

Same-Day Surgery Ileostomy Closure?

Manuel R. Moran, MD

Abstract

Loop ileostomy is a common procedure for temporary fecal diversion. Length of stay for ileostomy closure in many series is 3 to 6 days. There is, however, increasing pressure on surgeons to discharge patients as soon as possible. With attention to surgical details and careful perioperative management, it is possible to perform ileostomy closure as a same-day-discharge operation. This technique was used to treat six patients who needed ileostomy closure. All patients were discharged the day after or the day of the surgical intervention. There was no morbidity. Loop ileostomy and same-day ileostomy closure are cost-effective procedures for temporary fecal diversion.

(*Am J Man Care* 1997;3:1003-1006)

For editorial comment, see page 1091.

In a healthcare industry in which the political environment is cost containment, surgeons are familiar with pressure placed on them to discharge patients as soon as possible. It is not possible, however, to send surgical patients home until they can tolerate an oral diet and until pain control is acceptable.

Many surgeons prefer diverting ileostomy over diverting colostomy because it has fewer complications¹ and is easy to construct and close. A diverting ileostomy is easier for patients to manage than is a diverting transverse colostomy, so quality of life is bet-

ter than with a colostomy. It is almost always possible to close a loop ileostomy with a circumstomal technique.^{2,3} Although postoperative length of stay in most series is 3 to 6 days²⁻⁶ (Table 1), I believe this operation can be performed on many patients as a same-day-discharge procedure.

... METHODS ...

Six consecutive patients with ileostomies underwent a standardized surgical technique and perioperative care. Indications for ileostomy are recorded in Table 2. All patients were men 67 ± 11.7 years of age (mean \pm SD; range, 49 to 82 years). Ileostomies were constructed as a loop ileostomy, never as a divided ileostomy. The ileostomy was everted and matured with multiple interrupted 3-0 polyglactin 910 (Vicryl) sutures after an incision was made across the ileum on top of the loop. No aponeurotic sutures were placed, because this maneuver makes ileostomy take-down difficult. No support rods were used. No ileostomy-related complications occurred.

Ileostomy closure was performed no sooner than 6 weeks from the initial operation. Before the closure operation, patients received 2 g of intravenous cefotetan and 10 mg of intravenous metoclopramide. No oral antibiotics were used. Ileostomies were closed with a circumstomal technique (Figure). The edges of both limbs were resected with a GIA stapler. A few staples on the antimesenteric corner were removed, and a side-to-side stapled anastomosis was performed with a 60-mm GIA instrument. A suture was placed at the end of the anastomosis before the GIA instrument was fired to prevent any possible tension on the anastomosis. The resulting enterotomy was closed with two running sutures of 3-0 polyglactin 910 suture material or Lactomer 9-1 (Polysorb) while the anastomotic suture lines were held apart. The aponeurosis was closed with 0 polydioxanone suture (PDS). The wound, including

From the Veterans Administration Medical Center and Texas Tech University, Amarillo, TX

Address correspondence to: Manuel R. Moran, MD, 1550 Bell Street, #322, Amarillo, TX 79106-4494

aponeurosis and skin, was infiltrated with 0.25% bupivacaine without epinephrine. The skin was closed with interrupted sutures or staples. Non Adherent Dressing Wicks (Telfa wicks were placed in the wound and removed after 3 to 5 days.

In the recovery room patients were given 10 mg of intravenous metoclopramide and 30 mg of intravenous ketorolac tromethamine (Toradol). Patients who stayed overnight were given 15 or 30 mg (depending on age) of ketorolac tromethamine intravenously every

6 hours and 10 mg of metoclopramide intravenously every 6 hours. If the patient left the same day as the operation, 30 mg of intravenous ketorolac tromethamine was ordered on discharge. No scheduled parenteral narcotics were prescribed.

A clear liquid diet was started 1 hour after the operation, and a soft or regular diet was begun later that day or the next morning. Patients were sent home with a prescription for acetaminophen with codeine phosphate (Tylenol No. 3) or propoxyphene with acetaminophen (Darvocet N-100), 20 to 25 tablets with no refills. At discharge, patients were instructed to eat a soft or regular diet as tolerated but not to force themselves to eat if they were not hungry. Patients were told to keep the same dressing on until they came back to the clinic on postoperative day 3 to 5, and at that time the Telfa wicks were removed. Patients then were instructed to shower or bathe daily and to place a dry dressing on the incision until there was no drainage.

The choice of anesthetic agent was left to the anesthesiologist, and no attempt was made to standardize it. Five patients underwent the operation with general anesthesia and one with spinal anesthesia. All patients under general anesthesia were maintained with isoflurane; two were given propofol, and three were given thiopental sodium.

Table 1. Hospital Stay, Operative Time, and Patient Age in Several Ileostomy Closure Series

Author	Year	No. of Patients	Hospital Stay (d)*	Operative Time in Min	Age (y)
Feinberg, et al ³	1987	110	8 (3-33)	NA	32
Wexner, et al ⁴	1993	67	5 (3-49)	56	45
Hull, et al ⁵	1996				
Stapled		31	3 (2-5)	60	37.8
Handsewn		30	2.5 (1-19)	74	37.8
Bain, et al ⁶	1996 [†]				
Stapled		20	6 (4-18)	35	38
Handsewn		20	7 (4-26)	37	34
Hain, et al ²	1996	291	5.2 [‡]	NA	NA

*Values in parentheses are range

[†]Median results; all other authors gave mean results.

[‡]3.6 days for stapled anastomoses and 5.7 days for handsewn anastomoses

NA = not available.

Table 2. Indications for Diverting Loop Ileostomy

Coloanal anastomosis Extended low anterior resection Colonic pouch anal anastomosis Postoperative anastomotic leak after low anterior resection Difficulty low anterior resection (failed stapled anastomosis, re-anastomosed with sutures) Extended low anterior resection (patient with a local recurrence after low anterior resection and postoperative chemoradiation therapy for rectal cancer)
--

... RESULTS ...

Operating time was 74 ± 9 minutes (mean ± SD); most operations were performed by residents. Estimated blood loss was minimal for every patient (20 ± 16 ml, mean ± SD), as expected for this type of operation. The first three patients stayed overnight. The other three were discharged the day of the operation or early the next morning if the procedure was started in the afternoon. The minimum follow-up time for the first four patients was 4.5 months.

There was no morbidity such as wound infection or intestinal obstruction or mortality. At the time of writing, there have been no complications or readmissions related to the ileostomy or to the ileostomy closure. Follow up after ileostomy closure is 8 months ± 5.4 months (mean ± SD), varying from 2 months to 14 months. No readmissions or visits to the emergency room occurred. No patient required pain medication refills. None of the

patients requested a stronger pain medication after discharge from the hospital. All patients underwent close follow-up care in the clinic. No patient described himself as being discharged "too soon."

... DISCUSSION ...

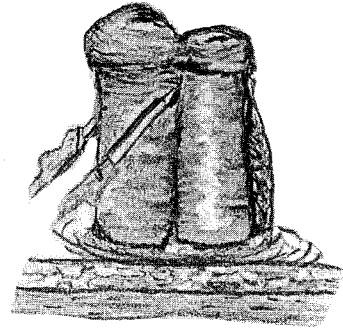
To the best of my knowledge, in no study has ileostomy closure been attempted as a same-day procedure. I believe the reason for the extended length of stay in most series is that patients are not allowed prompt resumption of oral intake. For example, Wexner et al.⁴ stated that their patients did not start a clear liquid diet until the third postoperative day. Delaying oral intake after intestinal operations is an old teaching that was the standard of care until a few years ago, and it is still being practiced by many surgeons. For some time it has been known that patients can start oral intake soon after an operation.⁷ The patients in this study started a liquid diet 1 hour after the operation. If a surgeon feels uncomfortable sending these patients home with a regular diet, the patient can be instructed to continue a liquid diet initially and to advance the diet as tolerated.

The average length of stay for ileostomy closure in a recent large series was 5.2 days.² The authors found that there was a greater length of stay with loop as opposed to divided ileostomy (6.5 versus 4.9 days) and with stapled as opposed to handsewn anastomosis (5.7 versus 3.6 days). In contrast, most of the patients at my center who undergo laparoscopic right hemicolectomy are discharged on postoperative day 3 or 4, and some as early as day 2. It makes no sense to have patients undergoing a lesser procedure stay for 4 or 5 days.


Pain control is easy after ileostomy closure because no muscular or fascial layers are divided. The operation is performed around the stoma, and the resulting aponeurotic defect can be closed without much tension. The patients in the study did not have severe or long-lasting pain, demonstrated by the fact that none requested a refill or a stronger analgesic.

If patients cannot go home after ileostomy closure, it is because they cannot tolerate oral intake. This "ileus" can be caused by swelling of the anastomosis or use of parenteral narcotics. The latter can be almost completely avoided by use of parenteral ketorolac tromethamine and a long-acting local anesthetic. A local anesthetic should be used because it is known from other outpatient operations, such as hemorrhoidectomy and hernia repair, that patients do not want to be discharged if they are experiencing considerable pain. Use of parenteral narcotics can be associated with nausea and vomiting. It is not possible to

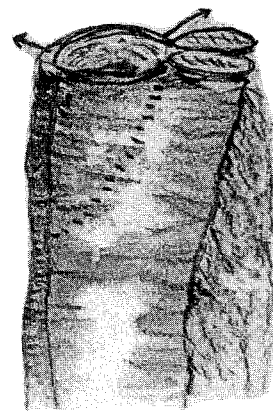
Figure 1. Technique of Ileostomy Closure



1a) The ileostomy is dissected using a circumstomal incision. Then, each limb of small bowel is divided near the ileostomy with a GIA 60 mm stapler.



1b) Several staples on the antimesenteric side are removed in each limb and using a GIA 60 mm stapler a side-to-side anastomosis is performed between both loops of small bowel.



1c) Both staple lines are pulled apart (as shown by the arrows) and the resulting enterotomy will be closed with two running sutures of 3-0 polyglactin 910 (Vicryl) or Lactomer 9-1 (Polysorb).

discharge a patient who is vomiting; that is why my colleagues and I prefer to use ketorolac tromethamine, a nonsteroidal anti-inflammatory drug.

Swelling of the anastomosis can be addressed with a stapled anastomosis. Although some studies compared stapled with handsewn anastomoses,^{5,6} in none was the procedure attempted as a same-day operation. The shortest length of stay (2.5 to 3 days) was reported in a paper that had several problems.⁵ First, the length of stay was not described in the body of the article, only in the abstract. Second, some of the numbers in the abstract did not match the numbers in the paper. A GIA stapler makes a larger lumen than a handsewn end-to-end anastomosis. In addition, when the anastomotic suture lines are held apart and the anastomotic staple lines are kept in an open V configuration, the area of the anastomosis can be as much as one-third larger than the original bowel lumen.⁸ The initial ileostomy should be a loop rather than divided because a loop is easier to close.

A GIA stapler costs this institution \$107, and the cost for each reload is \$66. Each surgery required one GIA stapler and two reloads, for a total of \$229 per patient.

All patients in the study left the hospital the day of the operation or the next day. In the past these patients stayed in the hospital for about 4 days. The estimated daily cost for hospitalization on the surgical floor at my institution is about \$1,038 per day. This means a \$3,000 savings per patient without any apparent increase in morbidity or patient dissatisfaction.

Ileostomy closure as a same-day surgical procedure is feasible if specific technical details are followed. Of course, this approach has to be tailored to each patient. I certainly am not advocating that every patient has to

be discharged the day of the operation. Some patients have ileus or other complications and need to be admitted to the hospital, increasing the average length of stay. For this reason, median (50th percentile) results might be more accurate because they eliminate this bias. Larger studies that report median length of stay are needed to confirm my results. Loop ileostomy closed several weeks later in a same-day-discharge operation should be cost-effective surgical treatment of many patients.

... REFERENCES ...

1. Williams NS, Nasmyth DG, Jones D, et al. De-functioning stomas: A prospective controlled trial comparing loop ileostomy with loop transverse colostomy. *Br J Surg* 1986;73:566-570.
2. Hain JM, Perez-Ramirez JJ, Madoff RD, et al. Loop ileostomy: A safe technique for temporary fecal diversion. Presented at the 95th Convention of The American Society of Colon and Rectal Surgeons; Seattle, WA, June 13, 1996.
3. Feinberg SM, McLeod RS, Cohen Z. Complications of loop ileostomy. *Am J Surg* 1987;153:102-107.
4. Wexner SD, Taranow DA, Johansen OB, et al. Loop ileostomy is a safe option for fecal diversion. *Dis Colon Rectum* 1993;36:349-354.
5. Hull TL, Kobe I, Fazio VW. Comparison of handsewn with stapled loop ileostomy closures. *Dis Colon Rectum* 1996;39:1086-1089.
6. Bain IM, Patel R, Keighley MR. Comparison of sutured and stapled closure of loop ileostomy after restorative proctocolectomy. *Ann R Coll Surg Engl* 1996;78:555-556.
7. Binderow SR, Cohen SM, Wexner SD, Noguera JJ. Must early postoperative oral intake be limited to laparoscopy? *Dis Colon Rectum* 1994;37:584-589.
8. Welter R, Charlier A, Psalmon F. In: Steichen FM, Ravitch MM, eds. *Stapling in Surgery*. Chicago: Year Book Medical Publishers, 1988:271-274.