

# The Patient's Photograph in the Medical Record as a Diagnostic Tool

Avivit Golan-Cohen, MD; Oded Horn, MD; Philip H. Sive, MD;  
and Shlomo Vinker, MD

Two case reports are presented: one of acromegaly and the other of hyperthyroidism. Previous photographs of the patients that appeared in their military medical record were of considerable assistance in making the correct diagnoses. When "smart cards" are issued in the future, inclusion of a photograph as an integral part of the patient's medical information should be considered.

*(Am J Manag Care. 2008;14(12):848-850)*

The advantages of a computerized medical record have been discussed extensively in the literature. The ability to store, organize, and retrieve information enables appropriate management of the health state of the individual. A computerized medical record also makes it possible to relate the characteristics of the individual to aspects of health and disease in the community.

Medical information, as defined in the vast majority of studies, relates to computerized fields containing coded material, information appearing as free text, or numerical data reflecting clinical or laboratory measurement. In specific fields that allow storage of visual information, it is usual to include photographic documentation in the medical record. Such is the case in the areas of dermatology, esthetic medicine,<sup>1</sup> imaging, and recently also dentistry.<sup>2</sup>

Particularly in the field of primary care, in which examination of patients always begins with observation of their general appearance, it is not usual to document this appearance with a photograph in the computerized medical record.

For reasons unrelated to medicine, the medical record of the Israel Defense Force (unlike civilian medical records) includes a passport-type photograph of the patient as a built-in part of his or her file. In the course of our routine work, we have found ourselves being helped frequently by that photograph and learn more from it than from what can be salvaged from a detailed, focused history.

In the following case reports we show the value of the patient's photograph as a specific diagnostic tool.

## CASE REPORTS

### Case 1

AC, a woman aged 26 years, an unmarried officer, complained of hirsutism of a year's duration. Inspection of the photograph in her medical file revealed that her facial features on examination were now coarser, her nose widened, and her lips thicker (Figure 1).

From her history focused on acromegaly, it was found that she had gained weight, and complained of a feeling of enlargement of her fingers and toes and occasional headaches. There were no other specific symptoms. Examination showed enlargement of the nose

For author information and disclosures,  
see end of text.

**In this issue**  
Take-away Points / p850  
[www.ajmc.com](http://www.ajmc.com)  
Full text and PDF

## Photograph in the Medical Record

and lips, broadening of fingers and toes, and hirsutism of the face and abdomen. Her serum prolactin level was 660 ng/mL (normal is <25 ng/mL).

Magnetic resonance imaging of the brain showed a large pituitary adenoma that pushed the stalk to the left. The remainder of the endocrine function was normal.

Treatment was initiated with octreotide and cabergoline to reduce the size of the tumor, which was too large for operation. After a number of months of treatment, the tumor shrank in size and was operated on with success.

In the opinion of the surgeons, the size of the tumor and its proximity to other brain structures had considerably endangered the patient. They doubted whether she could have recovered if the diagnosis had been made any later.

### Case 2

AM, a woman aged 40 years, a married officer, complained of typical symptoms of an upper respiratory tract infection.

On inspection of the photograph in the file, it was clear she had considerable weight loss. Consequently, her history revealed that she had lost about 30 kg after having given birth, far beyond the weight gain because of the pregnancy, which had ended a year and a half before. She complained of brittle nails, overactivity, and palpitations, with no other directing symptoms.

Her background history revealed that she had had an early menopause at the age of 31 years for an unknown reason, and was treated with regular hormone replacement. She became pregnant with the assistance of an ovum donor, and the pregnancy and labor were normal. Physical examination revealed no findings apart from the reduced weight.

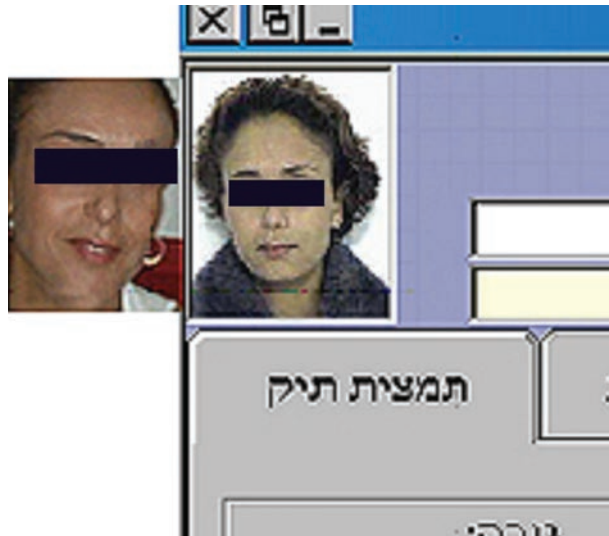
Laboratory tests showed increased levels of free thyroxine and total triiodothyronine, and a low level of thyrotropin. A thyroid scan showed a multinodular goiter.

She received appropriate treatment and 3 months after its initiation reported much improved well-being, a transition to a more convenient lifestyle, and a slight increase in weight. It subsequently transpired that her family life had undergone a radical change. During her thyrotoxic period, she suffered from overactivity that expressed itself in exaggerated work hours. However, with improved hormonal balance she reduced these hours, began to attend more to her son, and enabled her husband, who had been forced to fulfill her role at home, to seek work himself. The improvement in their marital relationship was an outcome of her rehabilitation.

## DISCUSSION

In DeGowin and DeGowin's textbook, observation of the patient is described as the most revealing factor with respect to

■ **Figure 1.** A Case of Acromegaly

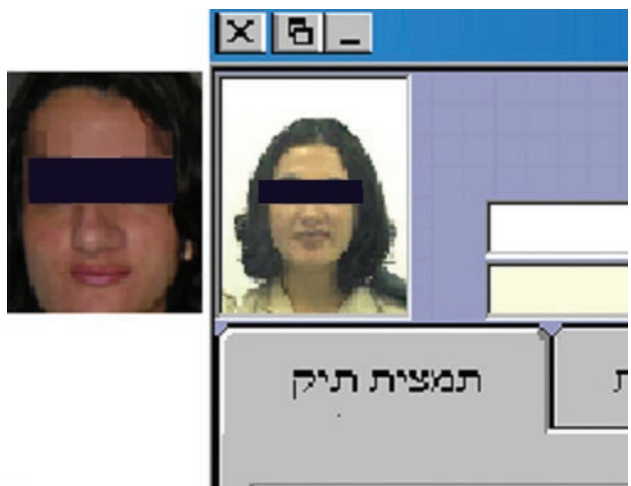

The picture on the right is the photograph as it appears in the medical records. The picture on the left is the photograph of the patient as she appears to the doctor's office.

physical signs.<sup>3</sup> Today, when the possibility of building intelligent information stores for every patient is being discussed, a readily available and instructive tool should be exploited—the patient's photograph, which may be incorporated into his or her medical record.

In the future, when "smart cards" containing all relevant medical information are issued for every patient,<sup>4,5</sup> inclusion of a photograph as an integral part of this information should

■ **Figure 2.** A Case of Hyperthyroidism



The picture on the right is the photograph as it appears in the medical records. The picture on the left is the photograph of the patient as she appears to the doctor's office.

### Take-away Points

The inclusion of a head and neck photograph in a personal medical record containing all relevant medical information may be of considerable diagnostic value in the treatment of patients.

- In 2 cases involving members of the Israel Defense Forces, the patient's photograph aided physicians in making a diagnosis.
- When future "smart cards" are issued, inclusion of a photograph as an integral part of the patient's medical information should be considered.

ily Medicine, Israel Defense Forces (AG-C, OH, PHS, SV), Tel Aviv, Israel.

**Funding Source:** None reported.

**Author Disclosure:** The authors (AG-C, OH, PHS, SV) report no relationship or financial interest with any entity that would pose a conflict of interest with the subject matter of this article.

**Authorship Information:** Concept and design (AG-C, OH, SV); acquisition of data (AG-C, OH); analysis and interpretation of data (AG-C, PHS, SV); drafting of the manuscript (AG-C, OH, PHS, SV); critical revision of the manuscript for important intellectual content (AG-C, PHS); provision of study materials or patients (AG-C, OH); administrative, technical, or logistic support (AG-C, PHS); and supervision (SV).

**Address correspondence to:** Dr. Avivit Golan-Cohen, MD, Israel Defense Forces, 14/1 Modiin St, Kiryat-Ono, 55022, Israel. E-mail: ccaa@netvision.net.il.

be considered. The photograph also may serve as a way to correctly identify a patient.<sup>6</sup> Rules will need to be determined for updating information, including timely updates of the photograph appearing in the medical record (eg, as is done for a passport or membership card for consumer organizations). When the photo is updated, it is logical that the original would be kept on the card as an historical record.

## CONCLUSIONS

The patient's medical history is the basis of the medical encounter. Observation is an important part of the physical examination of patients. With the additional dimension of information regarding the patient's past appearance provided by a photograph in the patient's record or smart card, the diagnosis is more easily achieved and may, as in the case presented, even be life saving.

**Author Affiliations:** From the Department of Family Medicine, Tel Aviv University (AG-C, OH, SV), Tel Aviv, Israel; and the Department of Fam-

## REFERENCES

1. Thomas JR, Tardy ME Jr, Przekop H. Uniform photographic documentation in facial plastic surgery. *Otolaryngol Clin North Am.* 1980;13(2):367-381.
2. Bengel W. Standardization in dental photography. *Int Dent J.* 1985;35(3):210-217.
3. DeGowin EL. *DeGowin & DeGowin's Bedside Diagnostic Examination.* 5th ed. New York: Macmillan; 1987:36-37.
4. Kardas G, Tunali ET. Design and implementation of a smart card based healthcare information system. *Comput Methods Programs Biomed.* 2006;81(1):66-78.
5. Bales S. The introduction of the electronic health card in Germany [in German]. *Bundesgesundheitsblatt Gesundheitsforschung Gesundheitsschutz.* 2005;48(7):727-731.
6. Mercer L, Widmer J, Prada J, Grogan K, Tresnan L. The registration function as a critical dependency in a lifetime clinical record (LCR). *Medinfo.* 1995;(8 pt 1):461. ■