

A Review of the First Anti-Evaporative Prescription Treatment for Dry Eye Disease: Perfluorohexyloctane Ophthalmic Solution

HIGHLIGHTS

- › The Pathophysiologic Role of Excessive Evaporation in Dry Eye Disease (DED)
- › Preclinical Trials Introducing Perfluorohexyloctane's Anti-Evaporative Mechanism of Action
- › Evidence from Clinical Trials Demonstrating the Safety and Effectiveness of Perfluorohexyloctane Ophthalmic Solution in Patients With DED

A Review of the First Anti-Evaporative Prescription Treatment for Dry Eye Disease: Perfluorohexyloctane Ophthalmic Solution

Financial support for this article was provided by **Bausch + Lomb**.

The contents of this supplement may include information regarding the use of products that may be inconsistent with or outside the approved labeling for these products in the United States. Physicians should note that the use of these products outside current approved labeling is considered experimental and are advised to consult prescribing information for these products.

Opinions expressed by authors, contributors, and advertisers are their own and not necessarily those of Clinical Care Targeted Communications Group, LLC; the editorial staff; or any member of the editorial advisory board. Clinical Care Targeted Communications Group, LLC, is not responsible for accuracy of dosages given in articles printed herein. The appearance of advertisements in this publication is not a warranty, endorsement, or approval of the products or services advertised or of their effectiveness, quality, or safety. Clinical Care Targeted Communications Group, LLC, disclaims responsibility for any injury to persons or property resulting from any ideas or products referred to in the articles or advertisements.

A Review of the First Anti-Evaporative Prescription Treatment for Dry Eye Disease: Perfluorohexyloctane Ophthalmic Solution

OVERVIEW

This supplement to *The American Journal of Managed Care*[®] provides managed care audiences with an introduction to the pathophysiologic role of excessive evaporation in dry eye disease (DED) and describes the current therapeutic management of DED. In addition, it highlights the clinical program supporting the efficacy and safety of perfluorohexyloctane ophthalmic solution (MIEBO[™]; Bausch + Lomb), a prescription eye drop that directly targets tear evaporation and is indicated for the treatment of the signs and symptoms of DED.

TABLE OF CONTENTS

Participating Faculty **S250**

Report

A Review of the First Anti-Evaporative Prescription Treatment for Dry Eye Disease: Perfluorohexyloctane Ophthalmic Solution **S251**

John D. Sheppard, MD, MMSc, FACS; David G. Evans, OD; and Eugene E. Protzko, MD

CLINICAL COMMUNICATIONS

Vice President

Angelia Szwed, MS

Director, Scientific Services

Patty Taddei-Allen, PharmD, MBA

Director, Publications

Danielle Mroz, MA

Scientific Director

Daniel Winslow, PharmD

Associate Scientific Directors

Erin Potter, PharmD
Nicholas Nowotarski, MD

Senior Clinical Content Manager

Ida Delmendo

Medical Writers

Dorothy Cooperson
Vieweg
Erin Garrow, PhD
Amanda Meyer, MS

Medical & Scientific Quality Review Editor

Jabir Bhuiyan, MS

Associate Editors

Amanda Thomas
Matthew Wynn

Assistant Editor

Thom LaPorte, MA

COPY & PRODUCTION

Vice President, Copy

Jennifer Potash

Copy Chief

Paul Silverman

Copy Supervisors

Angie DeRosa
Nicole Canfora Lupo

Senior Copy Editors

Cheney Baltz
Marie-Louise Best
Kelly King

Copy Editor

Kim Nir

Creative Director, Publishing

Melissa Feinen

Art Director

Julianne Costello

SALES & MARKETING

Vice President

Gil Hernandez

Associate Director, Business Development

Ben Baruch

Senior National Account Managers

Robert Foti
Kevin George

National Account Manager

Shaye Zyskowski

National Account Associates

Michael Bachalis
Alessandra Santorelli

OPERATIONS & FINANCE

Circulation Director

Jon Severn
circulation@mjhassoc.com

Vice President, Finance

Leah Babitz, CPA

Controller

Katherine Wyckoff

CORPORATE

President & CEO

Mike Hennessy Jr

Chief Financial Officer

Neil Glasser, CPA/CFE

Chief Marketing Officer

Brett Melillo

Chief Data Officer

Terric Townsend

Executive Vice President, Global Medical Affairs & Corporate Development

Joe Petroziello

Senior Vice President, Content

Silas Inman

Senior Vice President, Human Resources & Administration

Shari Lundenberg

Senior Vice President, Mergers & Acquisitions, Strategic Innovation

Phil Talamo

Executive Creative Director

Jeff Brown

FOUNDER

Mike Hennessy Sr
1960-2021

Copyright © 2023 by Clinical Care Targeted Communications Group, LLC

FACULTY

John D. Sheppard, MD, MMSc, FACS

Professor of Ophthalmology, Microbiology, & Molecular Biology

Clinical Director

Thomas R. Lee Center for Ocular Pharmacology
Eastern Virginia Medical School

Division Medical Director

EyeCare Partners

Medical Director

Lions Eye Bank of Eastern Virginia
Norfolk, VA

David G. Evans, OD

President

Total Eye Care, PA
Memphis, TN

Eugene E. Protzko, MD

Comprehensive Ophthalmologist

& Cataract Surgeon

Seidenberg Protzko Eye Associates

An affiliate of Prism Vision Group

Havre de Grace, MD

FACULTY DISCLOSURES

These faculty have disclosed the following relevant commercial financial relationships or affiliations in the past 12 months.

John D. Sheppard, MD, MMSc, FACS

CONSULTANCIES OR PAID ADVISORY BOARDS

AbbVie, Alcon, Aldeyra, Bausch + Lomb, Novaliq, Oyster Point, and Viatrix

LECTURE FEES FOR SPEAKING AT THE INVITATION OF A COMMERCIAL SPONSOR

AbbVie, Alcon, Aldeyra, Bausch + Lomb,

Novaliq, Oyster Point, and Viatrix

David G. Evans, OD

CONSULTANCIES OR PAID ADVISORY BOARDS

Visus

Eugene E. Protzko, MD reports no relationship

or financial interest with any entity that would pose a conflict of interest with the subject matter of this supplement.



AN **MH** life sciences® BRAND

Signed disclosures are on file at the office of *The American Journal of Managed Care*®, Cranbury, New Jersey.

A Review of the First Anti-Evaporative Prescription Treatment for Dry Eye Disease: Perfluorohexyloctane Ophthalmic Solution

John D. Sheppard, MD, MMSc, FACS; David G. Evans, OD; Eugene E. Protzko, MD

Introduction

Dry eye disease (DED) is one of the most common ocular surface conditions reported in the United States, with over 18 million US adults estimated to have a diagnosis of DED in 2023.¹⁻⁴ An imbalance between aqueous tear production and evaporation commonly drives the development and continuation of DED.^{1,5} DED is characterized by signs of ocular surface damage due to tear film instability and excessive evaporation associated with deficient lipid or aqueous tear film components and by symptoms of ocular pain and discomfort.^{1,5} Up to 90% of DED is associated with meibomian gland dysfunction (MGD), in which meibomian gland blockage and dropout contributes to a dysfunctional tear film lipid layer and consequent excessive evaporation.⁶⁻⁹

Most prescription eye drops for DED address signs and symptoms of disease by increasing tear production or decreasing inflammation, but they do not target the excessive evaporation that occurs in the majority of patients.^{1,10-15} Perfluorohexyloctane (PFHO) ophthalmic solution (MIEBO™; Bausch + Lomb) is the first and only FDA-approved treatment for DED that directly targets tear evaporation by supplementing the tear film lipid layer in patients whose tear evaporation exceeds tear production.^{16,17} PFHO is a water-free, preservative-free, single-ingredient prescription eye drop approved to treat the signs and symptoms of DED.¹⁸ Approval of PFHO was based on the results of 2 pivotal phase 3, multicenter, randomized clinical trials (RCTs), GOBI (NCT04139798) and MOJAVE (NCT04567329).¹⁸⁻²⁰ This article reviews preclinical data on the mechanism of action for PFHO and clinical data on its efficacy and safety in patients with DED.

Excessive Tear Evaporation and DED

The tear film is comprised of an inner, nutrient-rich mucoaqueous gradient layer that forms the bulk of the tear film and a thin outer lipid layer (**Figure 1**).^{21,22} Aqueous basal tear production largely occurs in the lacrimal glands, whereas most tear film mucins are synthesized by conjunctival goblet cells.^{1,21}

The meibomian glands, located within the tarsal plate of the upper and lower eyelids, produce the meibum that comprises the lipid layer.²¹ In a healthy tear film, the lipid layer resists tear evaporation

ABSTRACT

Dry eye disease (DED) is one of the most common ocular surface disorders. All DED involves an imbalance between tear production and evaporation. Most cases of DED are driven by excessive evaporation, which is often associated with meibomian gland dysfunction (MGD). In evaporative DED, a deficient tear film lipid layer is believed to lead to increased tear evaporation, inflammation, and ocular surface damage. Most prescription treatments for DED address signs and symptoms by targeting tear production and/or inflammation, but they do not address excessive evaporation. Perfluorohexyloctane (PFHO) ophthalmic solution (MIEBO™; Bausch + Lomb) is a water-free, single-ingredient, preservative-free prescription eye drop that directly targets tear evaporation and is approved by the FDA to treat the signs and symptoms of DED. Results from preclinical studies indicate that PFHO has a high oxygen carrying capacity, may reduce friction on blinking, and spreads quickly over the tear film surface to form a monolayer that inhibits evaporation. These effects can lead to stabilization of the tear film to promote ocular surface healing. Further, PFHO was detected in tears for at least 6 hours in a rabbit pharmacokinetic study, and results indicate that it may improve lipid layer thickness and quality. In 2 pivotal phase 3 trials in patients with DED and clinical signs of MGD (GOBI [NCT04139798] and MOJAVE [NCT04567329]), treatment with PFHO consistently met primary efficacy end points related to DED signs and symptoms (total corneal fluorescein staining and eye dryness, respectively) and was well tolerated. Compared with use of hypotonic saline solution, instillation of PFHO led to significant improvements in signs and symptoms in as early as 2 weeks. In a long-term, open-label safety extension study, efficacy of PFHO was sustained over 12 months, and the safety profile was consistent with those of previous studies. Clinical trial results indicate that treatment with PFHO effectively and consistently reduces the signs and symptoms of DED.

Am J Manag Care. 2023;29:S251-S259

For author information and disclosures, see end of text.

and provides protection against foreign matter, stability to prevent thinning and rapid breakup of tears, and a smooth surface for light refraction into the visual system.^{21,23} The lipid layer also contributes to lowering the healthy tear film's surface tension, resulting in its easy spreading across the eye and limiting irritation from blinking friction.^{21,23}

A deficiency in any layer of the tear film can cause a loss of tear film homeostasis. Most commonly, the outermost layer of the tear film is dysfunctional, resulting in increased tear evaporation.^{7,24} Increased tear evaporation, in turn, can lead to a cycle of hyperosmolarity, ocular surface desiccation and friction, inflammation and epithelial damage, and loss of goblet cells and meibomian glands, further driving aqueous tear evaporation and tear film instability.^{1,24,25} This damaging cycle can lead to the development and continuation of DED.²⁴

The imbalance between aqueous tear production and evaporation drives all forms of DED, including aqueous-deficient DED (driven by insufficient aqueous tear production), evaporative DED (associated with increased evaporation due to low levels or poor spreading of meibum), or some combination of these pathologies.^{1,7} However, most DED involves some level of excessive evaporation.^{1,7}

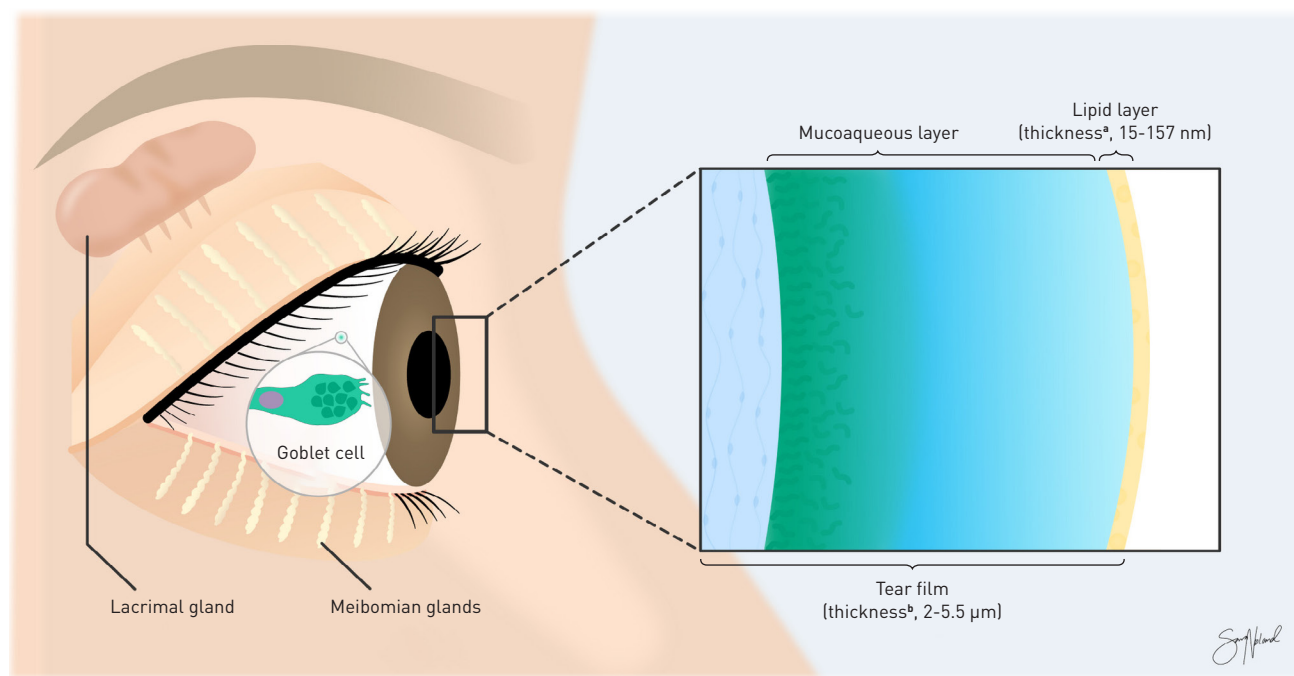
A contributing factor to development of evaporative DED is meibomian gland dysfunction (MGD), in which dysfunction and dropout of the meibomian glands and changes in the composition and viscosity of meibum compromise the tear film lipid layer.^{7,24} Up to an estimated 86% of patients with DED show signs of MGD, highlighting the pathophysiologic importance of a dysfunctional tear film lipid layer.⁶⁻⁸

Current Treatment Approaches

Appropriate treatment of DED should be guided by disease etiology and should address the underlying mechanisms of disease (eg, excessive evaporation, aqueous deficiency) to restore tear film stability and ocular surface homeostasis.^{1,26} Diagnosis involves investigation of clinical signs of DED, including low tear production, tear film instability, and ocular surface damage, which may be assessed via Schirmer testing, tear film breakup time, and ocular surface staining, respectively.^{9,10} Sustained care and management is frequently required to address the lingering effects of this chronic disease.¹

Recommended first-line treatments include tear replacement approaches, such as topical OTC ocular lubricants, as well as treatments aimed to decrease evaporation, including lipid-containing

FIGURE 1. The Healthy Ocular Tear Film^{21,22}



^aThe average thickness of the tear film lipid layer is approximately 40 nm.²¹

^bThe thickness of the tear film varies across different regions of the ocular surface.²¹

Adapted from Fjaervoll K, Fjaervoll H, Magno M, et al. Review on the possible pathophysiological mechanisms underlying visual display terminal-associated dry eye disease. *Acta Ophthalmol.* 2022;100(8):861-877. doi:10.1111/aos.15150. <https://onlinelibrary.wiley.com/doi/10.1111/aos.15150> under CC BY 4.0.

eye drops and therapies that encourage improved meibum flow and unblocking of affected glands (eg, eyelid hygiene, warm compresses).^{1,11,27} Patients for whom current first-line therapies prove to be inadequate may benefit from more advanced treatments, such as prescription medications or office-based procedures.^{1,10} Those with aqueous deficiency may benefit from placement of temporary or permanent punctal plugs to block tear drainage and improve tear supply.¹¹ To restore meibomian gland function and improve meibum flow in those with evaporative DED, procedural options include manual expression of meibomian glands, intraductal probing with a microcannula, and thermal pulsation or intense pulsed light therapies.^{10,11,27}

Prescription treatments approved for DED include those indicated to increase tear production or improve signs (eg, ocular surface damage) and/or symptoms (eg, eye dryness) of the disease.^{10,12-15,18,28,29} These treatments include a tear-film stabilizing ophthalmic insert, a cholinergic agonist nasal spray, eye drops with agents that have immunomodulatory or anti-inflammatory action (eg, calcineurin inhibitors, LFA-1 antagonists, corticosteroids), and, most recently, an eye drop that decreases tear-film evaporation.^{1,10,18,28,29}

The preservative-free hydroxypropyl cellulose ophthalmic insert (Lacrisert[®]; Bausch + Lomb) stabilizes and thickens the tear film to prevent rapid breakup of tears and lubricates and protects the ocular surface to relieve symptoms of DED.²⁸ Some patients may require twice-daily insertion for sufficient symptom relief, and satisfactory improvement may not occur for several weeks. Mostly mild and transient instances of vision blurring or photophobia, hypersensitivity, eyelid edema, and discomfort of the eyes or eyelashes have been reported with its use; in addition, corneal abrasion or foreign body sensation may occur if the insert is improperly placed.²⁸ Another prescription treatment for DED is varenicline nasal spray (Tyrvaya; Viatris), which contains a nicotinic acetylcholine receptor agonist that increases basal tear production by activating the trigeminal parasympathetic pathway.²⁹ In clinical trials, patients commonly experienced sneezing, cough, and throat or nose irritation upon instillation; adverse events (AEs) led to treatment discontinuation in approximately 3% or fewer of patients.²⁹⁻³¹ A precise and multi-step process of priming the bottle and delivering the varenicline spray is required²⁹; therefore, appropriate dosing may be a challenge for some patients.

Prescription Eye Drops and Unmet Needs

Most prescription eye drops indicated for treatment of DED reduce inflammation or stimulate tear production to address signs and symptoms of disease, although the exact mechanism of action in DED is rarely known.^{10-15,32}

Cyclosporine is a calcineurin inhibitor immunosuppressant; it is available as a 0.05% emulsion (Restasis; Allergan), a 0.09% nanomicellar solution (Cequa; Sun Ophthalmics), and a 0.1%

water-free solution (Vevye; Novaliq). It acts as a partial immunomodulator to increase tear production in patients whose tear production is presumed to be suppressed consequent to ocular inflammation.^{10,12,14,32} However, patients treated with the emulsion may not experience full clinical benefit for several months.^{11,33} Furthermore, patients with DED who are already being treated with topical anti-inflammatory drugs or punctal plugs may not experience increased tear production with use of cyclosporine ophthalmic emulsion, 0.05%.¹² Lifitegrast ophthalmic solution, 5.0% (Xiidra; Novartis), is an LFA-1 antagonist indicated for the treatment of signs and symptoms of DED; the results of in vitro studies suggest that it can inhibit certain inflammatory processes in corneal and conjunctival tissues.^{10,13}

Cyclosporine- and lifitegrast-containing eye drops are formulated without preservatives; they may be packaged in single-use vials, which are associated with increased costs.^{10,12-14,32}

Long-term treatment with cyclosporin- and lifitegrast-containing eye drops is often required to address DED; however, real-world use of these medications may be associated with low adherence and high rates of discontinuation.^{1,33} The most common AEs seen in clinical trials with cyclosporine were instillation-site pain, ocular burning, and conjunctival hyperemia.^{12,14,32} AEs associated with lifitegrast treatment in clinical trials included instillation site irritation, dysgeusia, and reduced visual acuity.¹³

Loteprednol etabonate ophthalmic suspension, 0.25% (Eysuvis; Kala Pharmaceuticals), contains a corticosteroid that inhibits inflammation to address signs and symptoms of DED.¹⁵ Treatment carries a lower risk of intraocular pressure (IOP) elevation than does treatment with other ocular steroids; however, this agent is intended for short-term use (maximum, 2 weeks) and carries the potential for steroid-associated AEs (eg, increased IOP; infection, cataracts, and delayed ocular surface healing).^{10,15,34} Instillation site pain was the most common AE in clinical trials with loteprednol etabonate, 0.25%.¹⁵ Loteprednol etabonate ophthalmic suspension is formulated with benzalkonium chloride, a preservative that can be associated with ocular surface toxicity.^{11,25}

These agents target different pathophysiologic pathways to disrupt the cycle of DED, yet until now topical prescription eye drops did not directly target the excessive evaporation present in most DED.^{1,10-15} PFHO—the first and only single-ingredient, preservative-free prescription eye drop approved for DED in the United States—was developed to target excessive evaporation.¹⁸

PFHO Mechanism of Action— Preclinical Study Results

Results from preclinical studies evaluating PFHO suggest that it can supplement the tear film lipid layer in patients with DED by rapidly spreading on instillation to form an anti-evaporative layer that remains on the eye for at least 6 hours and does not block the

diffusion of oxygen to the corneal surface. These results indicate PFHO's potential to stabilize the tear film, reduce friction, and promote ocular surface healing.^{16,17,35-40}

PFHO is a physiologically inert, semifluorinated alkane consisting of 6 perfluorinated and 8 hydrogenated carbons; it therefore has amphiphilic properties, allowing it to form a monolayer at the tear film air-liquid interface when applied topically (Figure 2^{35,41}).¹⁶⁻¹⁸ PFHO is a liquid at temperatures above -7.1°C , and it does not scatter or absorb visible light; with a refractive index similar to water, PFHO is associated with minimal blurred vision.^{16,19,35,42}

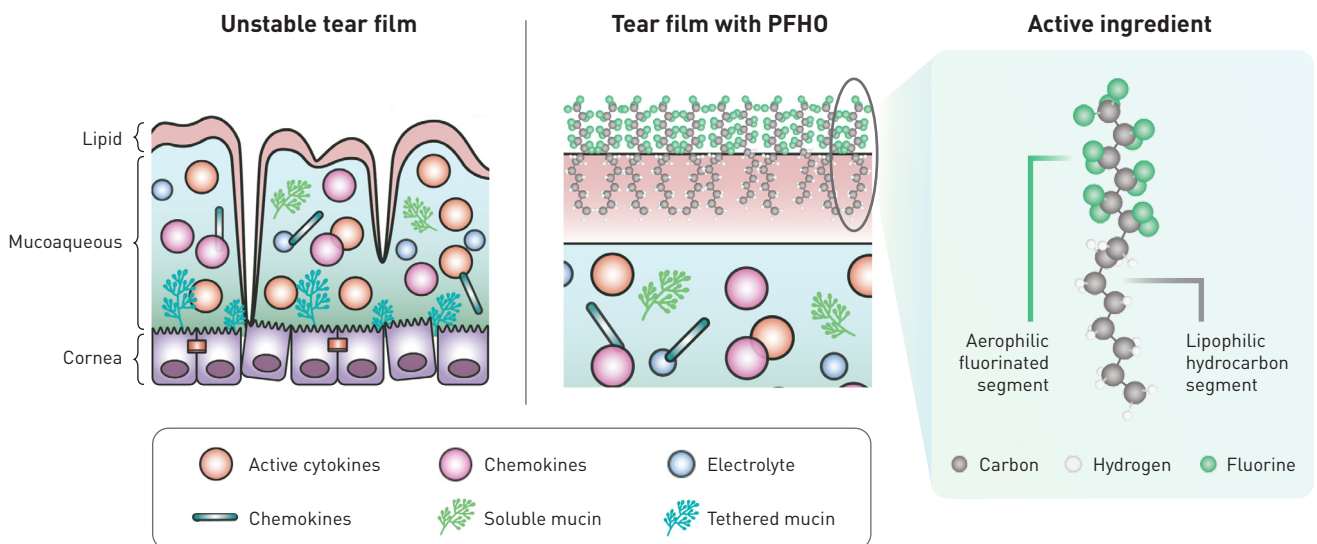
The anti-evaporative effect of PFHO was demonstrated in a series of in vitro gravimetric assays.¹⁶ Results of a preclinical study comparing the evaporation rate (R_{evap}) of saline alone to that of saline following layered application with common OTC artificial tear formulations (100 μL) or with PFHO showed that OTC eye drops did not significantly change the R_{evap} of saline, but layering different amounts of PFHO (range, 50-200 μL) on top of saline inhibited the R_{evap} by approximately 80% (all $P < .0001$). Additionally, when meibum collected from a healthy volunteer was layered on top of saline, the R_{evap} was inhibited by only 8%. However, layering an 11- μL or 100- μL drop of PFHO on top of saline and meibum inhibited the R_{evap} of saline by 34% and 83%, respectively (both $P < .0001$ vs saline alone). These results suggest that treatment with topical PFHO could address the excessive evaporation seen in most patients with DED.¹⁶

Results from another preclinical study support the potential of PFHO to spread quickly on the ocular surface and improve the tear film lipid layer.¹⁷ Compared with a drop of saline, a drop of PFHO exhibited faster spreading on the surface of ex vivo porcine eyes due to its lower surface tension. To examine PFHO's potential to stabilize the tear film lipid layer in vivo, the study also examined the effects of PFHO vs saline instillation into healthy rabbit eyes. When instilled twice daily (bid) over 7 days, lipid layer grade—which is associated with the quality and thickness of the tear film lipid layer—improved significantly with PFHO treatment compared with saline treatment from day 5 onwards ($P < .05$).¹⁷ PFHO may help spread ocular surface lipids to reduce friction on blinking, stabilize the tear film lipid layer, and improve the lipid layer grade to increase evaporation resistance.^{17,39}

Results from a third preclinical study showed that PFHO has a long-lasting presence in tears.³⁵ In a study with rabbits given a single topical ocular dose of PFHO (target dose, 45.6 mg/eye), the concentration of PFHO in tears was maintained for at least 6 hours. Exposure and distribution was highest in the tears and meibomian glands, with much lower exposure in conjunctival and corneal tissues; systemic absorption was minimal.³⁵ In addition, PFHO was present at 24 hours in the meibomian glands, indicating that the glands may function as a depot of the drug.^{10,35}

Finally, in another in vitro study, the oxygen concentration in PFHO was evaluated and determined to be high. The cornea is avascular;

FIGURE 2. PFHO Forms a Monolayer at the Tear Film Air-Liquid Interface^{35,41}



PFHO, perfluorohexyloctane.

Reproduced with permission from Bausch + Lomb.

thus, tears are a crucial source of the oxygen necessary for corneal health and epithelial healing after injury. The high oxygen solubility of PFHO indicates that it will allow oxygen transport from air to tears for corneal oxygenation to facilitate ocular surface healing.³⁶

Together, these preclinical study results suggest the potential of PFHO for DED treatment.^{16,17,35,36} The safety and efficacy of PFHO treatment also was examined across several clinical trials in patients with DED and clinical signs of MGD.

Clinical Evidence Supporting Use of PFHO

The efficacy and safety of PFHO for the treatment of DED was assessed in 2 pivotal phase 3 clinical trials, GOBI and MOJAVE (Table^{18-20,43,44}). Results indicated that treatment with PFHO was well tolerated and associated with statistically significant improvement vs control for both primary and key secondary sign and symptom end points, confirming efficacy and safety results from a previous phase 2 trial (SEECASE; NCT0333057).^{19,20,43} Furthermore, in an open-label safety extension trial (KALAHARI; NCT04140227) including a subset of patients from the GOBI study, treatment with PFHO remained safe and effective over the course of 52 weeks.⁴⁴

The SEECASE, GOBI, and MOJAVE trials compared topical treatment of PFHO to treatment with saline as a control in patients with DED and clinical signs of MGD.^{19,20,43} Typically, a vehicle control is used in DED clinical trials, but this was not viable, as the ophthalmic drop is composed of 100% PFHO.¹⁹ Therefore, SEECASE used isotonic (0.9%) saline as a control, whereas GOBI and MOJAVE used hypotonic (0.6%) saline as the control.^{19,20,43} Saline is a common ingredient in artificial tears, and the use of hypotonic saline solution as a control comparator in the trials provided additional rigor, as this solution can reduce tear film hyperosmolarity to effectively treat DED.¹⁹

To assess the ocular surface damage associated with DED, the trials measured corneal fluorescein staining (CFS) using the National Eye Institute scale. Investigators rated staining with scores ranging from 0 (no staining) to 3 (heavy staining) in each of 5 areas of the cornea (ie, inferior, superior, central, nasal, and temporal); the maximum total CFS (tCFS) score was 15. Symptom assessment was completed using the visual analog scale (VAS), with scores ranging from 0 (no discomfort) to 100 (maximal discomfort).¹⁹

SEECASE

The phase 2, multicenter, double-masked SEECASE study evaluated the efficacy, safety, and tolerability of bid or 4 times daily (qid) PFHO instillation compared with isotonic saline instillation for signs and symptoms of DED (Table^{18-20,43,44}). The study population was mostly female and had a mean age of 53 years.⁴³ Change from baseline (CFB) in mean tCFS and mean VAS eye dryness scores at 8 weeks were significantly greater for both PFHO dosing arms than for the isotonic saline (0.9%) arm, with greater improvements seen in the qid dosing arm; further, both signs and symptoms showed significant

improvements with as little as 2 weeks of treatment. Treatment with PFHO was well tolerated at both dosing regimens, with low rates of ocular AEs (eg, blurred vision, eye irritation, eye pain).⁴³

GOBI Pivotal Trial

GOBI was a phase 3, multicenter, double-masked RCT conducted to evaluate the efficacy and safety of treatment with PFHO compared with a hypotonic (0.6%) saline control for the treatment of signs and symptoms of disease in 597 patients with DED and clinical signs of MGD after 2, 4, and 8 weeks of treatment (Table^{18-20,43,44}). The study population was mostly female, with approximately half of patients aged 65 years or older.¹⁹ Both primary end points in GOBI were met, with significantly greater improvement from baseline in tCFS and VAS dryness score seen in patients who were treated with PFHO compared with those given hypotonic saline treatment at 8 weeks (Figure 3^{19,20}). Mean improvement from baseline with PFHO treatment was significantly greater across all key secondary end points, including CFB in VAS dryness and tCFS scores at week 2 and CFB in VAS burning or stinging score and central CFS (cCFS) score at week 8.¹⁹ In addition, compared with results in the hypotonic saline arm, the CFB in mean VAS dryness score in the PFHO arm was significant at week 2 and week 8, although the treatment difference at week 4 did not reach statistical significance (Figure 4^{19,20}).

Significantly more patients in the PFHO arm (41.2%) were tCFS responders (defined as showing ≥ 3 -step tCFS score improvement) compared with those in the hypotonic saline arm (27.2%). Similarly, 57.4% of patients in the PFHO arm were eye dryness responders (defined as showing $\geq 30\%$ reduction in VAS dryness score), whereas 46.6% of those in the hypotonic saline arm were considered eye dryness responders.¹⁹

In general, PFHO treatment was found to be safe and well tolerated. Among reported ocular AEs in both arms, none were serious, and most were mild in severity. Ocular AEs were considered to be related to treatment in 6.3% of patients in the PFHO arm and 3.1% of patients in the hypotonic saline arm. One patient discontinued PFHO treatment due to an ocular AE (eye irritation; severe), and 3 patients discontinued hypotonic saline treatment (conjunctivitis, dry eye, punctate keratitis); no serious ocular AEs were reported in either arm. The most common ocular AEs, reported in 1% or more of patients treated with PFHO, were blurred vision (3.0%; mostly mild and transient) and instillation site pain and eye discharge (both 1.0%).¹⁹

Results from the GOBI trial support the safety and tolerability of PFHO and its efficacy in treating the signs and symptoms of DED as early as 2 weeks and through 8 weeks of treatment.¹⁹

MOJAVE Pivotal Trial

Efficacy and safety of PFHO treatment was further assessed in the similarly designed phase 3 MOJAVE RCT, in which 620 patients

TABLE. Key Clinical Trial Information of PFHO Treatment in DED^{18-20,43,44,a}

Study (NCT number)	SEECASE (NCT03333057)	GOBI (NCT04139798)	MOJAVE (NCT04567329)	KALAHARI (NCT04140227)
Study design	Phase 2, multicenter, randomized, double-masked, isotonic saline-controlled US trial evaluating the efficacy and safety of PFHO for DED associated with MGD	Phase 3, multicenter, randomized, double-masked, hypotonic saline-controlled US trials evaluating the efficacy and safety of PFHO for DED associated with MGD		Phase 3, multicenter, single-arm, open-label extension of GOBI evaluating long-term safety and tolerability
Patient population	Adult patients with DED in both eyes; MGD in 1 or both eyes	Adult patients with self-reported history of DED in both eyes; MGD in 1 or both eyes		
Treatment	Patients were randomly assigned 2:2:1:1 to PFHO qid (n=114), PFHO bid (n=111), or saline 0.9% qid/bid (combined; control, n=111), respectively, in both eyes for 8 weeks.	Patients were randomly assigned 1:1 to PFHO qid (n=303) or saline 0.6% qid (control; n=294) in both eyes for 8 weeks.	Patients were randomly assigned 1:1 to PFHO qid (n=311) or saline 0.6% qid (control; n=309) in both eyes for 8 weeks.	At crossover (week 8 of GOBI/day 1 of KALAHARI), patients who were randomly assigned to PFHO qid (n=97) or saline 0.6% qid (n=111) in GOBI began treatment with PFHO qid in both eyes for 52 weeks.
Primary end points and results	Mean CFB in tCFS at week 8 vs control <ul style="list-style-type: none"> • PFHO qid: -1.18 (<i>P</i> < .001) • PFHO bid: -0.85 (<i>P</i> = .009) 	LS mean treatment difference vs control at week 8 <ul style="list-style-type: none"> • tCFS: -0.97 (<i>P</i> < .001) • VAS dryness score: -7.6 (<i>P</i> < .001) 	LS mean treatment difference vs control at week 8 <ul style="list-style-type: none"> • tCFS: -1.2 (<i>P</i> < .001) • VAS dryness score: -10.2 (<i>P</i> < .001) 	Patients reporting ≥ 1 ocular AE <ul style="list-style-type: none"> • 13.9%^b Patients reporting ≥ 1 nonocular AE <ul style="list-style-type: none"> • 24.5%
	Mean CFB in VAS dryness score at week 8 vs control <ul style="list-style-type: none"> • PFHO qid: -11.84 (<i>P</i> < .001) • PFHO bid: -10.70 (<i>P</i> = .002) 	LS mean treatment difference vs control <p>At week 2</p> <ul style="list-style-type: none"> • tCFS: -0.6 (<i>P</i> = .001) • VAS dryness score: -4.7 (<i>P</i> = .009) <p>At week 8</p> <ul style="list-style-type: none"> • VAS burning or stinging score: -5.5 (<i>P</i> = .006) • cCFS: -0.2 (<i>P</i> < .001) tCFS responders ^d <ul style="list-style-type: none"> • PFHO: 41.2% • Control: 27.2% OR, 1.88 [95% CI, 1.3-2.7]; <i>P</i> < .001	LS mean treatment difference vs control <p>At week 2</p> <ul style="list-style-type: none"> • tCFS: -0.6 (<i>P</i> = .001) • VAS dryness score: -7.8 (<i>P</i> < .001) <p>At week 8</p> <ul style="list-style-type: none"> • VAS burning or stinging score: -7.3 (<i>P</i> < .001) • cCFS: -0.3 (<i>P</i> < .001) tCFS responders ^d <ul style="list-style-type: none"> • PFHO: 50.0% • Control: 30.7% OR, 2.35 [95% CI, 1.7-3.3]; <i>P</i> < .001	Patients with ocular AEs related to study medication ^c <ul style="list-style-type: none"> • 6.3% Patients with ocular AEs leading to study discontinuation <ul style="list-style-type: none"> • 2.4% Mean CFB at week 52 <ul style="list-style-type: none"> • tCFS score: -2.1 • VAS dryness score: -33.7
Secondary key end points and results				
Key safety outcomes	Patients reporting ≥ 1 ocular AE <ul style="list-style-type: none"> • PFHO qid: 11.4% • PFHO bid: 4.5% • Control: 11.7% 	Patients reporting ≥ 1 ocular AE <ul style="list-style-type: none"> • PFHO: 9.6%^f • Control: 7.5% 	Patients reporting ≥ 1 ocular AE <ul style="list-style-type: none"> • PFHO: 12.9%^g • Control: 12.3% 	

AE, adverse effect; bid, twice daily; cCFS, central corneal fluorescein staining score; CFB, change from baseline; DED, dry eye disease; LS, least squares; MGD, meibomian gland dysfunction; PFHO, perfluorohexyloctane; OR, odds ratio; qid, 4 times daily; tCFS, total corneal fluorescein staining score; VAS, visual analog scale.

^aSign assessment: tCFS score using the National Eye Institute scale to assess staining with range 0 (no staining) to 3 (heavy staining) for each of 5 areas of the cornea, with a maximum total score of 15. Symptom assessment: VAS eye dryness scale with a range of 0 (no discomfort) to 100 (maximal discomfort).

^bOcular AEs reported in ≥ 1% of patients included allergic conjunctivitis, blurred vision, dry eye, increased lacrimation, instillation site pain, and vitreous detachment.

^cSuspected or considered by the investigator to be related to study medication

^dtCFS responder: ≥ 3-step improvement in tCFS score at week 8

^eEye dryness responder: ≥ 30% reduction in VAS dryness score at week 8

^fOcular AEs reported in ≥ 1% of patients in the PFHO arm included vision blurring, instillation site pain, and eye discharge.

^gOcular AEs reported in ≥ 1% of patients in the PFHO arm included blepharitis, conjunctival or ocular hyperemia, conjunctival papillae, blurred vision, visual acuity reduction, and hordeolum.

with DED and clinical signs of MGD were randomly assigned to either PFHO or 0.6% hypotonic saline treatment instilled qid for 8 weeks (Table^{18-20,43,44}). The study population was mostly female, with approximately a third of patients aged 65 years or older.²⁰ Consistent with results from the GOBI trial, significantly greater improvements from baseline in both tCFS and VAS dryness scores were seen with PFHO treatment versus use of hypotonic saline beginning at week 2 and continuing through week 8 (Figures 3 and 4).^{19,20} Significant improvement in other secondary efficacy outcomes (eg, central CFS, VAS burning/stinging scores) was seen as early as week 2. Additionally, 50.0% of patients in the PFHO arm were tCFS responders and 65.6% were eye dryness responders at week 8 compared with 30.7% and 45.3%, respectively, among those in the hypotonic saline arm.²⁰

Both treatment arms had similarly low rates of ocular AEs, which were mostly mild in severity, confirming the findings from SEECASE and GOBI and indicating that PFHO treatment was well tolerated.^{19,20,43} One patient in the hypotonic saline arm experienced a severe ocular AE of eye irritation, but no patients in either arm discontinued treatment due to AEs.²⁰ Ocular AEs deemed related to treatment were seen in 6.4% of patients in the PFHO arm and

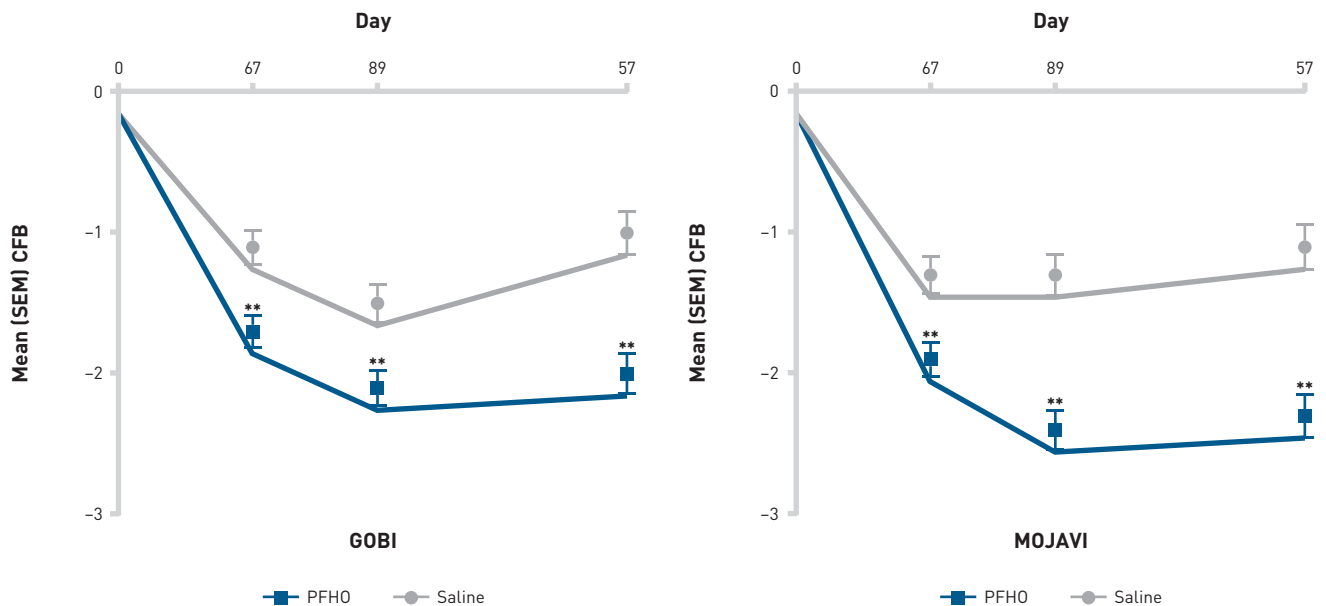
6.8% of patients in the hypotonic saline arm. The most common ocular AEs (incidence, ≥1%) reported in patients treated with PFHO included blepharitis (1.6%); conjunctival or ocular hyperemia, conjunctival papillae, and blurred vision (1.3% each); and visual acuity reduction and hordeolum (1.0% each).²⁰ Consistent with results from the GOBI study, PFHO achieved statistical superiority compared with hypotonic saline for all key end points, demonstrating improvements over hypotonic saline in treating both DED signs and symptoms across the length of the 8-week study.^{19,20} Furthermore, PFHO was similarly well tolerated and effective over 8 weeks of treatment, with a similar safety profile to the hypotonic saline control.²⁰

KALAHARI Extension Trial

The KALAHARI trial was an open-label extension of GOBI, in which a subset of patients from both the PFHO and hypotonic saline arms in GOBI were treated with PFHO qid for 52 weeks. Results from the KALAHARI trial supported the long-term efficacy and safety of PFHO treatment in patients with DED and clinical signs of MGD.⁴⁴

After 52 weeks of PFHO treatment, 13.9% of patients experienced an ocular AE, of which most were mild in severity. The most

FIGURE 3. Improvement in tCFS Over Time in GOBI and MOJAVE^{19,20}



CFB, change from baseline; PFHO, perfluorohxyloctane; SEM, standard error of the mean; tCFS, total corneal fluorescein staining.

**P ≤ .001

Adapted from *American Journal of Ophthalmology*, Vol 252, Sheppard JD, Kurata F, Epitropoulos AT, Krösser S, Vittitow JL; MOJAVE Study Group, NOV03 for signs and symptoms of dry eye disease associated with meibomian gland dysfunction: the randomized phase 3 MOJAVE study. Pages 265-274, Copyright [2023], with permission from Elsevier.

common ocular AEs were vitreous detachment (1.9% of patients, none considered treatment-related), allergic conjunctivitis (1.4%), blurred vision (1.4%), and increased lacrimation (1.4%); in 2.4% of patients, ocular AEs (eg, blurred vision, chalazion, dry eye, increased lacrimation, and increased IOP [each in 1 patient]) led to treatment discontinuation. Improvements in tCFS and VAS dryness score seen in GOBI among the active arm were maintained; in those who switched from the hypotonic saline control to PFHO at the start of the study, improvement in these measures was seen by week 4 and was maintained for the remainder of the study.⁴⁴

Conclusions

Results from multiple clinical trials showed the consistent efficacy and favorable safety profile of PFHO in treating the signs and symptoms of disease in patients with DED and clinical signs of MGD. PFHO recently received FDA approval for treatment of the signs and symptoms of DED, and it may address unmet needs in the prescription treatment of DED. Excessive evaporation is a major contributor to disease pathogenesis and the continuing cycle of DED progression. There are estimated to be over 18 million patients in the United States

with a DED diagnosis, most of whom experience excess tear evaporation. PFHO is the first and only FDA-approved prescription eye drop that directly targets excessive evaporation in patients with DED, thereby promoting ocular surface healing and symptomatic relief. ■

Authorship affiliation: Eastern Virginia Medical School (JDS); Total Eye Care, PA (DGE); Seidenberg Protzko Eye Associates (EEP)

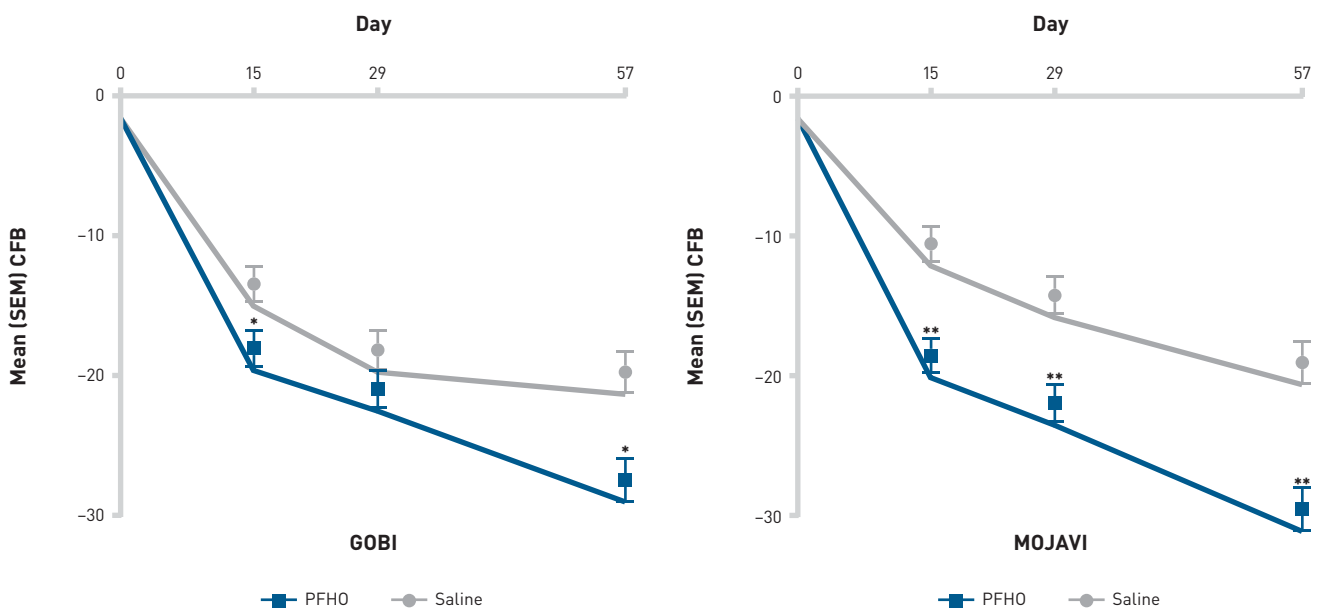
Funding source: Financial support for this article was provided by Bausch + Lomb.

Author disclosure: Dr Sheppard reports serving on a consultancy or paid advisor board for AbbVie, Alcon, Aldeyra, Bausch + Lomb, Novaliq, Oyster Point, and Viatriis. Dr Sheppard also reports receiving lecture fees for speaking at the invitation of a commercial sponsor from AbbVie, Alcon, Aldeyra, Bausch + Lomb, Novaliq, Oyster Point, and Viatriis. Dr Evans reports serving on a consultancy or paid advisor board for Visus. Dr Protzko reports no relationship or financial interest with any entity that would pose a conflict of interest with the subject matter of this supplement.

Authorship information: Concept and design (JDS); acquisition of data (EEP); analysis and interpretation of data (JDS, DGE, EEP); drafting of the manuscript (JDS, DGE); critical revision of the manuscript for important intellectual content (JDS, DGE); provision of study materials or patients (EEP); administrative, technical, or logistic support (JDS); supervision (JDS, EEP).

Address correspondence to: John D. Sheppard MD, MMSc, FACS, Virginia Eye Consultants, 241 Corporate Boulevard, Norfolk, VA 23502. mmarino@cvphealth.com

FIGURE 4. Improvement in VAS Dryness Score Over Time in GOBI and MOJAVE^{19,20}



CFB, change from baseline; PFHO, perfluorohexyloctane; SEM, standard error of the mean; VAS, visual analog scale.

* $P \leq .009$

** $P \leq .001$

Adapted from *American Journal of Ophthalmology*, Vol 252, Sheppard JD, Kurata F, Epitropoulos AT, Krösser S, Vittitow JL; MOJAVE Study Group, NOV03 for signs and symptoms of dry eye disease associated with meibomian gland dysfunction: the randomized phase 3 MOJAVE study. Pages 265-274, Copyright (2023), with permission from Elsevier.

REFERENCES

- Craig JP, Nelson JD, Azar DT, et al. TFOS DEWS II report executive summary. *Ocul Surf*. 2017;15(4):802-812. doi:10.1016/j.jtos.2017.08.003
- Bradley JL, Özer Stillman I, Pivneva I, Guerin A, Evans AM, Dana R. Dry eye disease ranking among common reasons for seeking eye care in a large US claims database. *Clin Ophthalmol*. 2019;13:225-232. doi:10.2147/OPTH.S188314
- Farrand KF, Fridman M, Stillman IO, Schaumberg DA. Prevalence of diagnosed dry eye disease in the United States among adults aged 18 years and older. *Am J Ophthalmol*. 2017;182:90-98. doi:10.1016/j.ajo.2017.06.033
- U.S. and world population clock. US Census Bureau. Accessed August 30, 2023. <https://www.census.gov/popclock/>
- McMonnies CW. Aqueous deficiency is a contributor to evaporation-related dry eye disease. *Eye Vis (Land)*. 2020;7:6. doi:10.1186/s40662-019-0172-z
- Stapleton F, Alves M, Bunya VY, et al. TFOS DEWS II epidemiology report. *Ocul Surf*. 2017;15(3):334-365. doi:10.1016/j.jtos.2017.05.003
- Lemp MA, Crews LA, Bron AJ, Foulks GN, Sullivan BD. Distribution of aqueous-deficient and evaporative dry eye in a clinic-based patient cohort: a retrospective study. *Cornea*. 2012;31(5):472-478. doi:10.1097/ICO.0b013e318225415a
- Rabensteiner DF, Aminfar H, Boldin I, Schwantzer G, Horwath-Winter J. The prevalence of meibomian gland dysfunction, tear film and ocular surface parameters in an Austrian dry eye clinic population. *Acta Ophthalmol*. 2018;96(6):e707-e711. doi:10.1111/aos.13732
- Geerling G, Baudouin C, Aragona P, et al. Emerging strategies for the diagnosis and treatment of meibomian gland dysfunction: proceedings of the OCEAN group meeting. *Ocul Surf*. 2017;15(2):179-192. doi:10.1016/j.jtos.2017.01.006
- Sheppard JD, Nichols KK. Dry eye disease associated with meibomian gland dysfunction: focus on tear film characteristics and the therapeutic landscape. *Ophthalmol Ther*. 2023;12(3):1397-1418. doi:10.1007/s40123-023-00669-1
- Jones L, Downie LE, Korb D, et al. TFOS DEWS II management and therapy report. *Ocul Surf*. 2017;15(3):575-628. doi:10.1016/j.jtos.2017.05.006
- Restasis. Prescribing information. Allergan; 2017. Accessed August 17, 2023. https://www.rxabbvie.com/pdf/restasis_pi.pdf
- Xiidra. Prescribing information. Novartis Pharmaceuticals; 2020. Accessed August 17, 2023. https://www.novartis.com/us-en/sites/novartis_us/files/xiidra.pdf
- Cequa. Prescribing information. Sun Pharmaceutical Industries Limited; 2022. Accessed August 17, 2023. <https://www.cequa.com/CequaPI.pdf>
- Eysuvis. Prescribing information. Kala Pharmaceuticals; 2020. Accessed August 17, 2023. <https://www.eysuvis-ecp.com/pdf/prescribing-information.pdf>
- Vittitow J, Kissing R, DeCory H, Borchman D. In vitro inhibition of evaporation with perfluorohexyloctane, an eye drop for dry eye disease. *Curr Ther Res Clin Exp*. 2023;98:100704. doi:10.1016/j.curtheres.2023.100704
- Agarwal P, Khun D, Krösser S, et al. Preclinical studies evaluating the effect of semifluorinated alkanes on ocular surface and tear fluid dynamics. *Ocul Surf*. 2019;17(2):241-249. doi:10.1016/j.jtos.2019.02.010
- Miebo. Prescribing information. Bausch + Lomb; 2023. Accessed August 17, 2023. <https://www.bausch.com/globalassets/pdf/packageinserts/pharma/miebo-package-insert.pdf>
- Tauber J, Berdy GJ, Wirta DL, Krösser S, Vittitow JL; GOBI Study Group. NOV03 for dry eye disease associated with meibomian gland dysfunction: results of the randomized phase 3 GOBI study. *Ophthalmology*. 2023;130(5):516-524. doi:10.1016/j.ophtha.2022.12.021
- Sheppard JD, Kurata F, Epitropoulos AT, Krösser S, Vittitow JL; MOJAVE Study Group. NOV03 for signs and symptoms of dry eye disease associated with meibomian gland dysfunction: the randomized phase 3 MOJAVE study. *Am J Ophthalmol*. 2023;252:265-274. doi:10.1016/j.ajo.2023.03.008
- Willcox MDP, Argüeso P, Georgiev GA, et al. TFOS DEWS II tear film report. *Ocul Surf*. 2017;15(3):366-403. doi:10.1016/j.jtos.2017.03.006
- Fjaervoll K, Fjaervoll H, Magno M, et al. Review on the possible pathophysiological mechanisms underlying visual display terminal-associated dry eye disease. *Acta Ophthalmol*. 2022;100(8):861-877. doi:10.1111/aos.15150
- Chhadva P, Goldhardt R, Galor A. Meibomian gland disease: the role of gland dysfunction in dry eye disease. *Ophthalmology*. 2017;124(11S):S20-S26. doi:10.1016/j.ophtha.2017.05.031
- Baudouin C, Messmer EM, Aragona P, et al. Revisiting the vicious circle of dry eye disease: a focus on the pathophysiology of meibomian gland dysfunction. *Br J Ophthalmol*. 2016;100(3):300-306. doi:10.1136/bjophthalmol-2015-307415
- Nebbioso M, Del Regno P, Gharbiya M, Sacchetti M, Plateroti R, Lambiase A. Analysis of the pathogenic factors and management of dry eye in ocular surface disorders. *Int J Mol Sci*. 2017;18(8):1764. doi:10.3390/ijms18081764
- Craig JP, Nichols KK, Akpek EK, et al. TFOS DEWS II definition and classification report. *Ocul Surf*. 2017;15(3):276-283. doi:10.1016/j.jtos.2017.05.008
- Arita R, Fukuoka S. Non-pharmaceutical treatment options for meibomian gland dysfunction. *Clin Exp Optom*. 2020;103(6):742-755. doi:10.1111/cxo.13035
- Lacrisert. Prescribing information. Bausch + Lomb; 2019. Accessed August 17, 2023. <https://www.lacrisert.com/siteassets/pdf/Lacrisert-package-insert.pdf>
- Tyrvaia. Prescribing information. Viatriis; 2021. Accessed August 17, 2023. <https://www.tyrvaia-pro.com/files/prescribing-information.pdf>
- Wirta D, Torkildsen GL, Boehmer B, et al. ONSET-1 phase 2b randomized trial to evaluate the safety and efficacy of OC-01 (varenicline solution) nasal spray on signs and symptoms of dry eye disease. *Cornea*. 2022;41(10):1207-1216. doi:10.1097/ICO.0000000000002941
- Wirta D, Vollmer P, Paaui J, et al. Efficacy and safety of OC-01 (varenicline solution) nasal spray on signs and symptoms of dry eye disease: the ONSET-2 phase 3 randomized trial. *Ophthalmology*. 2022;129(4):379-387. doi:10.1016/j.ophtha.2021.11.004
- Vevey. Prescribing information. Novaliq; 2023. Accessed August 24, 2023. https://www.accessdata.fda.gov/drugsatfda_docs/label/2023/217469s000lbl.pdf
- White DE, Zhao Y, Ogundele A, et al. Real-world treatment patterns of cyclosporine ophthalmic emulsion and lifitegrast ophthalmic solution among patients with dry eye. *Clin Ophthalmol*. 2019;13:2285-2292. doi:10.2147/OPTH.S226168
- Sheppard JD, Comstock TL, Cavet ME. Impact of the topical ophthalmic corticosteroid loteprednol etabonate on intraocular pressure. *Adv Ther*. 2016;33(4):532-552. doi:10.1007/s12325-016-0315-8
- Krösser S, Spencer E, Grillenberger R, et al. Ocular and systemic distribution of 14C-perfluorohexyloctane following topical ocular administration to rabbits. Poster presented at: Association for Research in Vision and Ophthalmology Annual Meeting; April 29-May 3, 2018; Honolulu, HI. Novaliq. Accessed August 17, 2023. https://www.novaliq.com/wp-content/uploads/2021/01/07_Krösser_ARVO2018_radiolabel-distribution-rabbits_EyeSol.pdf
- Stolowich N, Vittitow J, Kissing R, Borchman D. Oxygen-carrying capacity of perfluorohexyloctane, a novel eye drop for dry eye disease. *Curr Ther Res Clin Exp*. 2023;98:100705. doi:10.1016/j.curtheres.2023.100705
- Agarwal P, Khun D, Krösser S, et al. Evaluating the lubricating effect of semifluorinated alkanes on the ocular surface. *Invest Ophthalmol Vis Sci*. 2018;59(9):3282.
- Agarwal P, Khun D, Krösser S, et al. Evaluating the lubricating effect of semifluorinated alkanes on the ocular surface. Poster presented at: Association for Research in Vision and Ophthalmology Annual Meeting; April 29-May 3, 2018; Honolulu, HI. Novaliq. Accessed August 24, 2023. www.novaliq.com/wp-content/uploads/2021/01/08_Agarwal_ARVO2018_spreading-lipid-layer-effect_EyeSol.pdf
- Steven P, Scherer D, Krösser S, Beckert M, Cursiefen C, Kaercher T. Semifluorinated alkane eye drops for treatment of dry eye disease—a prospective, multicenter noninterventional study. *J Ocul Pharmacol Ther*. 2015;31(8):498-503. doi:10.1089/jop.2015.0048
- Schmidt D, Bata AM, Szegedi S, et al. Influence of perfluorohexyloctane eye drops on tear film thickness in patients with mild to moderate dry eye disease: a randomized controlled clinical trial. *J Ocul Pharmacol Ther*. 2020;36(3):154-161. doi:10.1089/jop.2019.0092
- Krafft MP, Riess JG. Chemistry, physical chemistry, and uses of molecular fluorocarbon—hydrocarbon diblocks, triblocks, and related compounds—unique “apolar” components for self-assembled colloid and interface engineering. *Chem Rev*. 2009;109(5):1714-1792. doi:10.1021/cr800260k
- Liang Y, Kociok N, Leszczuk M, et al. A cleaning solution for silicone intraocular lenses: “sticky silicone oil.” *Br J Ophthalmol*. 2008;92(11):1522-1527. doi:10.1136/bjo.2008.143750
- Tauber J, Wirta DL, Sall K, et al; SEECASE study group. A randomized clinical study (SEECASE) to assess efficacy, safety, and tolerability of NOV03 for treatment of dry eye disease. *Cornea*. 2021;40(9):1132-1140. doi:10.1097/ICO.0000000000002622
- Protzko E, Segal B, Korenfeld M, Krösser S, Vittitow J. Long-term safety and efficacy of perfluorohexyloctane ophthalmic solution for the treatment of patients with dry eye disease: the KALAHARI study. *Cornea*. In press.

SUPPLEMENT POLICY STATEMENT

Standards for Supplements to *The American Journal of Managed Care*®

All supplements to *The American Journal of Managed Care*® are designed to facilitate and enhance ongoing medical education in various therapeutic disciplines. All *Journal* supplements adhere to standards of fairness and objectivity, as outlined below. Supplements to *The American Journal of Managed Care*® will:

- I. Be reviewed by at least 1 independent expert from a recognized academic medical institution.
- II. Disclose the source of funding in at least 1 prominent place.
- III. Disclose any existence of financial interests of supplement contributors to the funding organization.
- IV. Use generic drug names only, except as needed to differentiate between therapies of similar class and indication.
- V. Be up-to-date, reflecting the current (as of date of publication) standard of care.
- VI. Be visually distinct from *The American Journal of Managed Care*®.
- VII. Publish information that is substantially different in form and content from that of the accompanying edition of *The American Journal of Managed Care*®.
- VIII. Prohibit excessive remuneration for contributors and reviewers.
- IX. Carry no advertising.

Publisher's Note: The opinions expressed in this supplement are those of the authors, presenters, and/or panelists and are not attributable to the sponsor or the publisher, editor, or editorial board of *The American Journal of Managed Care*®. Clinical judgment must guide each professional in weighing the benefits of treatment against the risk of toxicity. Dosages, indications, and methods of use for products referred to in this supplement are not necessarily the same as indicated in the package insert for the product and may reflect the clinical experience of the authors, presenters, and/or panelists or may be derived from the professional literature or other clinical sources. Consult complete prescribing information before administering.

