

Effective and Efficient Diagnosis of Parkinsonism: The Role of Dopamine Transporter SPECT Imaging With Ioflupane I-123 Injection (DaTscan™)

Jeffrey L. Cummings, MD, ScD; Michael J. Fine, MD; Igor D. Grachev, MD, PhD;
C. Rick Jarecke, PharmD; Meridith K. Johnson, MSc; Phillip H. Kuo, MD, PhD;
Joyce A. Oberdorf; Michael Rezak, MD, PhD; David E. Riley, MD;
Kenneth L. Schaecher, MD, FACP, CPC; and Daniel Truong, MD

Parkinson's disease (PD) is a common neurological illness associated with significant patient and payer burden. Its accurate diagnosis is challenging and misdiagnosis is common.¹⁻³ Additionally, overdiagnosis of PD has been observed when only clinical symptoms were used to assess uncertain cases.⁴ Although experts in movement disorders are able to achieve greater diagnostic accuracy than their primary care or general neurology counterparts, they are still uncertain about the diagnosis in many patients. Adding to this, access to experts may be limited, thus further reducing opportunities for diagnosis.⁵

Imaging technology has improved considerably in recent years. The 2011 approval by the US Food and Drug Administration (FDA) of the radiopharmaceutical ioflupane I-123 injection (hereafter referred to as DaTscan™) for striatal dopamine transporter (DaT) visualization using single-photon emission computed tomography (SPECT) offers a new biomarker that can assist in differentiating conditions associated with nigrostriatal degeneration (eg, PD, multiple system atrophy [MSA], progressive supranuclear palsy [PSP], and other parkinsonian syndromes) from those movement disorders without this degeneration (eg, essential tremor [ET]).⁶

This publication is based on a roundtable discussion involving a multidisciplinary panel of experts with experience in movement disorders, nuclear imaging, managed care, and patient advocacy, and provides clinical criteria and algorithms to help guide managed care organizations (MCOs) and practitioners in the appropriate use of DaTscan imaging.

Overview of Parkinson's Disease

PD is second only to Alzheimer's disease (AD) as a cause of neurodegenerative disease.⁷ More than 1 million Americans currently have PD and approximately 60,000 new cases are diagnosed each year.⁸ PD is characterized by a spectrum of motor and non-motor dysfunction.^{1,9} The motor-related disorders of PD include resting tremor, rigidity, postural instability, and bradykinesia.⁹ Common nonmotor symptoms in PD include sleep disorders, olfactory dysfunction, and neuropsychiatric and autonomic symp-

Abstract

Parkinson's disease (PD), the second-most common neurodegenerative disease, is characterized by motor and nonmotor symptoms. PD is often misdiagnosed; inappropriate treatment due to misdiagnosis has undesired consequences, as does delayed diagnosis. Unfortunately, most people with PD receive a diagnosis only after motor symptoms have emerged, by which time 40% to 60% of dopamine neurons have already been lost. Advances in imaging techniques have provided clinicians with increasingly sophisticated tools. In 2011, the US Food and Drug Administration approved ioflupane I-123 injection (DaTscan™) for striatal dopamine transporter visualization using single-photon emission computed tomography (SPECT) imaging, which provides an effective tool for assessing striatal dopaminergic deficiency. Among patients with suspected parkinsonian syndromes, of which PD is one, the diagnostic sensitivity and specificity of DaTscan SPECT imaging are high. In clinical studies that were part of the DaTscan new drug application, no serious drug-related adverse events reported by the 1236 participants were attributed to DaTscan. The introduction of DaTscan imaging and its utility necessitate the development of clinical recommendations for appropriate use; thus, a multidisciplinary panel of experts was convened to develop clinical criteria and algorithms to help guide clinicians and managed care organizations in the application of DaTscan SPECT imaging. Based on the consensus of this expert panel, appropriate use of DaTscan SPECT imaging includes cases where: (1) PD diagnosis is uncertain; (2) tremor of uncertain etiology is present; and (3) nonmotor and/or supportive symptoms and features associated with PD are present but the classical motor syndrome is absent or atypical.

Am J Manag Care. 2004;20:S97-S109

For author information and disclosures, see end of text.

■ Sidebar 1. UK Parkinson's Disease Society Brain Bank Clinical Diagnostic Criteria¹³

Step 1. Diagnosis of Parkinsonian Syndrome

- Bradykinesia (slowness of initiation of voluntary movement with progressive reduction in speed and amplitude of repetitive actions)
- And at least 1 of the following:
 - Muscular rigidity
 - 4-6 Hz rest tremor
 - Postural instability not caused by primary visual, vestibular, cerebellar, or proprioceptive dysfunction

Step 2. Exclusion Criteria for Parkinson's Disease

- History of repeated strokes with stepwise progression of parkinsonian features
- History of repeated head injury
- History of definite encephalitis
- Oculogyric crises
- Neuroleptic treatment at onset of symptoms
- More than 1 affected relative
- Sustained remission
- Strictly unilateral features after 3 years
- Supranuclear gaze palsy
- Cerebellar signs
- Early severe autonomic involvement
- Early severe dementia with disturbances of memory, language, and praxis
- Babinski sign
- Presence of cerebral tumor or communication hydrocephalus on CT scan
- Negative response to large doses of levodopa (if malabsorption excluded)
- MPTP exposure

Step 3. Supportive Prospective Positive Criteria for Parkinson's Disease

(3 or more required for diagnosis of definite Parkinson's disease)

- Unilateral onset
- Rest tremor present
- Progressive disorder
- Persistent asymmetry affecting side of onset most
- Excellent response (70%-100%) to levodopa
- Severe levodopa-induced chorea
- Levodopa response for 5 years or more
- Clinical course of 10 years or more

CT indicates computed tomography; MPTP, 1-methyl-4-phenyl-1,2,3,6-tetrahydropyridine.

Reprinted with permission from Hughes AJ, Daniel SE, Kilford L, Lees AJ. *J Neurol Neurosurg Psychiatry*. 1992;55(3):181-184.

toms.¹⁰ Key pathologic characteristics of PD include neuronal loss, particularly dopaminergic neuronal loss, appearing most prominently in the substantia nigra, as well as various protein deposits (cytoplasmic inclusions), Lewy bodies, and Lewy neurites.^{9,10}

Diagnosis and Differential Diagnosis of Parkinson's Disease

PD is diagnosed based on clinical information regarding symptoms and findings from a physical examination. Although tests may be used to rule out other conditions, there are no tests that specifically confirm a diagnosis of PD.¹¹

The most commonly used diagnostic criteria are the 1992 UK PD Society (UK PDS) Brain Bank criteria (see [Sidebar 1](#)).^{12,13} The UK PDS clinical diagnostic criteria include a 3-step algorithm. The first step involves evaluation

of symptoms that indicate possible PD. Step 2 involves consideration of factors that would rule out PD. Step 3 involves evaluation for the presence of additional supportive criteria to support a diagnosis of PD.¹³

Use of the "levodopa challenge test" for confirmation of a PD diagnosis remains an area of controversy. False-positive and false-negative responses to dopaminergic challenge may be as high as 40%.¹⁴ The previously mentioned UK PDS Brain Bank clinical diagnostic criteria count excellent (ie, 70% to 100%) response to levodopa as one of the diagnostic criteria for PD, and the American Academy of Neurology (AAN) practice parameter, published in 2006, recommends the levodopa (or apomorphine) challenge when a PD diagnosis is in doubt.^{12,13} However, these recommendations preceded the availability of DaT SPECT imaging. Newer guidelines, such as the 2013 European

■ **Table 1.** Conditions Frequently Misdiagnosed as Parkinson’s Disease^{9,16-21}

Common Misdiagnoses	Distinguishing Features
Essential tremor (ET)	<ul style="list-style-type: none"> • Tremor (action/postural) is singular or main feature • Family history more common • Alcohol responsiveness • No response to PD medications
Progressive supranuclear palsy (PSP) or Steele-Richardson-Olszewski disease	<ul style="list-style-type: none"> • Supranuclear gaze palsy • Early gait instability • Square-wave jerks • Upright posture • Pseudobulbar affect • Dysphagia
Multiple system atrophy (MSA)	<ul style="list-style-type: none"> • Autonomic disturbance • Cerebellar signs • Relative absence of tremor • Early gait instability • Dysphagia • Poor or atypical response to levodopa
Corticobasal ganglionic degeneration (CBGD)	<ul style="list-style-type: none"> • Limb apraxia • Cortical sensory abnormalities • Limb rigidity and dystonia • Focal reflex myoclonus • Nonfluent aphasia
Dementia with Lewy bodies (DLB)	<ul style="list-style-type: none"> • Early dementia • Visual hallucinations • Fluctuating cognition • REM sleep behavior disorder
Alzheimer’s disease	<ul style="list-style-type: none"> • Dementia is primary symptom
Drug-induced parkinsonism	<ul style="list-style-type: none"> • Exposure to dopamine-blocking drugs • Lack of rest tremor and asymmetry
Vascular parkinsonism	<ul style="list-style-type: none"> • History of chronic hypertension • Stepwise progression (if any) • Unilateral • Lower-body parkinsonism in multi-infarct states • Imaging

PD indicates Parkinson’s disease; REM, rapid eye movement.
Reprinted with permission from the National Parkinson Foundation.

Federation of Neurological Societies and the European Section of the Movement Disorder Society (EFNS/MDS-ES) diagnostic recommendations, do not support the use of drug challenges for the diagnosis of de novo parkinsonian patients because there is insufficient evidence to support their role in differentiating PD and other parkinsonian syndromes.¹⁴ Taken together, particularly in light of the recent evidence-based EFNS/MDS-ES recommendations, dopamine challenge should be regarded as a far from optimal means of supporting diagnosis and ought to be seen primarily as a therapeutic rather than a diagnostic tool in PD.

The motor and nonmotor symptoms experienced by patients are not exclusive to PD. Other neurodegenerative conditions, including MSA, PSP, dementia with Lewy bodies (DLB), and corticobasal ganglionic degeneration,

can also manifest with parkinsonism.⁹ ET, with which PD is often confused, is far more common than PD, affecting an estimated 5% of people in the United States 65 years or older.¹⁵ Conditions that are frequently mistaken for PD are listed in **Table 1**.^{9,16-21} Currently, most people with PD receive a diagnosis only after motor symptoms have appeared, by which time between 40% and 60% of dopamine neuronal markers have already been lost.^{10,22-24} The importance of nonmotor symptoms in early diagnosis has become better recognized in recent years. Barone et al surveyed 1072 patients with PD and found that 98.6% experienced at least 1 nonmotor symptom. Additionally, the researchers found that 3 domains of nonmotor symptoms—apathy, attention/memory, and psychiatric symptoms (eg, depression and anxiety)—were often not associated with disease duration or dopaminergic treatment, suggesting

■ **Table 2.** Misdiagnosis of Parkinsonian Syndrome and ET—Overview of Studies^{3,4,18,26-29}

Reference	Findings Regarding Misdiagnosis
Schrag A et al; 2002 ¹⁸	A prior diagnosis of PD was rejected in 15% of patients when reevaluated using standardized criteria after >1 year follow-up
Meara J et al; 1999 ³	47% of patients diagnosed as having PD in community practice did not meet the UK PDS Brain Bank criteria
Jain S et al; 2006 ²⁷	A prior diagnosis of ET was rejected in 37% of patients when reevaluated using standardized criteria
Marshall VL et al; 2009 ⁴	Clinical diagnosis specificity of 46% in patients in whom there was diagnostic uncertainty
Tolosa E et al; 2007 ²⁸	In 44% to 54% of patients with clinically uncertain parkinsonian syndromes, the diagnosis was changed after DaTscan imaging
Kupsch A et al; 2013 ²⁹	
Kupsch AR et al; 2012 ²⁶	

ET indicates essential tremor; PD, Parkinson's disease; UK PDS, United Kingdom Parkinson's Disease Society.

that these symptoms can start very early in the disease course and may function as early diagnostic markers.¹

Misdiagnosis of PD is extremely common, particularly in the primary care setting, where PD diagnoses may be incorrect nearly half of the time.³ The diagnosis of PD may be especially challenging for primary care physicians (PCPs), as it may be difficult for nonspecialist physicians to maintain a high level of knowledge about PD because a typical PCP may see a new case of PD relatively infrequently.²⁵ With regard to specialist diagnosis, a study of diagnostic accuracy of PD in patients with clinically uncertain parkinsonian syndromes found that movement disorder specialists fail to achieve an accurate diagnosis in about 47% of cases, while general neurologists misdiagnose as much as 75% of the time in this patient population.^{4,26} The earlier the patient is in the disease process, the more likely it is that the diagnosis will be mistaken.²⁵ **Table 2** provides an overview of studies on the misdiagnosis of parkinsonian syndromes and ET.^{3,4,18,26-29}

The consequences of delayed diagnosis or misdiagnosis are serious. Over time, delayed treatment can result in untreated symptoms that may result in prolonged disability. Also, patients with PD who have been misdiagnosed may receive inappropriate therapies with consequent risk of adverse events, while possibly undergoing additional and inappropriate testing.^{26,30,31}

Role of Imaging in Disease Detection of Nigrostriatal Degeneration

A number of imaging modalities and diagnostic agents have been studied for the assessment of patients with parkinsonism, including magnetic resonance imaging (MRI),

blood flow measures (Tc-99m hexamethylpropyleneamine oxime SPECT), ¹⁸F-fluorodopa positron emission tomography, ¹²³I-β-CIT SPECT, and DaTscan SPECT. Many of these imaging techniques/diagnostic agents are currently used in the research setting rather than in routine clinical practice. DaTscan (ioflupane I-123 injection) is approved by the FDA and the European Medicines Agency (under the brand name DaTSCAN) and is indicated for striatal DaT visualization using SPECT brain imaging to assist in the evaluation of adult patients with suspected parkinsonian syndromes. At present, MRI is a common imaging technique used in the diagnosis (or exclusion) of many conditions; however, MRI does not visualize nigrostriatal degeneration and is not specific for PD or parkinsonian syndromes.^{14,32}

DaTscan is a radiolabeled analogue of cocaine that binds to presynaptic dopamine receptors. It was administered in a total of 1236 subjects (1176 patients and 65 healthy volunteers) in 11 clinical studies that were part of the DaTscan new drug application. Adverse events were mild and infrequent, and no serious drug-related adverse reactions were attributed to DaTscan.³³ The injected substance is a radioactive material, and it is considered a scheduled, controlled substance in the United States.⁶ DaTscan images of normal and abnormal striatum activity are shown in **Figure 1**.⁶

DaTscan Clinical Effectiveness Studies

A phase 3 trial of DaTscan imaging involved 158 patients with a diagnosis of parkinsonism, 27 patients with ET, and 35 healthy volunteers at 6 centers where the images were read by the individual centers (“institutional on-site read”) and by an expert panel of 5 nuclear medicine physicians (“blinded read”), all assessors being blinded to patients’ clinical data.

■ **Figure 1.** Normal and Abnormal DaTscan Images⁶

Image 1

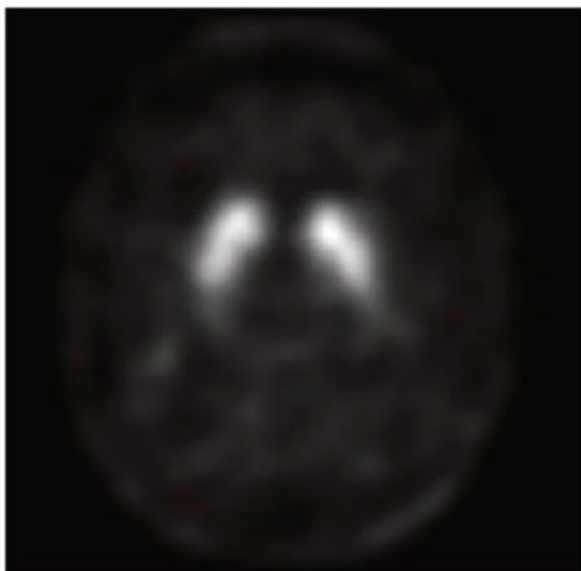


Image 2

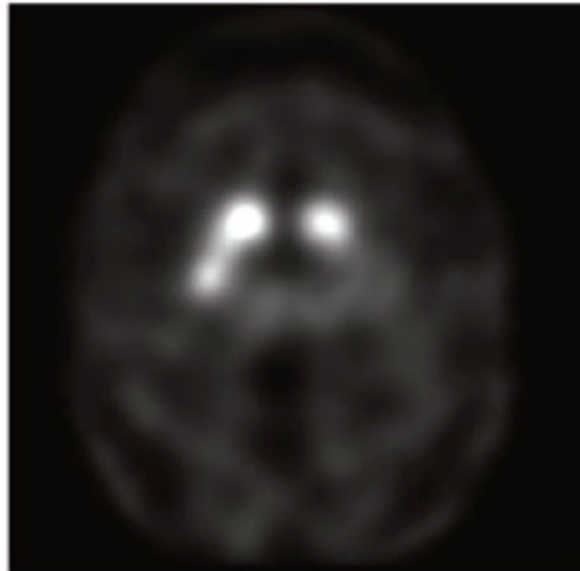


Image 3

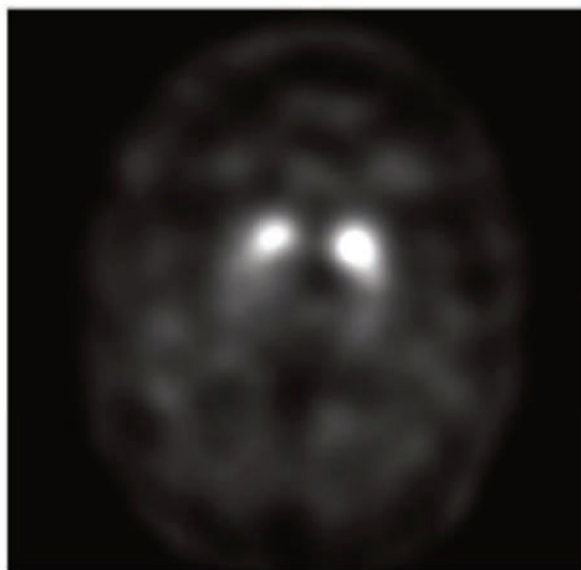
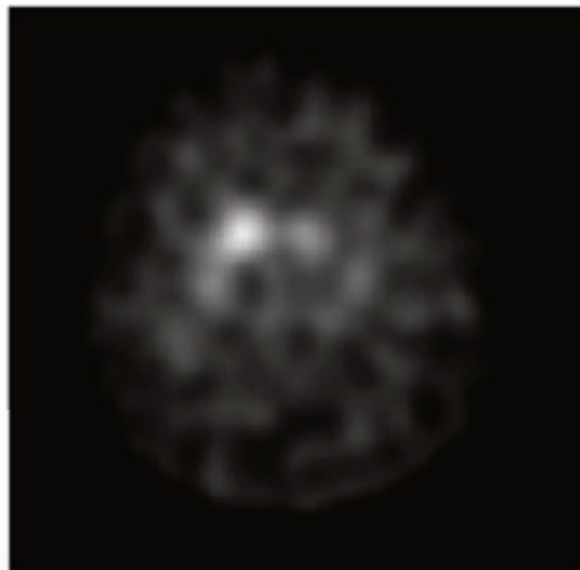


Image 4



From upper left, the first image shows 2 symmetric comma- or crescent-shaped focal regions of activity indicating normal activity; the next image shows asymmetric activity; the third image shows that activity is absent in the putamen of both hemispheres and confined to the caudate nuclei; the final image shows activity is absent in the putamen of both hemispheres and greatly reduced in 1 or both caudate nuclei.

Positive percent agreement (statistical equivalent to sensitivity) for a parkinsonism diagnosis was 97% and negative percent agreement (statistical equivalent of specificity) for ET was 100% for the institutional assessors, whereas sensitivity was 95% and specificity was 93% for the expert panel. In this study, patients had established clinical diagnoses, and for

that reason an expert panel for clinical diagnosis (reference standard) was not considered necessary.³⁴

The effectiveness of DaT imaging to achieve an accurate differential diagnosis was the subject of a study by Jennings et al in which the diagnostic accuracy of movement disorder specialists (MDSs) was compared with DaT imaging in patients

Report

with suspected PD. The authors found that while MDSs were able to identify people who had PD (92% sensitivity), they also misidentified a large proportion of people who did not have PD (30% specificity). By contrast, DaT imaging allowed for exactly the same degree of sensitivity but with a 100% specificity rate.³⁵ A similar study conducted in the European Union by Marshall et al observed diagnostic sensitivity of 93% and specificity of 46% among neurologists compared with a sensitivity of 78% and specificity of 97% using DaTscan imaging. This study used 3 blinded imaging experts and a clinical expert panel with a review of videotapes to establish the clinical diagnosis at 3 years follow-up (reference standard) after DaTscan imaging. It is important to point out that overdiagnosis of PD (as reflected by high sensitivity and low specificity of clinical diagnosis in the Jennings and Marshall studies when imaging information was not provided), and subsequent inappropriate treatment, is common in the clinical setting.⁴

DaTscan Clinical Utility Studies

Several studies in both the United States and Europe have demonstrated the impact of DaTscan on clinician diagnostic thinking and patient management. In a recent global randomized study (United States and Europe) involving 273 patients with clinically uncertain parkinsonian syndromes, patients were randomized to receive either DaTscan imaging (135 patients) or no imaging (138 patients; the control group) to evaluate the impact on clinical disease management. The follow-up period after DaTscan imaging was 12 months, with visits at weeks 4, 12, and 52. At 4 weeks, 45% of the DaTscan group experienced a change in diagnosis versus 9% of the control group ($P < .001$). At 12 weeks, 46% and 12% experienced diagnosis changes ($P < .001$). At 1 year, 54% of patients in the DaTscan group received a change in diagnosis compared with 23% in the control group ($P < .001$). In addition, a significantly greater mean change from baseline in confidence of diagnosis was observed in the DaTscan group versus the control group at all visits ($P < .001$). In the DaTscan group, a change in diagnosis at 1 year was significantly more common among general neurologists (75%) compared with MDSs (47%; $P = .022$). Compared with those in the control group, significantly more patients in the DaTscan group had at least 1 change in clinical management at 12 weeks (31% vs 50%; $P = .002$) and 1 year (22% vs 41%; $P < .001$). Examples of changes in clinical management included initiation or escalation of dopaminergic therapy in patients with abnormal scans and discontinuation of dopaminergic therapy in patients with normal scans.²⁶

The diagnostic accuracy of DaTscan was also assessed in a multicenter, open-label follow-up study in patients

from the Clinically Uncertain Parkinson Syndrome study ($n = 118$).³⁰ At the 2-year follow-up ($n = 85$), the rate of agreement between the follow-up diagnosis and the initial clinical diagnosis at baseline before DaTscan imaging was 56% (suggesting a change in clinical diagnosis in 44% of patients).²⁸

The impact of DaTscan on diagnosis and clinical management was also evaluated in an independent study of cases from clinical practice by Seifert et al (2013). As part of the study, physicians ordering DaTscan imaging for their patients were contacted retrospectively and asked to complete a brief survey with questions regarding diagnosis, confidence in diagnosis, and clinical management of the patient before and after DaTscan imaging. A total of 112 patients were included in the study. After DaTscan imaging, there was a change in diagnosis in 31% of patients (35 of 112). Physicians felt that the scan influenced their diagnosis in 68% of patients (76 of 112), and physicians were more confident in the diagnosis. Clinical management was affected in 58% of patients (65 of 112). This study had certain methodological limitations (ie, it was a retrospective survey), which may explain some differences from the 2 previous prospective studies.³⁶

Guidelines for Diagnostic Use of DaTscan SPECT Imaging

The clinical value of DaTscan in patient diagnosis and management has been recognized in guidelines developed by clinicians and payer organizations. The 2013 EFNS/MDS-ES guidelines, the most recent of the major guidelines for PD imaging, state that “DaTscan SPECT is indicated in the presence of significant diagnostic uncertainty and particularly in patients presenting atypical tremor manifestations,” and grade the level of evidence as “A” (see [Sidebar 2](#)).^{12,14,25,37,38} The guidelines further note that “All other SPECT imaging studies do not fulfill registration standards and [other agents] cannot be recommended for routine clinical use.”¹⁴

The US-based Society of Nuclear Medicine and Molecular Imaging (SNMMI), which has developed technical guidelines specific to DaTscan SPECT, has identified situations for which DaTscan imaging is ideally suited. These situations include visualization of striatal DaT in the evaluation of adult patients with suspected parkinsonian syndromes, early diagnosis of presynaptic parkinsonian syndromes, and differentiating ET from tremor due to presynaptic parkinsonian syndromes, which include PD, MSA, and PSP. The SNM guidelines also recommend DaTscan imaging for differentiating presynaptic parkinsonian syndromes from parkinsonism without presynaptic dopaminergic loss, as with drug-induced

■ **Sidebar 2. Guidelines for Diagnostic Use of DaTscan SPECT Imaging**^{12,14,25,37,38}

- EFNS/MDS-ES: “DaTscan SPECT is indicated in the presence of significant diagnostic uncertainty and particularly in patients presenting atypical tremor manifestations (level of evidence: A). All other SPECT imaging studies do not fulfill registration standards and cannot be recommended for routine clinical use.”¹⁴
- SNM: Situations for which DaTscan imaging is ideally suited: visualization of striatal DaT in the evaluation of adult patients with suspected parkinsonian syndromes; early diagnosis of presynaptic parkinsonian syndromes; differentiating ET from tremor due to presynaptic parkinsonian syndromes, which include PD, MSA, and PSP. DaTscan imaging is also recommended for differentiating presynaptic parkinsonian syndromes from parkinsonism without presynaptic dopaminergic loss, as with drug-induced parkinsonism or psychogenic parkinsonism, and also for differentiating DLB from AD.³⁷
- AAN: SPECT modalities are noted for their varying degrees of accuracy in distinguishing PD from ET and for which the AAN practice parameter stated that they are “possibly useful,” noting that insufficient evidence was available [at that time]^a to determine whether these modalities can distinguish PD from other kinds of parkinsonism.¹²
- NICE (UK): DaTscan imaging should be “considered for people with tremor where ET cannot be clinically differentiated from parkinsonism” and “available to specialists with expertise in its use and interpretation.”³⁸
- SIGN (UK): DaTscan imaging “Should be considered as an aid to clinical diagnosis in patients where there is uncertainty between PD and nondegenerative parkinsonism/tremor disorders.”²⁵

^aNote: The AAN practice parameter was published in 2006, prior to the approval of DaTscan in the United States.

AAN indicates American Academy of Neurology; AD, Alzheimer’s disease; DaT, dopamine transporter; DLB, dementia with Lewy bodies; EFNS/MDS-ES, European Federation of Neurological Societies and the European Section of the Movement Disorder Society; ET, essential tremor; NICE, National Institute for Health and Clinical Excellence; PD, Parkinson’s disease; PSP, progressive supranuclear palsy; SIGN, Scottish Intercollegiate Guidelines Network; SNM, Society of Nuclear Medicine; SPECT, single-photon emission computed tomography; UK, United Kingdom.

parkinsonism or psychogenic parkinsonism, and also for differentiating DLB from AD.³⁷

The current AAN practice parameter for PD was published in 2006 (before approval of DaTscan in the United States) and no comprehensive update has been developed. However, at the time, DaT SPECT imaging was cited as “possibly useful,” and it was noted that insufficient evidence was available to determine whether these modalities could distinguish PD from other kinds of parkinsonism.¹²

In the United Kingdom, the National Institute for Health and Clinical Excellence, which, in addition to clinical recommendations, is focused on national health policy in the context of a governmental single-payer system, recommended that DaTscan imaging be “considered for people with tremor where ET cannot be clinically differentiated from parkinsonism” and “available to specialists with expertise in its use and interpretation.”³⁸ Also from the United Kingdom, the Scottish Intercollegiate Guidelines Network stated that DaTscan SPECT “should be considered as an aid to clinical diagnosis in patients where there is uncertainty between PD and nondegenerative parkinsonism/tremor disorders.”²⁵

Proposed Algorithms for the Appropriate Use of DaTscan Imaging in the Diagnosis of Parkinson’s Disease and ET

Although clinical guidelines broadly define the scope of indicated use of DaTscan imaging in the diagnosis of PD and ET, they offer little detail regarding its appropriate and inappropriate use and where it belongs in the diagnostic work flow.

The following information is based on discussion among members of an expert panel consisting of specialists in the areas of movement disorders, nuclear imaging, and managed care. The panelists recognized the utility of DaTscan and engaged in discussions with the goal of providing guidance regarding the appropriate use of DaTscan SPECT imaging. The suggestions offered by the expert panel, and provided here, should be regarded as general guidance, in recognition of the fact that cases will arise that fall outside this clinical framework.

Appropriate Use of DaTscan SPECT Imaging

Table 3 provides recommendations from the expert panel regarding appropriate versus inappropriate use of DaTscan imaging. In general, appropriate use includes cases where: (1) PD diagnosis is uncertain; (2) tremor of uncertain etiology is present; and (3) nonmotor and/or supportive symptoms and features associated with PD are present but the classical motor syndrome is absent or atypical. Thus, appropriate use would include, for example, a patient with at least 1 motor symptom plus 1 nonmotor symptom such as hyposmia (impairment of sense of smell), rapid eye movement sleep behavior disorder, parasympathetic or sympathetic dysfunction, or neuropsychiatric symptoms.³⁹ Inappropriate use includes cases where a certain diagnosis has been ascertained, it is not a PD diagnosis, and greater diagnostic clarity is needed.

Table 3. Recommendations From the Expert Panel Regarding Appropriate and Inappropriate Use of DaTscan in Parkinson’s Disease

Appropriate	Inappropriate
<ul style="list-style-type: none"> • Uncertain diagnosis of PD <ul style="list-style-type: none"> o Non-classical presentation o Monosymptomatic o Atypical/unusual parkinsonism (see Table 4) o Incomplete parkinsonism • Tremor of uncertain etiology • Suspected DLB • PD patients as candidates for DBS • Nonmotor complex or supportive features in patients without established clinical diagnosis of PD <ul style="list-style-type: none"> o Constipation o Depression o Cognitive changes o Anosmia o Autonomic symptoms 	<ul style="list-style-type: none"> • Certain diagnosis of PD <ul style="list-style-type: none"> o Not appropriate for routine confirmation of PD diagnosis • Monitoring disease course (note: will become appropriate after introduction of DMTs) • Known PD mutation • Certain non-PD/non-ET diagnosis

DBS indicates deep brain stimulation; DLB, dementia with Lewy bodies; DMT, disease-modifying therapy; ET, essential tremor; PD, Parkinson’s disease.

Sidebar 3. Discussion Regarding “Appropriate Use” of DaTscan Imaging

Dr Cummings began the discussion by asking the panelists what constituted appropriate use of DaTscan imaging. A panelist responded, “Patients with an unclear presentation in which Parkinson’s is a reasonable possibility...patients with an uncertain diagnosis of Parkinson’s.” Further clarification was requested regarding “uncertain,” and 1 panelist mentioned distinguishing ET from PD, though ET may coexist with PD (as noted by another panelist). Use of DaTscan imaging in patients with nonmotor symptoms (eg, constipation, depression) in addition to ET was suggested by a panelist as an example of appropriate use of DaTscan imaging. However, constipation and depression were described as nonspecific symptoms, whereas the presence of rapid eye movement sleep behavior disorder might tip the scale further in favor of a diagnosis of PD, as would a family history of PD. Also, anosmia was mentioned as a key nonmotor symptom. The panelists noted that DaTscan imaging would be inappropriate in patients without motor symptoms. One panelist mentioned the clinically uncertain parkinsonian syndromes criteria, which are “monosymptomatic, atypical, or incomplete presentation of parkinsonian symptoms.” Another panelist mentioned that DaTscan imaging should be performed once per patient; multiple DaTscan imaging scans would be an example of

inappropriate use. DaTscan imaging would also be inappropriate in cases where the diagnosis is certain. The use of DaTscan imaging was also discussed in the context of deep brain stimulation surgery, in which case the diagnosis of ET versus PD would guide placement of the leads. DaTscan imaging would also be appropriate in cases of suspected psychogenic parkinsonism and drug-induced PD, and in patients with tremor of unknown origin. With regard to patients with DLB, the panelists noted that DaTscan imaging may be appropriate on a case-by-case basis, though the use of DaTscan imaging for all patients with dementia was not considered appropriate. The panelists concurred that DaTscan imaging should not be used for the routine confirmation of PD. The use of DaTscan imaging was also considered appropriate in patients with parkinsonian syndrome and comorbidities that may mask symptoms or complicate diagnosis, and for patients diagnosed with parkinsonian syndrome who do not respond to medication. The panelists also discussed the meaning of “atypical presentation” and “unusual presentation.” The panelists agreed that the recommendations would include common “atypical presentations,” and that these atypical cases constitute appropriate use. Throughout the discussion, Dr Cummings summarized and recorded the recommendations of the panel.

DaTscan imaging is currently perceived as inappropriate for disease monitoring due to a lack of regulatory validation in appropriately designed prospective trials (ie, it is not licensed for such an indication). DaTscan is currently being used in clinical trials to assess patient study eligibility (ie, whether patients have a DaT deficiency) and monitor changes in DaT density (eg, in the Parkinson Progression Marker Initiative 5-year follow-up study)⁴⁰ (see **Sidebar 3**).

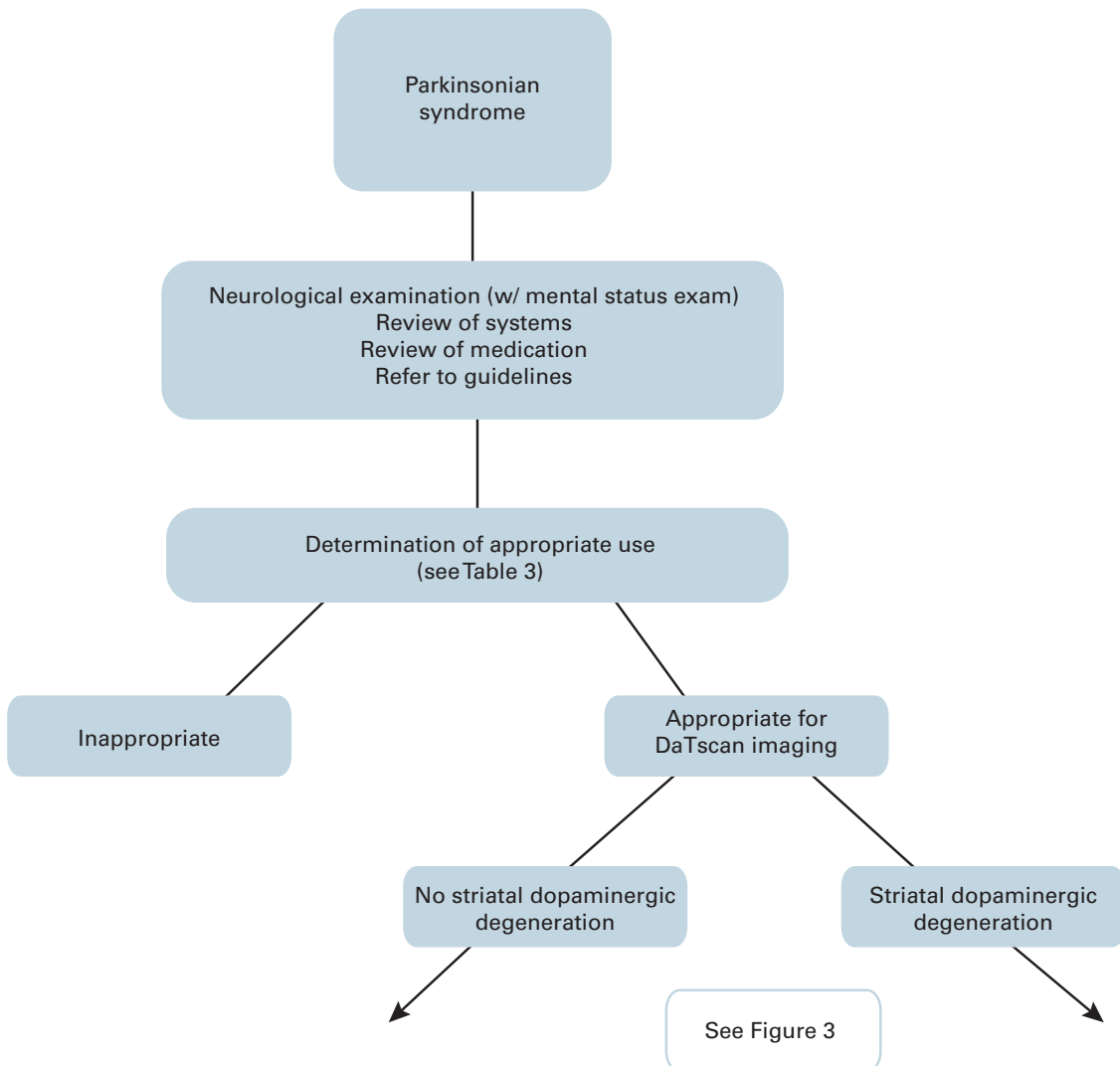
Table 4 offers criteria for a functional definition of atypical/unusual parkinsonism. The full and appropriate clinical utility of DaTscan SPECT imaging beyond its established diagnostic role remains to be elucidated. In addition to the criteria already noted for the appropriate

Table 4. Functional Definitions of Suspected/Clinically Uncertain/Atypical/Unusual Parkinsonism

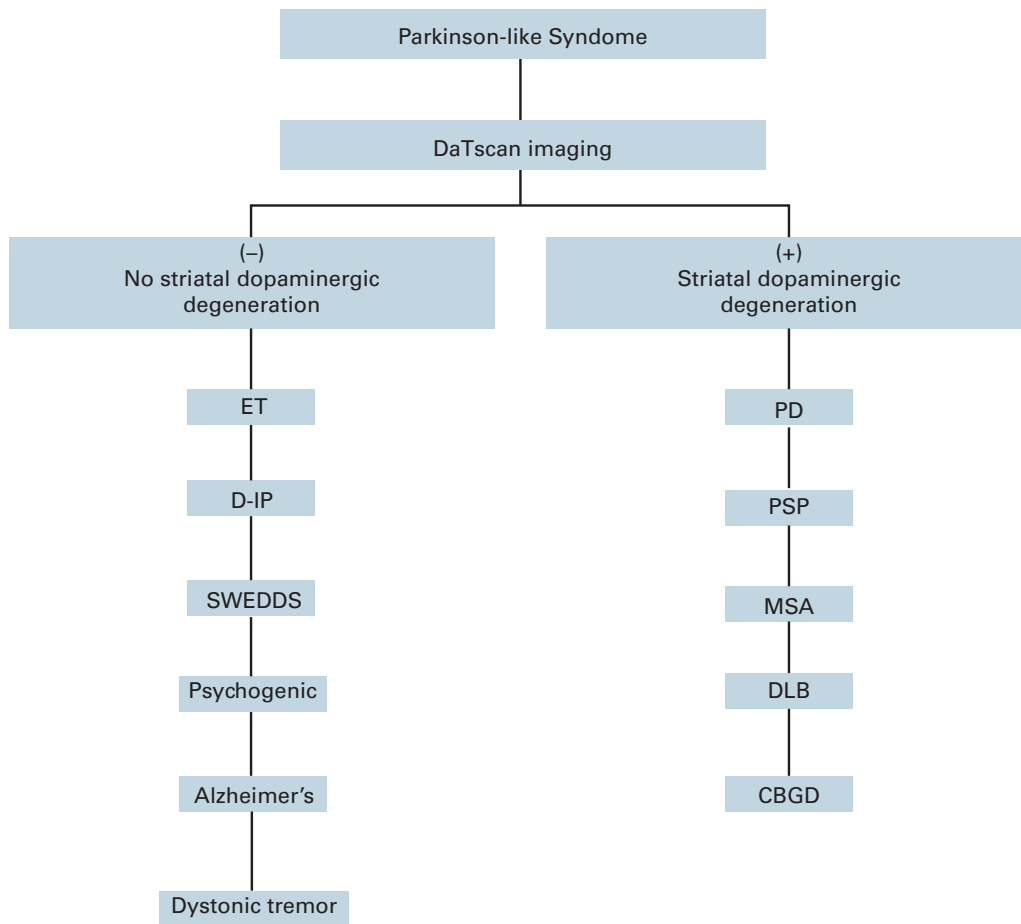
- Unusual or atypical or incomplete presentation
- Unusual disease course
- Unusual response, or lack of response, to treatment
- Unusual symptoms
- Early age of onset
- Unusual family history

and inappropriate use criteria in **Table 3**, it is important to further describe those patients for whom DaTscan SPECT

Figure 2. Diagnostic Algorithm for Patients With Parkinsonian Syndrome



■ **Figure 3.** Algorithm for Use of DaTscan Imaging in Patients With Parkinson-like Syndrome



CBGD indicates cortical basal ganglionic degeneration; D-IP, drug-induced Parkinsonism; DLB, dementia with Lewy bodies; ET, essential tremor; MSA, multiple system atrophy; PD, Parkinson's disease; PSP, progressive supranuclear palsy; SWEDDS, scans without evidence for dopaminergic deficit.

may be clinically useful. A provisional list includes the following:

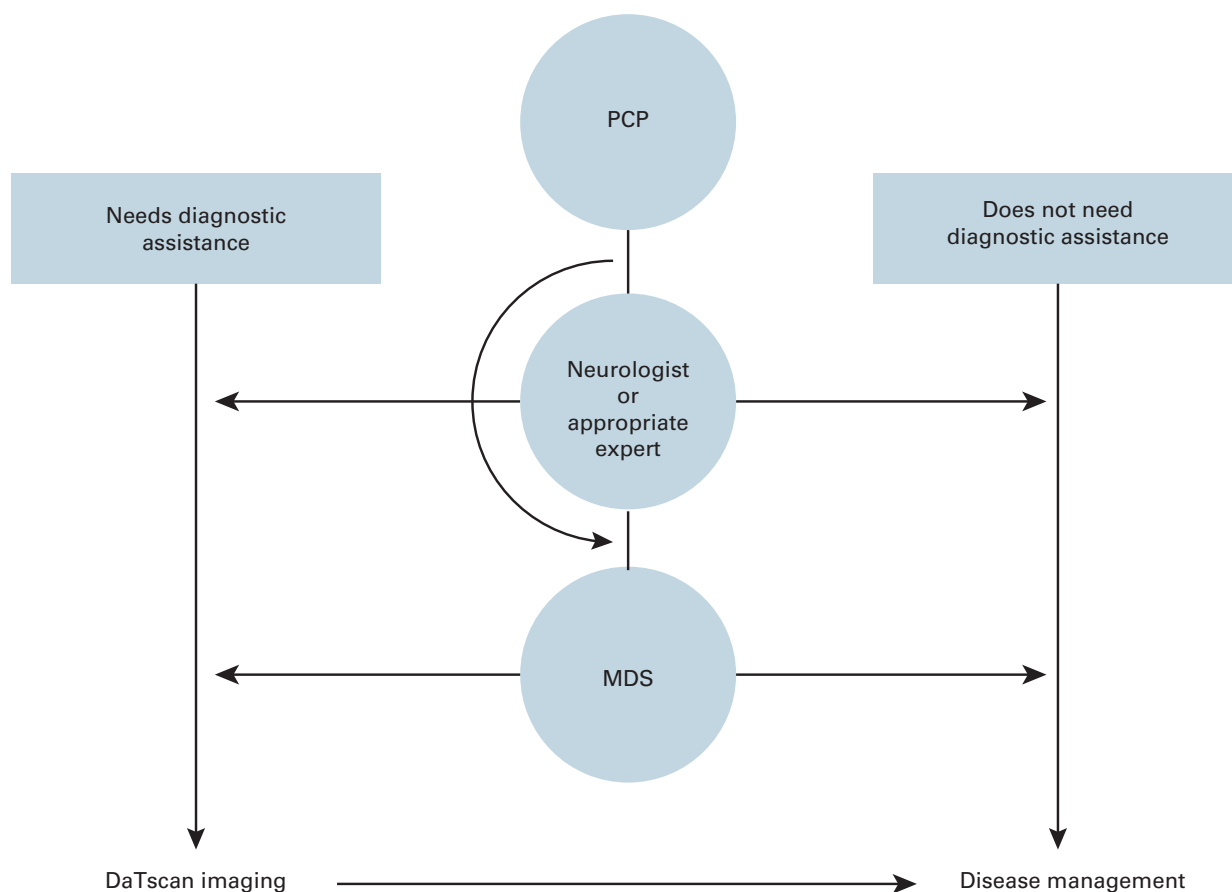
- Patients with suspected (or clinically uncertain) parkinsonian syndrome
- Patients diagnosed with parkinsonian syndrome and complicated comorbidities that may mask symptoms or otherwise make assessment difficult
- Patients diagnosed with parkinsonian syndrome on dopamine blockers or who are suspected of having drug-induced disease or where a vascular form of parkinsonism is possible
- Patients with tremor of uncertain etiology and suspected ET
- Patients who are candidates for deep brain stimulation
- Patients with suspected psychogenic parkinsonism
- Patients diagnosed with parkinsonian syndrome who are not responding to anti-Parkinson's treatment

- Patients in denial of the diagnosis of PD who might accept treatment if objective data were available

For patients with suspected DLB, DaTscan imaging may be appropriate, based on a case-by-case determination, particularly if a patient is experiencing autonomic disturbances, has demonstrated sensitivity to neuroleptic medications, or is receiving medications for PD. The DLB indication and differential diagnosis from AD are included in the European Union label,⁴¹ but they have not received approval from the FDA.

Figure 2 describes the diagnostic process for a patient with a parkinsonian syndrome, which includes a work-up consisting of a neurological examination with a mental status examination, a medication review (for ruling out drug-induced parkinsonism), and a review of systems (a history of cerebrovascular disease). Upon completion of these steps, it should be determined whether or not DaTscan

■ **Figure 4.** Practitioner Algorithm for Use of DaTscan Imaging in a PD/ET Diagnosis



ET indicates essential tremor; MDS, movement disorder specialist; PCP, primary care physician; PD, Parkinson’s disease.

■ **Sidebar 4.** Discussion Regarding DaTscan Use by Physician Specialty

The question of whether PCPs should be allowed to order DaTscan imaging was discussed, and some panelists noted that the majority of PCPs may find making a diagnosis of PD challenging. Thus, the panelists recommended that DaTscan imaging be ordered by general neurologists and MDSs. However, it was noted that some PCPs may have the appropriate expertise to order DaTscan. Thus, the term “appropriate experts” was used to denote the physician specialties which may order DaTscan for their patients. “Appropriate experts” may be general neurologists, MDSs, or expert PCPs (eg, gerontologists/geriatricians) on a case-by-case basis.

imaging is indicated (Tables 3 and 4). For those patients deemed appropriate for DaTscan imaging, **Figure 3** describes its use for detecting substantia nigra degeneration and the possible conditions associated with the presence or absence of such degeneration.

DaTscan Use by Physician Specialty

Although the panel recommends that DaTscan be ordered by a specialist with experience in diagnosing PD (see **Sidebar 4**), a PCP may be the first person to evaluate a patient with suspected early PD (**Figure 4**). Where the clinical or differential diagnosis is straightforward and confirmed, DaTscan imaging is not appropriate, and the next step will be to move toward disease management. Arriving at a certain diagnosis, however, is likely to require referral to an “appropriate expert,” who may be an expert PCP (eg, gerontologist/geriatrician), general neurologist, or MDS (movement disorder specialist). A non-expert PCP

Report

may refer patients to an MDS or general neurologist. The practitioner to whom a referral is made can then establish whether a diagnosis is straightforward, and if not, whether the other criteria indicate the appropriateness of DaTscan imaging.

Managed Care Considerations

Generally, MCOs concentrate their efforts on the most prevalent diseases affecting Americans (eg, diabetes, hypertension, AD) and focus less on rarer diseases such as PD, in large part due to limited resources and financial priorities. Thus, most MCOs do not have specific policies in place for the use of imaging agents in PD.

When assessing the utility of DaTscan imaging, it is important to note the clinical benefits that imaging with DaTscan may offer for a disease that is, in many cases, challenging to diagnose.² DaTscan imaging has been shown to confer more accurate diagnoses, resulting in frequent diagnostic and therapeutic revisions for patients with suspected PD, and major clinical guidelines recommend DaTscan imaging.^{12,14,25,37,38} An earlier and more accurate diagnosis of PD may have substantial benefits. Not only does it ensure that a patient's condition is correctly identified, but also that the patient is receiving appropriate treatment, while avoiding inappropriate and potentially harmful treatment. These factors are key in achieving improved outcomes and controlling the cost of care.

Future Research

Additional research should add to the body of evidence regarding DaTscan imaging in the diagnosis of degenerative parkinsonism and nondegenerative mimics (eg, ET). Potential research topics include:

- Real-world outcome/utility data of practitioner experience with DaTscan imaging
- Impact of DaTscan imaging on comorbidities and resource use
- Validation of appropriate use and promising future indications
- Cost modeling
- Quantitative (or semiquantitative) approach to supplement the visual read assessment

Such information would help MCOs further clarify the appropriate use of DaTscan in the diagnosis of PD and any promising new indications, and develop specific policies for its coverage.

Author affiliations: Cleveland Clinic Lou Ruvo Center For Brain Health, Las Vegas, NV, and Cleveland Clinic Lerner College of Medicine of Case Western Reserve University, Cleveland, OH (JLC); Health Net, Huntington Beach, CA (MJF); Medical Affairs, GE Healthcare-Life Sciences, Princeton, NJ (IDG); GE Healthcare-Life Sciences, Princeton, NJ (CRJ); Health Economics and Outcomes Research, GE Healthcare, Chalfont St Giles, UK (MKJ); Department of Medical Imaging and Departments of Medicine and Biomedical Engineering, University of Arizona, Tucson, AZ (PHK); National Parkinson Foundation, Miami, FL (JAO); Movement Disorders Center, Neuroscience Institute, Central DuPage Hospital, Winfield, IL (MR); Movement Disorders Center, Neurological Institute, University Hospitals, and Department of Neurology, Case Western Reserve University School of Medicine, Cleveland, OH (DER); SelectHealth, Murray, UT (KLS); The Parkinson and Movement Disorder Institute, Orange Coast Memorial Medical Center, Fountain Valley, CA (DT).

Funding source: This meeting and publication were supported by GE Healthcare, Princeton, NJ.

Author disclosure: Drs Cummings and Kuo report serving as a consultant/paid advisory board and receipt of honoraria from GE Healthcare. Dr Kuo also reports receipt of grants and lecture fees from GE Healthcare. Drs Grachev and Jarecke and Ms Johnson report employment with GE Healthcare. Dr Jarecke also reports stock ownership with GE Healthcare. Ms Oberdorf reports receipt of honoraria from GE Healthcare. Drs Fine, Rezak, Riley, Schaecher, and Truong report no relationship or financial interest with any entity that would pose a conflict of interest with the subject matter of this supplement.

Authorship information: Concept and design (JLC, MJF, IDG, CRJ, MKJ, PHK, MR, KLS, DT); acquisition of data (DER); analysis and interpretation of data (IDG, JAO, DT); drafting of the manuscript (JLC, MJF, CRJ, PHK, JAO, MR, KLS, DT); critical revision of the manuscript for important intellectual content (JLC, MJF, IDG, CRJ, MKJ, PHK, JAO, MR, DER, KLS, DT); provision of study materials or patients (IDG, MKJ); obtaining funding (IDG); administrative, technical, or logistic support (IDG); supervision (MKJ); participant at roundtable meeting (DER); and contribution at the roundtable for presenting information (CRJ).

Address correspondence to: Jeffrey L. Cummings, MD, ScD, Cleveland Clinic Lou Ruvo Center for Brain Health, 888 W Bonneville Ave, Las Vegas, NV 89106. E-mail: Cumminj@ccf.org.

REFERENCES

1. Barone P, Antonini A, Colosimo C, et al; PRIAMO study group. The PRIAMO study: a multicenter assessment of nonmotor symptoms and their impact on quality of life in Parkinson's disease. *Mov Disord*. 2009;24(11):1641-1649.
2. O'Brien JA, Ward A, Michels SL, Tziveleki S, Brandt NJ. Economic burden associated with Parkinson disease. *Drug Benefit Trends*. 2009;21(6):179-190.
3. Meara J, Bhowmick BK, Hobson P. Accuracy of diagnosis in patients with presumed Parkinson's disease. *Age Ageing*. 1999;28(2):99-102.
4. Marshall VL, Reiningger CB, Marquardt M, et al. Parkinson's disease is overdiagnosed clinically at baseline in diagnostically uncertain cases: a 3-year European multicenter study with repeat [123I]FP-CIT SPECT. *Mov Disord*. 2009;24(4):500-508.
5. National Collaborating Centre for Chronic Conditions. Parkinson's disease: national clinical guideline for diagnosis and management in primary and secondary care. London, UK: Royal College of Physicians; 2006.
6. DaTscan (loflupane I 123 Injection) [package insert]. Arlington Heights, IL: GE Healthcare; April 2011.
7. Nussbaum RL, Ellis CE. Alzheimer's disease and Parkinson's disease. *N Engl J Med*. 2003;348(14):1356-1364.
8. Parkinson's disease Q&A, sixth edition. Parkinson's Disease Foundation website. http://www.pdf.org/pdf/pubs_parkinson_qa_12.pdf. Accessed May 14, 2013.

9. Cummings JL, Henchcliffe C, Schaier S, et al. The role of dopaminergic imaging in patients with symptoms of dopaminergic system neurodegeneration. *Brain*. 2011;134(pt 11):3146-3166.
10. Schapira AH, Agid Y, Barone P, et al. Perspectives on recent advances in the understanding and treatment of Parkinson's disease. *Eur J Neurol*. 2009;16(10):1090-1099.
11. Nutt JG, Wooten GF. Clinical practice: diagnosis and initial management of Parkinson's disease. *N Engl J Med*. 2005;353(10):1021-1027.
12. Suchowersky O, Reich S, Perlmutter J, et al. Practice parameter: diagnosis and prognosis of new onset Parkinson's disease (an evidence-based review): report of the Quality Standards Subcommittee of the American Academy of Neurology. *Neurology*. 2006;66(7):968-975.
13. Hughes AJ, Daniel SE, Kilford L, Lees AJ. Accuracy of clinical diagnosis of idiopathic Parkinson's disease: a clinicopathological study of 100 cases. *J Neurol Neurosurg Psychiatry*. 1992;55(3):181-184.
14. Berardelli A, Wenning GK, Antonini A, et al. EFNS/MDS-ES/ENS [corrected] recommendations for the diagnosis of Parkinson's disease [published correction appears in *Eur J Neurol*. 2013;20(2):406]. *Eur J Neurol*. 2013;20(1):16-34.
15. Louis ED, Thawani SP, Andrews HF. Prevalence of essential tremor in a multiethnic, community-based study in northern Manhattan, New York, N.Y. *Neuroepidemiology*. 2009;32(3):208-214.
16. Parkinson's toolkit. National Parkinson Foundation website. <http://www.toolkit.parkinson.org>. Accessed April 30, 2013.
17. Bhidayasiri R. Differential diagnosis of common tremor syndromes. *Postgrad Med J*. 2005;81:756-762.
18. Schrag A, Ben-Shlomo Y, Quinn N. How valid is the clinical diagnosis of Parkinson's disease in the community? *J Neurol Neurosurg Psychiatry*. 2002;73(5):529-534.
19. Armstrong MJ, Litvan I, Lang AE, et al. Criteria for the diagnosis of corticobasal degeneration. *Neurology*. 2013;80(5):496-503.
20. Defebvre L. Myoclonus and extrapyramidal diseases. *Neurophysiol Clin*. 2006;36(5-6):319-325.
21. Thanvi, B, Lo Nelson, Robinson, T. Vascular parkinsonism—an important cause of parkinsonism in older people. *Age Ageing*. 2005;24:114-119.
22. Marek K. Dopaminergic dysfunction in parkinsonism: new lessons from imaging. *Neuroscientist*. 1999;5:333-340.
23. Fearnley JM, Lees AJ. Ageing and Parkinson's disease: substantia nigra regional selectivity. *Brain*. 1991;114(pt 5):2283-2301.
24. Marek K, Jennings D. Can we image premotor Parkinson disease? *Neurology*. 2009;72(7, suppl):S21-S26.
25. Scottish Intercollegiate Guidelines Network. Diagnosis and pharmacological management of Parkinson's disease: a national clinical guideline. Edinburgh, Scotland: Scottish Intercollegiate Guidelines Network; 2010.
26. Kupsch AR, Bajaj N, Weiland F, et al. Impact of DaTscan SPECT imaging on clinical management, diagnosis, confidence of diagnosis, quality of life, health resource use and safety in patients with clinically uncertain parkinsonian syndromes: a prospective 1-year follow-up of an open-label controlled study. *J Neurol Neurosurg Psychiatry*. 2012;83(6):620-628.
27. Jain S, Lo SE, Louis ED. Common misdiagnosis of a common neurological disorder: how are we misdiagnosing essential tremor? *Arch Neurol*. 2006;63(8):1100-1104.
28. Tolosa E, Borghet TV, Moreno E; DaTSCAN Clinically Uncertain Parkinsonian Syndromes Study Group. Accuracy of DaTSCAN (123I-ioflupane) SPECT in diagnosis of patients with clinically uncertain parkinsonism: 2-year follow-up of an open-label study. *Mov Disord*. 2007;22(16):2346-2351.
29. Kupsch A, Bajaj N, Weiland F, et al. Changes in clinical management and diagnosis following DaTscan SPECT imaging in patients with clinically uncertain parkinsonian syndromes: a 12-week follow-up study. *Neurodegener Dis*. 2013;11(1):22-32.
30. Catafau AM, Tolosa E; DaTSCAN Clinically Uncertain Parkinsonian Syndromes Study Group. Impact of dopamine transporter SPECT using 123I-ioflupane on diagnosis and management of patients with clinically uncertain Parkinsonian syndromes. *Mov Disord*. 2004;19(10):1175-1182.
31. Hauser RA, Grosset DG. [123I]FP-CIT (DaTscan) SPECT brain imaging in patients with suspected parkinsonian syndromes. *J Neuroimaging*. 2012;22(3):225-230.
32. Benadiba M, Luurtsema G, Wichert-Ana L, Buchpiguel CA, Busatto Filho G. New molecular targets for PET and SPECT imaging in neurodegenerative diseases. *Rev Bras Psiquiatr*. 2012;34(suppl 2):S125-S136.
33. Grachev I, Sherwin P, Lane D, et al. Safety profile of DaTscan™ (ioflupane I 123 Injection), a radiopharmaceutical indicated for visualization of the striatal dopamine transporter using SPECT. *J Nucl Med*. 2013;54(suppl 2):1781.
34. Benamer TS, Patterson J, Grosset DG, et al. Accurate differentiation of parkinsonism and essential tremor using visual assessment of [123I]-FP-CIT SPECT imaging: the [123I]-FP-CIT study group. *Mov Disord*. 2000;15(3):503-510.
35. Jennings DL, Seibyl JP, Oakes D, et al. (123I) beta-CIT and single-photon emission computed tomographic imaging vs clinical evaluation in Parkinsonian syndrome: unmasking an early diagnosis. *Arch Neurol*. 2004;61(8):1224-1229.
36. Seifert KD, Wiener JI. The impact of DaTscan on the diagnosis and management of movement disorders: a retrospective study. *Am J Neurodegener Dis*. 2013;2(1):29-34.
37. Djang DS, Janssen MJ, Bohnen N, et al. SNM practice guideline for dopamine transporter imaging with 123I-ioflupane SPECT 1.0. *J Nucl Med*. 2012;53(1):154-163.
38. Parkinson's disease: diagnosis and management in primary and secondary care. National Institute for Health and Care Excellence website. <http://www.nice.org.uk/CG035>. Accessed May 3, 2013.
39. Truong DD, Wolters EC. Recognition and management of Parkinson's disease during the premotor (prodromal) phase. *Expert Rev Neurother*. 2009;9(6):847-857.
40. Marek K, Jennings D, Lasch S, et al; Parkinson Progression Marker Initiative. The Parkinson Progression Marker Initiative (PPMI). *Prog Neurobiol*. 2011;95(4):629-635.
41. European Medicines Agency. EPAR – product information. http://www.ema.europa.eu/ema/index.jsp?curl=pages/medicines/human/medicines/000266/human_med_000739.jsp&mid=WC0b01ac058001d124. Published March 21, 2013. Accessed June 8, 2013.