

Possible Use of Ultrafast CT of Coronaries To Make Decisions in Hyperlipidemic Patients

Based on a presentation by Linda L. Demer, MD, PhD

Presentation Summary

Electron beam computed tomography (EBCT) can detect calcifications in the coronary vasculature in the absence of stenosis, whereas angiography does not allow visualization of calcium deposits. The amount of calcification demonstrated on EBCT correlates with the level of

atherosclerosis, and is also related to clinical outcome. EBCT is not a substitute for angiography, but the technique may have a role in risk stratification comparable to that of cholesterol level. The exact role EBCT could play in diagnosing and managing hyperlipidemic patients is not yet fully determined.

Use of ultrafast computed tomography (CT) or electron beam computed tomography (EBCT) in CHD is controversial. Ultrafast CT was rapidly commercialized before its clinical validity was established. However, ultrafast CT can measure vascular calcification, which is a marker for atherosclerosis but not necessarily for stenosis. Linda L. Demer, MD, PhD, Chief of the Division of Cardiology at the UCLA Medical Center in Los Angeles described the potential benefits of this relatively unexplored technology.

"CT scanning has an identity problem, because of its name. Early on, the type of computed tomography that images calcium in the coronary arteries was referred to as 'cine CT,'" explained Dr. Demer. "Later, it became known as ultrafast CT. It is also called electron beam CT scanning."

The main difference, according to Dr. Demer, between EBCT and ordinary CT scanning is that images are per-

formed extremely rapidly while freezing the motion of the heart. This technique allows imaging of calcium deposits not detectable on fluoroscopy or x-ray.

EBCT ... may have a role in risk stratification.

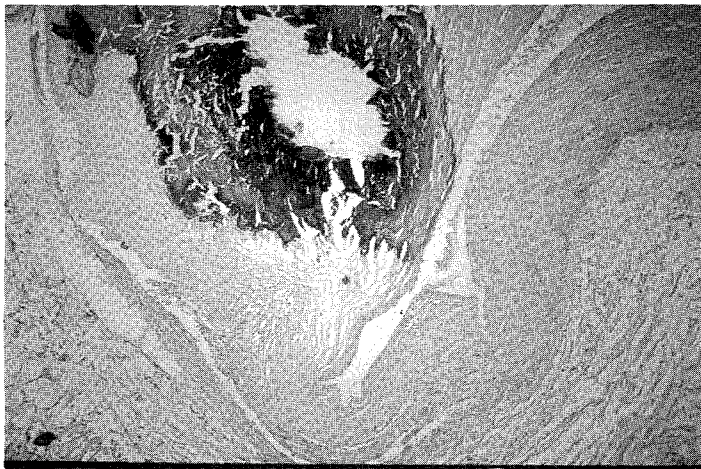
Characterization of Calcium Deposits

At both the imaging level and the histologic level, calcium deposits in the vasculature share characteristics of bone. EBCT identifies lesions that resemble osteoporotic bone and also shows evidence of bone resorption and remodeling, as seen in normal bone. A positive EBCT scan clearly shows coronary calcium deposits, as does x-ray (Figure 1). One important factor is that calcium deposits in the coronary arteries are as

dense as compact bone and sometimes even more dense than trabecular bone in the vertebrae.

A negative scan is determined by how many pixels receive a threshold value. If a pixel does not exceed the 130-unit

Figure 1. ECBT Scan Showing Coronary Calcium Deposits



threshold of brightness on the image, it is considered negative for calcium. There is some discussion in the field about the appropriate threshold level, Dr. Demer said. Some experts have argued that it should be lower to improve sensitivity. EBCT can also detect calcification in the aorta; scans show that calcium deposits in the aorta are as dense as bones of the spinal column.

"One of the things that EBCT reveals is a connection between aortic calcification and, paradoxically, osteoporosis. Another interesting point is that this type of calcification has been found in preliminary studies of a new genetically modified mouse that develops complete ossification of the aorta within 2 months of life," Dr. Demer elaborated.

Clinical Value of Detecting Calcification

The amount of vascular calcification seen on EBCT corresponds more closely to the amount of atherosclerotic plaque than to the degree of stenosis. To come up with a value to assign to the patient, CT images are analyzed by a number of different methods, including calcium score and calcium mass. Calcium score was the original method used to measure vascular calcification; the equation is density times volume of the multiple images of pixels with a density exceeding the threshold value. This equation in its original form assigns the peak density value to all pixels above threshold. Another score currently in use is calcium mass. That equation is: density times volume multiplied by a conversion factor.

Originally, EBCT was designed for screening and was sought as a substitute for angiography and stress testing. The sensitivity tended to be high, but the specificity tended to be lower.

"The sensitivity and specificity were adequate, but not at the level that would be desirable for screening," Dr. Demer told listeners. "Some people say EBCT is inaccurate, but I explain that the test can be very accurate for what it measures and very inaccurate for what it doesn't measure. What it doesn't seem to measure is the degree of angiographic stenosis," she added.

An important finding to come from the sensitivity/specificity discussion is that early atherosclerotic lesions do calcify. The fact that EBCT has a specificity of <50% means that many individuals have significant calcification without significant stenosis. Significant calcification almost always indicates the presence of atherosclerosis.

"This was a surprise, and it was only evident because EBCT provides intravascular arthroscopy," Dr. Demer explained.

There is good evidence that EBCT will be useful to evaluate symptomatic lesions. EBCT is also predictive for revascularization procedures and may be

useful for risk stratification. However, the screening value of EBCT remains questionable. A recent study showed that the amount of calcium measured by EBCT correlated with the amount of plaque.¹ This raised the question of why the technique does not evaluate stenosis. Perhaps EBCT cannot identify stenosis, because stenosis is caused by failure of arterial remodeling and compensatory enlargement of the vessel, suggested Dr. Demer. Thus, there may be much calcification and plaque through compensatory enlargement but the lumen remains patent.

"It may be that the calcium factor is telling us something. My view is that in general, a high cholesterol level indicates the patient is more likely to have cholesterol accumulating in the artery walls if the walls are susceptible. Similarly, a high degree of calcification indicates that the artery wall is susceptible," she elaborated.

Amount of Calcification Relates to Outcome

EBCT has been shown to have a high receiver operating curve (ROC) value and to be predictive in asymptomatic patients of clinical events, including revascularizations.² ROC is a measure of the value of the test and cutoff criteria. This measure avoids the problem in variations of specificity and sensitivity that depend on special criteria, she explained.

Another study found a good correlation between EBCT calcium score and coronary heart disease or myocardial infarction [RB Detrano, unpublished data]. In that study, EBCT appeared to be reliably predictive among symptomatic patients. A less clear relationship was seen in asymptomatic patients. These findings may relate to features of calcification, suggested Dr. Demer. Perhaps calcification is protective when it is extensive and harmful early in its development, she theorized.

Conclusion

EBCT is not a substitute for angiography. It is still too early to predict the exact role EBCT will have. Its usefulness may be comparable to that of a cholesterol level for risk stratification.

... REFERENCES ...

1. Rumberger JA, Simons DB, Fitzpatrick LA, Sheedy PF, Schwartz RS. Coronary artery calcium area by electron-beam computed tomography and coronary atherosclerotic plaque area: A histopathologic correlative study. *Circulation* 1995; 92:2157-2162.
2. Arad Y, Spadaro LA, Goodman K, et al. Predictive value of electron beam computed tomography of the coronary arteries: A 19-month follow-up of 1173 asymptomatic subjects. *Circulation* 1996;93:1951-1953.