

AMA/CME ARTICLE

Breast Reconstruction After Mastectomy

Paul R. Weiss, MD, FACS

This activity is designed for primary care physicians.

GOAL

To appreciate the significant advances and current techniques in breast reconstruction after mastectomy and realize the positive physical and emotional benefits to the patient.

OBJECTIVES

1. Understand basic and anatomic principles of breast reconstruction.
2. Discuss the options for breast reconstruction: a) immediate versus delayed; b) autologous tissue versus implant; and c) stages of reconstruction and ancillary procedures.
3. Provide a comprehensive overview of the risks and benefits of, as well as the alternatives to, each approach so primary care physicians can counsel patients effectively.

Breast reconstruction has evolved from comparatively crude and rudimentary beginnings more than a quarter century ago. Thanks to advances in plastic surgery, breast reconstructive pro-

cedures are now straightforward and can be performed at the time of mastectomy even when postoperative chemotherapy is anticipated. From an oncologic standpoint, immediate reconstruction does not influence prognosis. The reconstruction does not mask local recurrence, as recurrence usually occurs in the surgical scar and not deep within the breast tissue.

Importantly, skin-sparing mastectomy procedures offer the potential for better aesthetic results than ever before, and breast reconstruction is a critical determinant of a patient's post-mastectomy quality of life. Improved quality of life outcomes are clearly correlated with positive psychological effects, a reduced incidence of depression, and enhanced body image. Over time, all of these effects increase a patient's sense of well-being and this, in turn, can positively impact overall physical health.

As a result of the positive outcomes, and sometimes even cost savings associated with breast reconstruction, managed care plans are increasingly receptive to modified radical mastectomy with immediate reconstruction as an attractive alternative to lumpectomy with axillary lymph node dissection and radiation. A *modified radical mastectomy* involves removal of both the breast with the nipple-areola and the axillary lymph nodes in a formal dissection within identified landmarks. In addition, as we see more patients who have been treated with lumpectomy and radiation, it has become apparent that secondary deformities related to this procedure—such as peau d'orange of skin, significant soft tissue volume loss, and nipple-areola retraction resulting in asymmetry—are common. When a large lesion in a relatively small breast is treated with lumpectomy and radiation, deformity and asymmetry may be especially pronounced. These problems are difficult to treat, as further surgical manipulation of the irradiated breast and chest wall are associated with a significantly higher complication rate when compared with the non-irradiated field.

CONTINUING MEDICAL EDUCATION ACCREDITATION

The Long Island Jewish Medical Center, the Long Island campus for the Albert Einstein College of Medicine, designates this continuing medical education activity for 1 credit hour in Category 1 of the Physician's Recognition Award of the American Medical Association.

The Long Island Jewish Medical Center is accredited by the Accreditation Council for Continuing Medical Education (ACCME) to sponsor continuing medical education for physicians. This activity is cosponsored by the Johns Hopkins University School of Medicine.

This CME activity was planned and produced in accordance with the ACCME Essentials.

From the Albert Einstein College of Medicine, Bronx, NY
Address correspondence to: P.R. Weiss, MD, FACS, 1049 Fifth Avenue, Suite 2D, New York, NY 10028

It is important to understand that the physician does not always have alternatives, as mastectomy is sometimes the clear choice. As our knowledge of breast cancer becomes more sophisticated, treatment is becoming more specific to the specific histologic type of breast cancer. Ductal carcinoma-in-situ with or without microinvasive carcinoma, for example, mandate modified radical and total mastectomy, respectively.

While women may achieve a better aesthetic result with equal oncologic treatment consisting of mastectomy and immediate reconstruction, the issues are often clouded and the decision to undergo mastectomy is often difficult for the patient traumatized by the diagnosis of breast cancer to comprehend. A strong, interconnected support team of physicians is needed to support the patient. The patient should make her decision collaboratively with her primary care physician, surgeon, oncologist, and plastic surgeon. These healthcare providers need to work as a team to present the risks, benefits, and alternatives completely, explicitly, and as rapidly as possible after the cancer is diagnosed to avoid delay in treatment.

When mastectomy is the best treatment course, immediate reconstruction is preferable to delayed reconstruction for both the patient and insurer. It eliminates a period of breast absence, and patients who undergo immediate reconstruction appear to emerge from surgery in a better psychological and emotional frame of mind than patients who undergo mastectomy alone. Immediate reconstruction also obviates the need for additional hospitalization, surgery, anesthesia, and recovery time. In my experience, patients who have reconstructive surgery immediately after mastectomy with autologous tissue also appear to have better range of motion of the ipsilateral arm than women treated with mastectomy alone. This is likely because the replacement of living tissue lessens scarring and contracture. As a result, this may minimize or prevent additional expenses related to physical therapy, medications, and absence from work.

Overview of Basic Reconstruction Techniques

To best advise patients with breast cancer, primary care physicians should understand basic breast reconstruction techniques. The most common reconstructive techniques involve a two-phase procedure. In the first phase, the breast mound is created and allowed to heal. In the second phase, the breast shape is refined and the nipple-areola is created.

Commonly, the breast mound is created using either an implant with or without a tissue expander, or an autologous tissue reconstruction procedure, prefer-

ably with a transverse rectus abdominis musculocutaneous (TRAM) flap.

Phase I, Implants

After mastectomy, there is usually not enough remaining skin to allow primary implant placement, and tissue expansion is often required. Tissue expansion devices operate on the principle that the overlying skin expands and actually undergoes neoplasia, in the same way that the abdominal skin expands during pregnancy.

During reconstruction, an expander that can be inflated after surgery is placed in a submuscular pocket that the surgeon creates primarily beneath the pectoralis major muscle. The serratus anterior muscle may be used for lateral implant coverage, and some surgeons elevate the rectus fascia inferiorly for additional prosthesis coverage. Once the surgical wound has healed, the tissue is expanded weekly (or at some other convenient or appropriate interval) by injecting a filling port transcutaneously. This port is detected by palpation, or with a magnetic or metal detector. When the desired size is achieved, a permanent device is then placed during a straight forward surgical procedure.

Since 1991, when the Food and Drug Administration withdrew silicone-filled devices from the market, only saline-filled implants have been available. Investigative groups are now prospectively evaluating silicone gel-filled devices, as well as other fill materials, for breast reconstruction purposes.

Phase I, TRAM Flaps

Since the late 1970s, the musculocutaneous principle, which relies on blood flow from vessels within muscle into the overlying fat and skin via musculocutaneous perforating vessels, has been used widely in reconstructive plastic surgery. The TRAM flap relies on this principle and can usually provide adequate tissue without an implant.

To create a pedicle TRAM flap, the abdominal wall is undermined, and the skin island is dissected free. Next, the rectus abdominis muscle is dissected and divided inferiorly. During this dissection, the inferior epigastric artery, which is the dominant vessel to the rectus abdominis muscle, is divided. Blood flow then transfers entirely to the superior epigastric artery, reducing total blood flow to the flap. The musculocutaneous unit is then rotated under the abdominal wall flap into the breast wound defect. The immediate mastectomy wound (or a reopened wound when the procedure is delayed) is filled with the flap tissue. Abdominally, muscle fascia is repaired and the skin is

closed. Often, a flatter, more aesthetically pleasing appearance of the abdomen results.

Hartrampf¹ initially described a technique for maximizing blood supply and volume of viable tissue for the TRAM flap, and since then, many variations in technique have arisen. From this experience, we have learned that there are several important considerations when creating a TRAM flap:

- **Flap location.** Perforating vessels from the muscle to the skin island are more numerous in the periumbilical region and are essentially absent below the arcuate line (Figure 1), so moving the donor site superiorly on the abdominal wall improves flap blood flow.^{2,3}
- **Flap viability.** Since division of the inferior epigastric artery compromises blood flow to the pedicle TRAM flap, it is important to harvest tissue from zones with the most abundant blood flow from remaining vessels. Tissue in zone I [Figure 1], the area directly overlying the muscle, has the most abundant blood supply. In the area lateral to the rectus muscle (zone II), flow is reduced but is almost always adequate for survival. Crossing the midline becomes more problematic. Tissue from zone III (tissue originally overlying contralateral rectus abdominis muscle) is less reliable, and its viability must be assessed at surgery. Tissue from the area lateral to the contralateral rectus abdominis muscle (zone IV) should not be considered since it rarely has adequate circulation.

When breast reconstruction is delayed, the inferior epigastric vessels are divided during a separate procedure before flap transfer.⁴ This may be combined with flap elevation 10 to 21 days before transfer. These techniques can take advantage of the beneficial, physiologic response to ischemia, which can improve circulation of the flap. Specifically, these techniques can improve viability of zone III tissue, and otherwise high risk patients may be treated with greater success (see next bullet for more information on these risk factors).

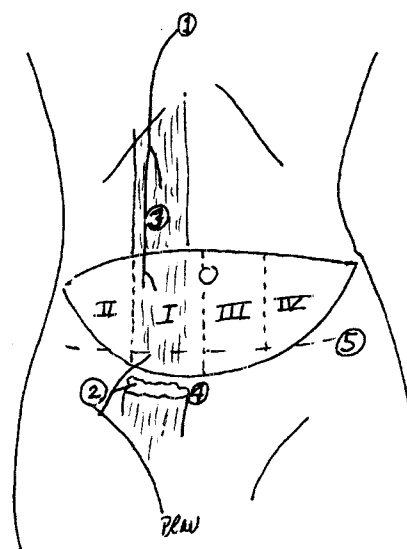
To enhance flap viability, some have attempted to harvest both rectus abdominis muscles (ie, the double pedicle procedure), but this technique is not recommended. In essence, this procedure allows harvesting from two zone I and two zone II regions. However, it can weaken the abdominal wall donor site, and reinforcement of the abdominal wall fascia with polypropylene or polytetrafluorethylene may be necessary to avoid weakness or pseudohernia. The procedure can

compromise the patient's ability to sit straight up from a lying position. With unilateral muscle harvest, abdominal wall problems are rare, and even the most athletic patients can return to pre-surgical activity.⁵

- **Risk factors.** Obesity, insulin dependent diabetes mellitus, hypertension, prior radiation therapy, and other organ diseases increase the risk of flap failure. Obese patients with abdominal wall pannus, in particular, are not suitable candidates for TRAM reconstruction, since circulation to the thick fat layer is uncertain. When reconstructing a field that has received prior radiation therapy, a much higher complication rate is expected due to vascular compromise. (For more information on these risks, see Potential Complications.)

The TRAM flap can also be raised as a free tissue transfer. So-called perforator flaps minimize muscular damage to the abdomen, including the rectus abdominal muscle and skin-fat flap. Microsurgical free flaps are appropriate in patients with a thin abdominal wall where a relatively large breast is to be constructed. Patients with risk factors such as smoking or diabetes mellitus may have better results with a microsurgical

Figure 1. Diagram of a Skin Island with Labeled Zones for a Right TRAM Flap



1 = superior epigastric artery; 2 = inferior epigastric artery-dominant pedicle; 3 = cut edge of rectus abdominis muscle; 4 = site of the division of the rectus abdominis muscle in a pedicle procedure; 5 = arcuate line

free flap. See Complications. The surgeon dissects the inferior epigastric vessels (arteries and veins) from the rectus abdominis muscle. These perforating vessels remain in continuity with the flap and are microsurgically anastomosed in the chest. There is no need for muscle transfer with this technique; the rectus abdominis muscle remains in place. The buttocks can also successfully serve as a donor site for microsurgical free tissue transfer.

The need for simultaneous, bilateral reconstruction is increasing, as prophylactic treatment of the contralateral breast is becoming more common for high-risk patients receiving treatment for breast cancer. Obviously, bilateral reconstruction is more costly than unilateral reconstruction, but it can prevent future expenses associated with hospitalization, surgery, and radiation. Treatment of bilateral breasts with tissue expanders and implants varies little from similar treatment of a single breast. With TRAM reconstruction, however, the donor site is divided in half, and this limits the volume of available tissue. Viability is more assured when bilateral TRAM reconstructions are performed simultaneously (as opposed to different times), as viable tissue from both zones I and II can be contained in both flaps. With simultaneous, bilateral procedures, tissue expansion reconstruction can easily be carried out simultaneously at each office visit, and symmetry is easier to achieve than with unilateral reconstructions.

Patients with prior mastectomy who may or may not have had reconstruction may also present for treatment of the contralateral breast. If a previous reconstruction was performed with a TRAM, a second TRAM flap cannot be harvested because the perforating vessels are divided in the first abdominal wall elevation. In this situation, tissue expansion, a latissimus dorsi musculocutaneous flap, or other methods must be used. While implant reconstruction is not influenced by prior reconstruction methods, caution must be exercised when a field treated with prior radiation therapy is encountered, as noted earlier.

Phase II

Once a breast mound is established, either through tissue expansion or a well-healed autologous musculocutaneous unit such as a TRAM flap, the second stage of reconstruction can begin. This stage usually begins 3 months to 6 months after the first stage is completed, although it may be postponed if needed for patient convenience or chemotherapy.

Numerous factors involving both the affected and contralateral breast must be considered when plan-

ning this second stage of reconstruction. If the opposite breast is of adequate size and shape with minimal ptosis (drooping from excess skin), the goal of reconstruction is to match the intact breast, and treatment of the intact breast is not indicated. The volume and/or position of breast tissue that has been expanded with a permanent implant may need to be adjusted, or the inframammary fold position or shape may require adjustment. A breast reconstructed with a TRAM flap can be contoured with direct excision of excess tissue or suction-assisted lipectomy (SAL). With SAL, fat is vacuumed from areas of excess using a blunt tip catheter connected to a suction device. Occasionally, after the TRAM flap procedure, the position of the island of tissue must be adjusted. This can be done safely with careful dissection of the musculocutaneous unit.


When the contralateral breast is of inadequate size or shape, or ptosis exists, treatment of this breast is needed to achieve symmetry. Thanks to the combined impact of public advocacy, legislative process, and the increasingly recognized importance of quality of life on the patient's short- and long-term physical well-being, managed care plans and insurers are now covering such procedures.

In these cases, careful preoperative evaluation to rule out malignancy in the contralateral breast—including examination, mammography, and other diagnostic techniques—is routine. Provided there are no oncologic implications, numerous procedures otherwise reserved for cosmetic purposes (ie, mastopexy, reduction mammoplasty, and augmentation mammoplasty with implants) may be used. When the contralateral breast is ptotic but exhibits adequate volume, a mastopexy is indicated. In this procedure, the nipple-areola is transposed to a higher position, and excess skin is excised. If volume is inadequate, a saline-filled implant may be added in either a submuscular (ie, below the pectoralis major muscle) or subglandular (ie, beneath breast parenchyma) position. When volume is too great, and this is common, reduction using a pedicle procedure is required. With this procedure, the nipple-areola remains attached to a de-epithelialized flap of tissue, breast parenchyma is removed, and the skin flaps are closed around the nipple-areola after raising it to a new position. Any removed tissue is submitted to pathology for examination. When mastopexy or reduction mammoplasty is used, there is usually enough excess areola to use for reconstruction of the neo-areola of the affected breast, thereby obviating the need for a separate donor site and providing good color match.

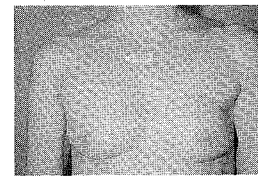
Figure 2. Photos Illustrating Various Stages of Breast Reconstruction



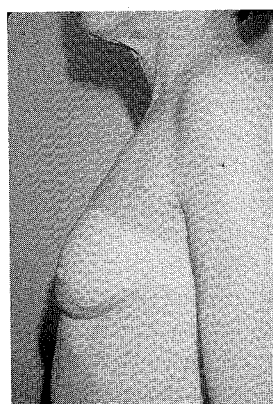
2a) Preoperative anterior view



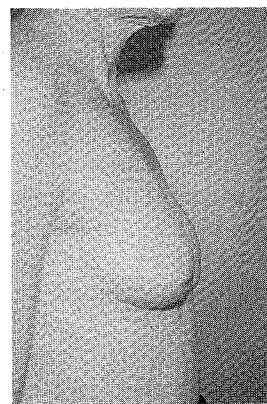
2b) Preoperative lateral view



2c) Postoperative completion of TRAM and nipple-areola



2d) Postoperative lateral view



2e) Postoperative lateral view

During this second stage, the nipple-areola for the affected breast is also created. The surgeon may choose from a number of flap techniques, but I prefer a skate flap, which is shaped like a sea skate. The "wings" of this flap wrap around a central mound to create the nipple. It is important to determine flap position with the patient standing, before she enters the operating room. The areola may be simulated with a full thickness graft from the opposite breast, inner thigh, or a dogear (ie, excess skin and soft tissue at the end of a surgical incision) from the previous surgery. Color match of the nipple and/or areola

is accomplished with tattoo techniques performed simultaneously or subsequently.

Potential Complications

Potential complications related to breast reconstruction must be carefully evaluated by the plastic surgeon before presenting recommendations to the patient and other treating physicians.⁶ As discussed earlier, obesity, insulin dependent diabetes mellitus, hypertension, prior radiation therapy, and other organ disease can pose significant increased risk for the patient. These conditions not only affect sur-

vival of the flap reconstruction but can cause other general complications related to surgery.

For all patients, the prolonged general anesthesia required for immediate or delayed reconstruction poses risks, although use of sequential compression devices during surgery and prompt postoperative mobilization of the patient lessen the risk of deep vein thrombophlebitis and pulmonary embolism. Prophylactic antibiotics have also proven valuable in reducing the incidence of infection and are especially important when a foreign body (implant) is placed.

Since there is increased blood loss from the combined mastectomy with immediate reconstruction, donation of one or two autologous units is encouraged as an additional precaution in case transfusion is necessary. Autologous donation stimulates bone marrow prior to surgical blood loss and provides the safest transfusion method. Careful planning of the reconstructive procedure with modifications dictated by various factors—both physiologic and anatomic—reduce complications of surgery.

Late complications of TRAM flaps include abdominal wall weakness, which may produce a visible bulge, with or without discomfort, and this may necessitate repair. Implants may undergo late capsular contracture, as the result of a foreign body reaction in which a fibrous capsule normally develops around the implant, although textured implants placed submuscularly appear to lessen this problem. This reaction may cause the breast to become firm, distorted, and painful. Removal, surgical capsulectomy, or capsulotomy with implant replacement may be needed. Surgical scars are rarely a problem and continue to improve with time.

Cost/Reimbursement of Immediate Breast Reconstruction

Overall, the option of immediate breast reconstruction is an ideal one. The hospitalization required for mastectomy with immediate tissue expander insertion is usually similar to that required for mastectomy alone. While the cost of the tissue expander, as well as contingent plastic surgery fees, need to be considered, these expenses are often justified by the benefits associated with quality of life. Patients are usually discharged after 4 or 5 days, often with an axillary drain in situ, which is removed when drainage volume falls to an appropriate level. In all reconstruction procedures, drains avoid late seroma formation in the donor and reconstructed sites. Immediate TRAM reconstruction patients may require 1 or 2 days of added hospitalization when compared with mastectomy alone.

For secondary procedures (delayed reconstruction), 1 to 2 days of hospitalization may be required for tissue expansion, and 4 to 7 days of hospitalization may be required for TRAM reconstruction. Second-stage procedures may be performed on an ambulatory basis, or over a 23-hour or 1-day admission to the hospital. General anesthesia is not always required for secondary procedures. Patients are advised in their initial consultation(s) that procedures for symmetry or nipple areola reconstruction are optional, and some patients elect to forego these procedures.

At the time of this writing, most insurance companies and health maintenance organizations, as well as Medicare and Medicaid, reimburse for reconstructive procedures. Health maintenance organizations and other managed care organizations reimburse the surgeon with a fee for service for these procedures (ie, reconstruction of the breast, reconstruction of the nipple, and achievement of symmetry of the contralateral breast) and in the form of a global fee to the hospital that is usually specified in the managed care contract.

Conclusion

Even when breast reconstruction is associated with additional costs over mastectomy alone, the overall advantages of breast reconstruction after mastectomy are obvious. Furthermore, with the exception of occasional and correctable problems related to implants, the results of breast reconstruction are permanent. In sum, I believe that breast reconstructions are among the safest and most gratifying surgical procedures available to women with breast cancer (Figure 2).

... REFERENCES ...

1. Hartrampf CE, ed. *Hartrampf's Breast Reconstruction with Living Tissue*. New York: Raven Press; 1991.
2. Moon HK, Taylor GI. The vascular anatomy of rectus abdominis musculocutaneous flaps based on the deep superior epigastric system. *Plast Reconstr Surg* 1988;82:815-832.
3. Slavin SA, Goldwyn RM. The midabdominal rectus myocutaneous flap: Review of 236 flaps. *Plast Reconstr Surg* 1988;81:189.
4. Restifo RJ, Ward BA, Scoutt LM, Brown JM, Taylor KJ. Timing, magnitude, and utility of surgical delay in the TRAM flap: part II. Clinical Studies. *Plast Reconstr Surg* 1997;99:1217-1223.
5. Mizgala CL, Hartrampf CR Jr, Bennett GK. Abdominal function after pedicled TRAM flap surgery. *Clin Plast Surg* 1994;21:255-272.
6. Vinton AL, Traverso LW, Zebring D. Immediate breast reconstruction following mastectomy is as safe as mastectomy alone. *Arch Surg* 1990;125:1303-1307.

CME QUESTIONS: TEST #039706

Long Island Jewish Medical Center and Johns Hopkins University School of Medicine are accredited by the Accreditation Council for Continuing Medical Education (ACCME) to sponsor continuing medical education for physicians. Long Island Jewish Medical Center, the Long Island Campus for the Albert Einstein College of Medicine, designates this continuing medical education activity for 1.0 credit hour in Category 1 of the Physician's Recognition Award of the American Medical Association. This CME activity was planned and produced in accordance with the ACCME Essentials and Standards for Commercial Support.

Instructions

After reading the article, "Breast Reconstruction After Mastectomy," select the best answer to each of the following questions. In order to receive 1 CME credit, at least 7 of the 10 answers must be correct. Estimated time for this activity is 1 hour. CME credits are distributed on a yearly basis.

1. Most local recurrences of breast cancer are in the mastectomy scar.
a) true
b) false
2. Zone III represents the most viable tissue for a TRAM flap.
a) true
b) false
3. Donor scars are more objectionable for TRAM versus latissimus dorsi flap reconstruction.
a) true
b) false
4. Autologous reconstruction produces the best aesthetic results.
a) true
b) false
5. Survival when mastectomy is combined with reconstruction is better than mastectomy alone.
a) true
b) false
6. Ductal carcinoma-in-situ can best be treated by lumpectomy and axillary dissection followed by radiation therapy.
a) true
b) false
7. Breast reconstruction utilizing a tissue expander and subsequent implant may be a better choice for the obese patient.
a) true
b) false
8. Delay procedures may be valuable to allow greater volume of tissue transfer in a TRAM reconstruction.
a) true
b) false
9. Benefits of breast reconstruction far outweigh the risks of the procedure chosen.
a) true
b) false
10. Few insurance companies and health maintenance organizations allow reimbursement for breast reconstruction.
a) true
b) false

AMA/CME TEST FORM

AJMC Test #039706

Breast Reconstruction
After Mastectomy

Application for 1 Credit
Hour of AMA Category I

(Test valid through
June 15, 1998.
No credit will be given
after this date.)

Please circle your answers:

1. a b
2. a b
3. a b
4. a b
5. a b
6. a b
7. a b
8. a b
9. a b
10. a b

(PLEASE PRINT CLEARLY)

Name _____
Address _____
City _____
State/Zip _____
Phone # _____

Please enclose a check for \$10, payable to
American Medical Publishing, and mail with this form to:

The AJMC CME Test
American Medical Publishing
1816 Englishtown Road, Suite 101
Old Bridge, NJ 08857