

## Otological Agents in the Treatment of the Draining Ear

*James C. Denny III, MD*

### **Abstract**

Otorrhea is the result of several pathologic conditions of the ear, including bacterial, fungal, and viral acute external otitis (AOE), acute otitis media with perforation (AOM), posttympanostomy tube otorrhea (PTTO), and chronic suppurative otitis media (CSOM). The significant differences among these conditions necessitate a thorough knowledge of the pathogenesis of each prior to the selection of a treatment regimen likely to succeed. Consideration must be given to the accelerating process of antimicrobial resistance, rising concern over ototoxicity, and limits on the resources available for healthcare in general. This article reviews the pathophysiology of AOE, AOM, PTTO, and CSOM and proposes treatment options that demonstrate the value of otological therapy as the first-line treatment option for AOE, PTTO, and CSOM with consideration given to efficacy as well as cost effectiveness. The growing concern with ototoxicity and resultant recent litigation issues are also discussed.

*(Am J Manag Care. 2002;8:S353-S360)*

**D**raining ears present both a medical and social problem for patients as well as their families. The purulent otorrhea is a sign of infection by either bacterial or fungal organisms in most circumstances, although instances of viral infection and allergic reactions also produce otorrhea. Acute otitis externa (AOE), swimmer's ear, is predominantly a bacterial infection, but may also result from mycotic or viral infections. In the case of chronic otitis externa, hypersensitivity reactions, most commonly from aminoglycosides, cause the majority of cases.<sup>1-3</sup> These patients typically have a thin,

watery drainage with chronic itching and hearing loss. Acute otitis media (AOM) is most frequently seen with an intact tympanic membrane, but not infrequently purulent otorrhea will develop following rupture of the tympanic membrane. Otorrhea following tube placement (PTTO) occurs in a significant number of patients, particularly in the pediatric age group. Another group of patients with purulent otorrhea are those with chronic perforations or mastoid cavities, resulting in chronic suppurative otitis media (CSOM). In addition to the infectious ramifications of otorrhea, the social stigma of the drainage are significant in the daycare and school settings. Primary care providers see the vast majority of patients with AOE, AOM, and PTTO on initial presentation and can successfully manage them on a routine basis provided they are aware of the predominant organisms associated with each condition and the steps necessary to eradicate these organisms.

Traditional management of otorrhea and its underlying cause has often included the use of systemic antibiotics in combination with antibiotic/antifungal drops. When using the combination of systemic and topical medications, the cost in many cases is elevated to well over \$100 per treatment. Research is showing increasing evidence of equal or superior efficacy of properly selected otological therapy compared to oral regimens.<sup>4,9</sup> When viewing this information in the context of rapidly escalating antibiotic resistance across the world, using topical products has its appeal. Topical otologic and ophthalmologic products have been presented to the

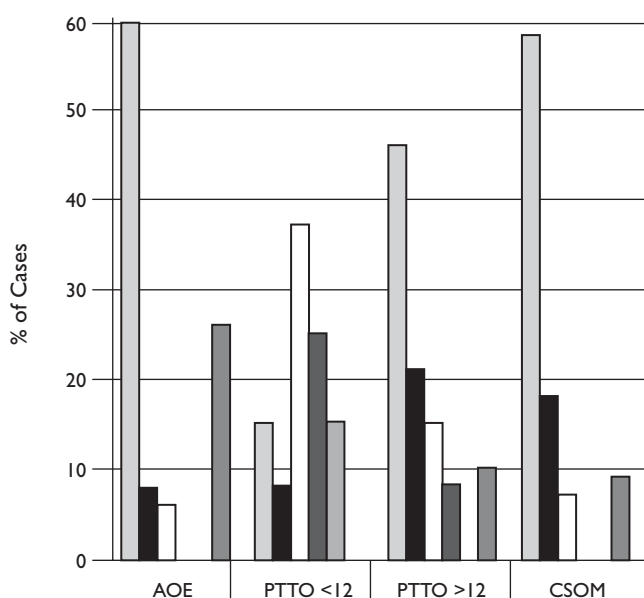
Food and Drug Administration (FDA) for approval for many years; to date there has been no information presented demonstrating the development of resistance to topical concentrations of susceptible antibiotics. Topical products can produce concentrations many times greater in the targeted tissue than those possible using systemic treatment. These concentrations do not seem to allow bacterial modification with resultant development of resistance or side effects.

When reviewing the spectrum of causative bacteria for the various types of otitis being discussed, both gram-positive

and gram-negative bacteria are important, particularly *Pseudomonas* species and resistant *Streptococcus* and *Staphylococcus* species (Figure). A large number of affected patients are in the pediatric age group, and no oral antibiotics that routinely cover *Pseudomonas* have been approved by the FDA for this age group. A number of topical products will safely eradicate gram-negative bacteria.

Topical treatment of draining ears dates back at least to the time of Socrates. Common preparations in the ancient world included red lead, resin, olive oil, goose grease, frankincense, cow's milk, and cream. On the Western frontier in the 1800s, rattlesnake oil (consisting of camphor, turpentine, menthol, and sassafras) was popular. Some of the older products that have been used in the 1900s, such as merthiolate, gentian violet, and benzoin, have been found to be ototoxic to the inner ear structures.<sup>10</sup> The ideal ototopical drop would cover the common pathogens, have proven efficacy, be safe, easy to use (low viscosity), painless (higher pH), nontoxic, and cost effective. It is appropriate to treat AOE, PTTO, CSOM, and some cases of AOM with perforation using topical therapy as the primary modality. An important point to emphasize is that topical therapy will have no therapeutic effect on concurrent systemic disease such as rhinosinusitis, adenotonsillitis, AOM without perforation, or tracheobronchitis.

Figure. Major Bacterial Pathogens



	AOE	PTTO <12	PTTO >12	CSOM
■ Pseudomonas	60	15	46	58
■ Staphylococcus	8	8	21	18
□ Streptococcus	6	37	15	7
■ Hemophilus		25	8	
■ Moraxella		15		
■ Other	26		10	9

AOE indicates acute otitis media; PTTO, posttympanostomy tube otorrhea; CSOM, chronic suppurative otitis media.

...ACUTE OTITIS EXTERNA...

The external auditory canal is a skin-lined tube that allows sound to travel to the tympanic membrane without playing a significant role in amplifying sound. The outer portion is cartilaginous, while the inner portion is bony. The skin over the cartilaginous portion is thick and adherent, while that covering the bony portion is thin and sensitive as well as being more susceptible to trauma. The skin in the outer cartilaginous area produces cerumen. Epithelial migration makes the external auditory canal self-cleaning in most circumstances. Cerumen

helps prevent bacterial growth by its acidic pH (6.1) and the fatty acids and lysozymes that are present. Cerumen also acts effectively to waterproof the external canal. The curved shape protects the tympanic membrane from injury. Cerumen impaction is by far the most common problem related to the external auditory canal and results in the most requests for treatment. Both the condition itself, and incomplete attempts to resolve the problem, result in a significant number of AOE cases.

AOE is an inflammatory process in the external auditory canal that can be caused by bacteria, fungi, or viruses. The normal flora of the canal contains both bacterial and fungal saprophytes that are not considered pathologic. Certain factors are well known to predispose an individual to inflammation of the external canal and subsequent otitis externa (Table 1). The most common of these are water exposure, foreign objects in the ear (such as earplugs and hearing aids), cerumen impaction, and underlying dermatologic conditions such as seborrheic dermatitis. When the external auditory canal swells, visualizing the tympanic membrane to determine its integrity is often impossible. Visualization of the tympanic membrane is essential when choosing topical therapy for otitis externa. The drops being used to treat the external canal will penetrate into the middle ear space if the tympanic membrane is not intact, which exposes the inner ear to potentially ototoxic products that may be selected.

The diagnosis of AOE is reasonably straightforward and involves taking a history, which usually involves water exposure, trauma, underlying immunocompromise, or diabetes alone or in combination with one of these other causes. The patients will usually report some combination of pain, itching, discharge, and hearing loss. Physical examination reveals a tender, swollen, erythematous canal and tragus with purulent drainage. When visualizing fungal otitis externa, the actual mycelia or other fungal elements may be seen. If possible, the tympanic membrane should be visualized. Severe

cases can result in cellulitis of the pinna or surrounding areas as well as lymphadenitis and systemic signs such as fever.

The differential diagnosis includes bacterial, mycotic, or viral (blisters often present) etiologies, eczema, psoriasis, keratosis obturans, canal cholesteatoma, and cancer. The most common bacterial pathogens are listed in the Figure.<sup>5,11-13</sup> By far the most prevalent of these is *Pseudomonas aeruginosa*, accounting for well over half of all infections. This is in significant contradistinction to AOM. Treatments suitable for AOM frequently are inappropriate for AOE because of the high percentage of *P aeruginosa* and *Staphylococcus aureus*.

Otomycosis is uncommon as a primary diagnosis. Fungal organisms may grow on desquamated epithelium and cerumen as simple saprophytes and in these circumstances, no treatment is necessary. In many cases, fungal infection results from prolonged treatment with broad-spectrum oral, intravenous, or topical antibiotics. True fungal otitis externa is caused by *Aspergillus* or *Candida* species.<sup>13</sup> Treatment of chronic fungal external otitis is difficult and can take prolonged periods to accomplish.

Treatment of AOE involves several important steps. Initially, one should try to clean as much debris as possible out of the canal itself. This can be done with suction, curette, an otowick, or under certain circumstances if the tympanic membrane is intact, by irrigation. The use of a wick,

**Table 1.** Factors Leading to Acute Otitis Externa

- Frequent swimming or water exposure
- Humid climate or season
- Anatomic problems (narrow, hairy canal)
- Trauma or foreign body insertion
- Cerumen impaction
- Dermatologic conditions
- Diabetes or immunocompromised state
- Devices for ear (hearing aids, earplugs)

whether commercially produced or home-made, is an extremely valuable adjunct both for debriding the canal and assuring delivery of topical medications. Given the well-defined patterns of infection, culturing the canal on initial treatment is usually not necessary and should be reserved for treatment failures. If possible, ascertaining the status of the tympanic membrane should be done first. Certain ototopical drugs used for treatment of both bacterial and mycotic infections are known to be ototoxic when introduced into the middle ear space and should be avoided when there is a known perforation of the tympanic membrane. If the tympanic membrane cannot be seen, the safest course is to treat the condition as if a perforation were present and use nonototoxic drops.<sup>14</sup>

After determining whether the infection is bacterial or fungal, the ototopical medication can be selected. For uncomplicated otitis externa, the vast majority of infections will respond to the appropriate topical medication. Because *Pseudomonas* accounts for roughly 60% of the bacterial infections, the most useful drops will contain either an aminoglycoside or fluoroquinolone as the active ingredient. Topical corticosteroids are available in some preparations and have been shown to hasten the resolution of pain by a several hours, but have not been shown to alter cure rates or times.<sup>15</sup> Adding systemic coverage to the treatment regimen does not appear to provide an advantage for uncomplicated AOE; it only serves to increase cost and possible side effects associated with the systemic product.

Fungal AOE will often respond to removal of debris and acidification alone with agents such as hydrocortisone with acetic acid, or vinegar. Topical antiseptics, such as gentian violet, have a role as long as the tympanic membrane is intact.<sup>10</sup> In patients with more severe or resistant infections, topical antifungals such as clotrimazole, miconazole, and nystatin are extremely effective. Rarely will systemic medications such as fluconazole be necessary.

### ...POSTTYMPANOSTOMY TUBE OTORRHEA ...

PTTO occurs following insertion of pressure-equalizing tubes in both the pediatric and adult population, but occurs most frequently in children. PTTO is most likely to occur during 2 distinct periods: during the first 2 weeks following surgery, with infection and the resultant otorrhea coming from either preexisting otitis media or contamination of the external auditory canal, and after the initial healing phase, when subsequent otorrhea is usually related to upper respiratory infections through nasopharyngeal reflux.<sup>14</sup> Whether water contamination, such as from bathing and swimming, plays a significant role is controversial; some otolaryngologists recommend strict water avoidance, while others have more limited restrictions.

The bacteriology of PTTO more closely resembles that of AOM than AOE, although *Pseudomonas* species and *S aureus* play a role as well. Older patients with PTTO have a higher percentage of these latter bacteria than the pediatric population. Typically, these older patients have been treated with systemic therapy. Many physicians have been concerned that ototopical medication would not penetrate into the middle ear space to eradicate the infection. According to a written communication from G. Gates, MD (May 2001), a recent study he has undertaken has conclusively proven that the medication in ototopical drops penetrates into the middle ear space in quantities sufficient to successfully treat these infections. Properly administered and appropriately selected drops have the advantage of high concentrations of antibiotics with broad efficiency, including against resistant *Streptococcus* and *Pseudomonas* species. This results in a significant therapeutic advantage, particularly in the pediatric population, for whom no oral agent has been approved by the FDA that covers *Pseudomonas* infection. Several studies have confirmed the efficacy of treating PTTO with ototopical drops as a single agent.<sup>4,9,14</sup> This reduces the systemic side

effects as well as the emergence of resistant bacteria. Treatment with the appropriate otopical medication significantly lowers cost when compared to treatment with oral medications and combination therapy (Table 2).

When prescribing otopical products, instructing the patient or family in proper delivery of the drops is important. The pinna is pulled posteriorly and the tragus should be gently pumped to allow penetration into the middle ear space. As with AOE, the otowick can be a valuable adjunct in the delivery of the drops in certain circumstances. The patient must lie with the affected ear up for adequate exposure to the drops unless a wick is in place. Recent evidence shows that otopical therapy has a place in treating AOM with perforation.<sup>16</sup> Using the same techniques as described above, particularly tragal pumping, this form of treatment can be valuable in patients with allergies to oral medications or those with resistant bacteria who have draining ears caused by AOM. More severe infections warrant combined therapy.

---

### ...CHRONIC SUPPURATIVE OTITIS MEDIA...

Patients with CSOM have perforations of the tympanic membrane that allow exposure of the middle ear space and the oval and round windows, similar to the exposure that occurs with a tympanostomy tube. Many of these patients also have exposed mastoid cavities and semicircular canals. These patients generally have a long-term problem that commonly involves multiple recurrent infections. These patients require chronic management to control rather than eliminate the problem. The bacteriology of CSOM closely approaches that of AOE, with *Pseudomonas* and *Staphylococcus* species being the predominant infecting organisms.

---

### ...TREATMENT OF THE DRAINING EAR...

When treating the draining ear, determining the cause of the drainage is essen-

tial. As previously discussed, the bacteriology of the different disease processes (AOE, PTTO, CSOM) varies significantly, and no single oral agent can be used for all 3 diseases in both the pediatric and adult populations. However, topical preparations are available as single-agent treatment that safely cover the standard organisms known to cause each disease. Keeping in mind the common organisms causing each type of draining ear, several factors are useful in selecting the agent best suited for each patient. The ideal otopical preparation covers the common pathogens, has proven efficacy, is safe with little or no toxicity, is easy to use (low viscosity), painless (higher pH), and is cost effective. In recent years, evidence of toxicity using a variety of drops has surfaced. Only products that minimize further patient problems as well as resolving the initial problem should be used.

Exposure of the middle ear space, whether in CSOM, PTTO, or AOM with perforation, carries with it the risk of ototoxicity. Ototoxicity is clearly a significant side effect of topically applied aminoglycosides.<sup>17-20</sup> The use of topical aminoglycosides can result in permanent hearing and/or balance problems. In addition to intravenous preparations, commercially available drops can cause this severe complication.<sup>21,22</sup> Topical aminoglycosides have long been used to denervate the vestibular system in patients with Meniere's disease. Unfortunately, the use of topical aminoglycosides has spawned a number of high-cost lawsuits related to ototoxicity. In a letter to physicians on November 21, 1996, a statement by the FDA noted that: "Neomycin can induce permanent Sensorineural Hearing Loss due to cochlear damage, mainly destruction of hair cells in the organ of Corti. The risk of ototoxicity increases with prolonged use; therefore, duration of therapy should be limited to 10 consecutive days." The Committee on Safety of Medicines (the equivalent of the FDA in Canada) stated in 1981 and 1998 that: "Doctors are reminded that topical treatment with aminoglycosides is contraindicated with tympanic membrane perforation." Some

of the nonantibiotic antiseptics such as merthiolate, cresylate, and gentian violet have also been shown to be ototoxic when used topically in patients with disrupted tympanic membranes. Propylene glycol, an additive to several drops, is also highly ototoxic. In addition, a marked increase in sensitivity to topical neomycin has been reported in the dermatology literature.<sup>1,2</sup> In many cases, this manifests as a failure to heal.

The successful use of ototopical products for both bacterial and fungal infections is dependent on the medication reaching the target tissue. Often this requires cleaning or debriding the canal. The use of otowicks facilitates both debridement and delivery of the product if the canal is obstructed. Ototopical prod-

ucts penetrate through a pressure-equalizing tube and a perforation of the tympanic membrane and subsequently have been shown to eradicate infection in these areas.

**Available Agents**

Eardrops have been used for many years, including commercially produced drops as well as homemade concoctions. Drops have contained antibiotics, antiseptics, antifungals, and a variety of other ingredients designed to acidify and sterilize the ear canal or middle ear. Ophthalmologic preparations, which are pH-balanced and unlikely to cause burning or irritation on contact, have also been popular alternatives that have been very effective. For years, concern was minimal as to whether collateral damage done to the auditory or vestibular systems was related to treatment. Any complications were felt to be directly related to the underlying disease process. When choosing an ototopical preparation, a number of variables must be considered. When choosing antibacterial agents, issues to be considered include the active antibiotic agent, the pH, whether a corticosteroid is needed, the viscosity, or whether an ophthalmologic product is better suited to the problem.

The most effective antibiotic preparations contain either an aminoglycoside or fluoroquinolone as the active ingredient. Historically, neomycin-based products have dominated the market for both otologic and ophthalmologic drops used in the ear. The availability of topical fluoroquinolone products has been a great advance over the last decade. These drops are extremely effective and do not carry the risk of ototoxicity when the middle ear or mastoid cavity is exposed. The only FDA-approved product for use in the middle ear is a fluoroquinolone drop, ofloxacin otic. The lower the pH, the more likely the patient will feel an uncomfortable, burning sensation as the drops are applied. Drops with a higher viscosity are more difficult to apply, particularly in pediatric patients. The addition of a topical corticosteroid in the drop preparation has been shown in a recent study

**Table 2.** Costs of Oral and Ototopical Products Used to Treat Ear Disease

Product	Cost (\$)*	Organisms Not Covered	Comments
<b>Oral preparations</b>			
Amoxicillin 80 mg/kg	25.00	Resistant strep, staph, <i>Pseudomonas</i>	
Augmentin 875 mg	115.00	<i>Pseudomonas</i>	
Avelox 400 mg	108.00	<i>Pseudomonas</i>	Adults only
Ceftin 500 mg	105.00	<i>Pseudomonas</i>	
Cipro 750 mg	117.00		Adults only
Levaquin 500mg	110.00		Adults only
<b>Topical preparations</b>			
Cortisporin (brand)	63.00		Possible ototoxicity
Cortisporin (generic)	34.00		
Cipro HC	87.50		FDA contraindicated in middle ear
Floxin otic	49.75		Only FDA-approved product for middle ear

\*These prices were an average of 4 pharmacy chains in Knoxville, Tennessee, on September 3, 2002. FDA indicates Food and Drug Administration.

**Table 3.** Otopical Antibiotic Preparations

Products	Active Ingredient	Dosing	Steroid	pH	FDA Status	Comments
Garamycin	gentamicin	tid	no	6.5	off label	possibly ototoxic
Tobrex	tobramycin	tid	no	6.5	off label	possibly ototoxic
Chloromycetin	chloramphenicol	qid	no	4.5	contraindicated ME	propylene glycol toxic
Ciloxan	ciprofloxacin	bid	no	4.5	off label	
Floxin	ofloxacin	bid	no	6.5	approved ME	
Ocuflox	ofloxacin	bid	no	4.5	off label	
Bleph 10	sulfacetimide	qid	no	<4	off label	weak <i>Staphylococcus</i> , <i>Pseudomonas</i> effect
Cortisporin susp	neomycin	qid	hydrocortisone	3.8		possibly ototoxic
Cortisporin sol	polymixin	qid	hydrocortisone	3	contraindicated ME	possibly ototoxic
Tobradex	tobramycin	tid	dexamethasone	6.8	off label	possibly ototoxic
Cipro HC	ciprofloxacin	bid	hydrocortisone	4.8	contraindicated ME	high viscosity

FDA indicates Food and Drug Administration; bid, twice daily; tid, 3 times daily; qid, 4 times daily; ME, middle ear.

to decrease the time to pain relief by several hours in AOE when comparing ciprofloxacin alone with a ciprofloxacin preparation containing hydrocortisone.<sup>15</sup> No evidence has shown that topical corticosteroids improve cure rates or decrease the time to cure. However, most otolaryngologists have observed a positive effect from the corticosteroids when treating resistant granulation problems. A representative listing of available products is seen in **Table 3**.

A recent study by Tom demonstrated the safety of a number of the antifungal drops for use in the middle ear space.<sup>23</sup> Treatment of fungal AOE has benefited from the wide availability of over-the-counter (OTC) products that are very effective in eradicating mycotic disease. The drops are more readily used for the external canal, while the creams are more effective for the pinna. Clotrimazole and tolnaftate are available OTC as drops, while miconazole and nystatin creams are also available as OTC products. As previously described, acidification is also quite beneficial and helps prevent recurrent disease.

A review of commonly used drops and their characteristics is presented in **Table 3**.

None of the ophthalmologic preparations have been presented for otologic use before the FDA, so their usage is outside of approved indications.

#### ...CONCLUSION...

Otopical therapy has proven to be efficacious in numerous studies as single-agent therapy for AOE, PTTO, and CSOM. These agents should be considered for the first-line treatment of all of these conditions. In cases of treatment failure, cultures are indicated prior to adding systemic medications. Treatment of AOE should include coverage for *P aeruginosa* unless a culture demonstrates otherwise. If the integrity of the tympanic membrane cannot be determined, when a tympanic membrane perforation is present, or a tympanostomy tube is in place, aminoglycosides should not be used as first-line treatment because of the risk for ototoxicity. If an aminoglycoside drop is selected for an open middle ear space, informed consent should be obtained from the patient or guardian. For patients with a tympanic membrane perforation or tympanostomy tube, ofloxacin otic is the only product approved by the FDA for use in

the middle ear. It is equally efficacious for AOE, thus it can be used for all 3 of these disease processes (AOE, PTTO, and CSOM). Ofloxacin otic also has the advantage of having a pH of 6.5, so it does not burn on administration. Otological agents provide superior efficacy at a lower cost than the systemic products or the combination of otological and systemic antibiotic medications. In addition, use of otological agents avoids systemic side effects and decreases development of resistant bacteria.

... REFERENCES ...

1. **Smith IM, Keay DG, Buxton PK.** Contact hypersensitivity in patients with chronic otitis externa. *Clin Otolaryngol.* 1990;15:155-158.
2. **VanGinkel CJW, Brintjes TD, Huizing EH.** Allergy due to topical medications in chronic otitis externa media. *Clin Otolaryngol.* 1995;20:326-328.
3. **Santuria BH, Marcus MD, Lucente FE.** *Diseases of the External Ear: An Otolgic-Dermatologic Manual.* New York, NY: Grune & Stratton; 1980.
4. **Coldblatt EL, Dohar J, Nozza RJ, Nielsen RW, Sidman JD.** Topical ofloxacin versus amoxicillin/clavulanate in purulent otorrhea in children with tympanostomy tubes. *Int J Pediatr Otorhinolaryngol.* 1998;46:91-101.
5. **Kiris M, Berktoos M.** The efficacy of topical ciprofloxacin in the treatment of chronic suppurative otitis media. *Ear Nose Throat J.* 1998;77:34-37.
6. **Esposito S, D'Errico G, Montanara C.** Topical and oral treatment of chronic otitis media with ciprofloxacin: a preliminary study. *Arch Otolaryngol Head Neck Surg.* 1990;116:557-559.
7. **Zipfel TE, Wood WE, Street DF, et al.** The effect of topical ciprofloxacin on post-operative otorrhea after tympanostomy tube insertion. *Am J Otol.* 1999;20:416-420.
8. **Dohar JE, Garner ET, Nielsen RW, et al.** Topical ofloxacin in the treatment of children with tympanostomy tubes. *Arch Otolaryngol Head Neck Surg.* 1999;125:537-545.
9. **Goldblatt E.** Efficacy of ofloxacin and other otic

- preparations for acute otitis media in patients with tympanostomy tubes. *Pediatr Infect Dis J.* 2001;20:116-119.
10. **Myer CM III.** Historical perspective in the use of otic antimicrobial agents. *Pediatr Infect Dis J.* 2001;20:98-101.
11. **Klein JO.** *In vitro* and *in vivo* antimicrobial activity of topical ofloxacin and other otological agents. *Pediatr Infect Dis J.* 2001;20:102-103.
12. **Mandel EM, Casselbrant ML, Kurs-Lasky M.** Acute otorrhea: bacteriology of a common complication of tympanostomy tubes. *Ann Otol Rhinol Laryngol.* 1994;103:713-718.
13. **Brook I, Frazier EH, Thompson DH.** Aerobic and anaerobic microbiology of external otitis. *Clin Infect Dis.* 1992;15:955-958.
14. **Hannley M, Denny JC, Holzer SS.** Use of otological antibiotics in treating 3 common ear diseases. *Otolaryngol Head Neck Surg.* 2000;122:934-940.
15. **Pistorius B, Westberry K, Drehobi M, et al.** Prospective, randomized, comparative trial of ciprofloxacin otic drops, with or without hydrocortisone vs. polymixin b-neomycin-hydrocortisone otic suspension in the treatment of acute diffuse otitis externa. *Infect Dis Clin Pract.* 1999;8:387-395.
16. **Bluestone CD.** Efficacy of ofloxacin and other otological preparations for chronic suppurative otitis media in children. *Pediatr Infect Dis J.* 2001;20:111-115.
17. **Bath AP, Walsh RM, Bance ML, Rutka JA.** Ototoxicity of topical gentamicin preparations. *Laryngoscope.* 1999;109:1088-1093.
18. **Helal A.** Aminoglycoside ear drops and ototoxicity. *Can Med Assoc J.* 1997;156:1056.
19. **Marais J, Rutka JA.** Ototoxicity and topical eardrops. *Clin Otolaryngol.* 1998;23:360-367.
20. **Wong D, Rutka JA.** Do aminoglycoside otic preparations cause ototoxicity in the presence of tympanic membrane perforations? *Otolaryngol Head Neck Surg.* 1997;116:404-410.
21. **Schuknecht HF.** Ablation therapy in the management of Meniere's disease. *Acta Otolaryngol (Stockh) Suppl.* 1957;132:1-42.
22. **Nedzelski JM, Bryce GE, Pfeleiderer AG.** Treatment of Meniere's disease with topical gentamicin: preliminary report. *J Otolaryngol.* 1992;21:95-101.
23. **Tom LWC.** Ototoxicity of common topical antimycotic preparations. *Laryngoscope.* 2000;110:509-516.