

# Ocular Toxicities of MEK Inhibitors in Patients With Cancer: A Systematic Review and Meta-analysis

Jing Han, MD<sup>1</sup>; Juejing Chen, MD<sup>2</sup>; Hanqiong Zhou, MD<sup>1</sup>; Lidan Hao,<sup>1</sup>; Qiming Wang, MD, PhD<sup>1</sup>

## ABSTRACT

**Background:** Mitogen-activated protein kinase (MEK) inhibitors, which integrate the important signaling chain of the RAS-RAF-MEK-ERK1/2 pathway, regulate cell functions such as division and proliferation for patients with solid tumors. However, various ocular adverse effects (AEs) affect patients during clinical treatment. This systematic review aimed to assess the occurrence of AEs during treatment with MEK inhibitors plus targeted therapy or chemotherapy.

**Methods:** A scientific literature search was conducted in PubMed, the Cochrane Library, Embase, and several Chinese databases to identify randomized controlled trials. Overall, ocular AEs were assessed as the primary end point; blurred vision, chorioretinopathy, and retinal detachment were assessed as secondary end points.

**Results:** Seventeen randomized controlled trials were included. Overall, the use of MEK inhibitors combined with other targeted inhibitors or chemotherapy was significantly associated with a nearly 7.3% increased risk of overall ocular toxicities vs therapy without MEK inhibitors (risk ratio [RR], 2.88; 95% CI, 1.42-5.85,  $P < .05$ ). An increased risk of blurred vision (RR, 4.10; 95% CI, 2.55-6.58;  $P < .05$ ), chorioretinopathy (RR, 8.36; 95% CI, 3.42-20.47;  $P < .05$ ), and retinal detachment (RR, 8.98; 95% CI, 3.92-20.57;  $P < .05$ ) was demonstrated.

**Conclusions:** Treatment with MEK inhibitors combined with targeted drugs or chemotherapy seems to increase overall ocular AEs. A more practical algorithm for the screening of ocular AEs was suggested to be conducted whenever new or worsening ocular toxicities occur.

## PERSPECTIVE

David L. DeRemer, PharmD, BCOP, and Bently P. Doonan, MD, MS, share a perspective on treatment options for ocular toxicities on [page 138](#).

**M**EK proteins are mitogen-activated protein kinase, an important downstream part of the RAS-mitogen-activated protein kinase (MAPK), also known as the RAS-RAF-MEK-ERK1/2 pathway, highly regulating and playing an important role in cell proliferation, differentiation, apoptosis, and stress responses.<sup>1</sup> Deregulation of the MAPK pathway occurs in more than 30% of various human cancers.<sup>2</sup> Many ongoing clinical trials or preclinical studies of corresponding drugs focus on targeting RAS, RAF, MEK, or ERK. For example, dabrafenib and vemurafenib significantly improved response rates, progression-free survival, and overall survival compared with chemotherapy in metastatic melanoma; however, resistance to treatment developed quickly in most patients. Hitherto, 4 MEK inhibitors have been developed and approved: 3 combined with v-raf murine sarcoma viral oncogene homolog B1 (*BRAF*) inhibitors to treat several *BRAF* V600 mutant solid tumors, and 1 for neurofibromatosis type.<sup>3-6</sup> Of note, apart from binimetinib, which is used only for melanoma,

trametinib has been indicated in combination with dabrafenib for melanoma, non–small cell lung cancer (NSCLC), anaplastic thyroid cancer, and other unresectable or metastatic solid tumors with *BRAF* V600E mutation in adult patients and pediatric patients 6 years and older.<sup>4</sup> Recently, cobimetinib has been newly indicated as a single agent for the treatment of adult patients with histiocytic neoplasms.<sup>6</sup>

Preclinical studies showed that MEK plays a critical role in maintaining the integrity of the retinal pigment epithelium (RPE) by protecting against various stresses, including oxidative stress, light-induced damage, and inflammation. The RPE is an epithelial barrier formed of RPE cells that maintains the outer blood-retinal barrier and is crucial for maintaining neural retinal function.<sup>7</sup> MEK inhibitors lead to acute RPE toxicity, which results in RPE hyperpermeability and breakdown of the retinal-blood barrier. Ocular toxicities are commonly associated with MEK inhibitors, aside from rash, diarrhea, fatigue, and elevated creatinine phosphokinase levels. Thus, this systematic review aimed to provide updated evidence of ocular toxicities related to MEK inhibitors combined with targeted therapy or chemotherapy and briefly discuss their management.

## Materials and Methods

### Search strategy

We performed a literature search of PubMed, the Cochrane Library, Embase, the Chinese National Knowledge Infrastructure, Wanfang Data, and Chinese Biomedical Literature from inception to November 11, 2020, with the last review performed on January 1, 2022. Keywords included *trametinib*, *binimetinib*, *selumetinib*, *cobimetinib*, *ocular*, and *eye*. A prospective protocol was created in advance and uploaded to the International Prospective Register of Systematic Reviews

(PROSPERO) online platform (registration No. CRD42021235589).

### Selection criteria and quality assessment

Two reviewers read titles, abstracts, or full texts to identify potential articles that met the inclusion criteria. Studies included in this meta-analysis were required to have (1) a randomized controlled trial (RCT) design, (2) patients with cancer undergoing MEK inhibitor therapy, and (3) eye-related adverse effects (AEs) reported in the outcomes.

Cochrane Collaborations' tool for assessing the risk of bias was used to assess the quality of included studies by 2 independent researchers. The items included in this tool were random sequence generation, allocation concealment, blinding of participants and personnel, blinding of outcome assessment, incomplete outcome data, and selective reporting.

### Data extraction and outcome measures

Two investigators (JH and HZ) independently extracted data from included studies. Disagreements were resolved by consensus or by involving a third review author (JC). Data extracted from studies included study characteristics, patient characteristics, details regarding MEK inhibitor and placebo groups, and outcome measures. The primary end points were clinical events (overall eye-related AEs). The secondary end points incorporated specific ocular AEs (retinal detachment, chorioretinopathy, and blurred vision).

### Statistical analysis

This meta-analysis was performed using a statistical software program (Stata version 15.0; StataCorp LP). Outcome data were extracted as risk ratios (RRs) and 95% CIs. Random-effects models were used for all outcomes because of differences in study

participants and length of follow-up. The Cochran *Q* test and the *I*<sup>2</sup> test were performed to assess the heterogeneity of the summary effects. If the *P* value of the Cochran *Q* test was less than .01 and *I*<sup>2</sup> was greater than 50%, heterogeneity was considered to exist.

### Assessment of risk of bias in included studies

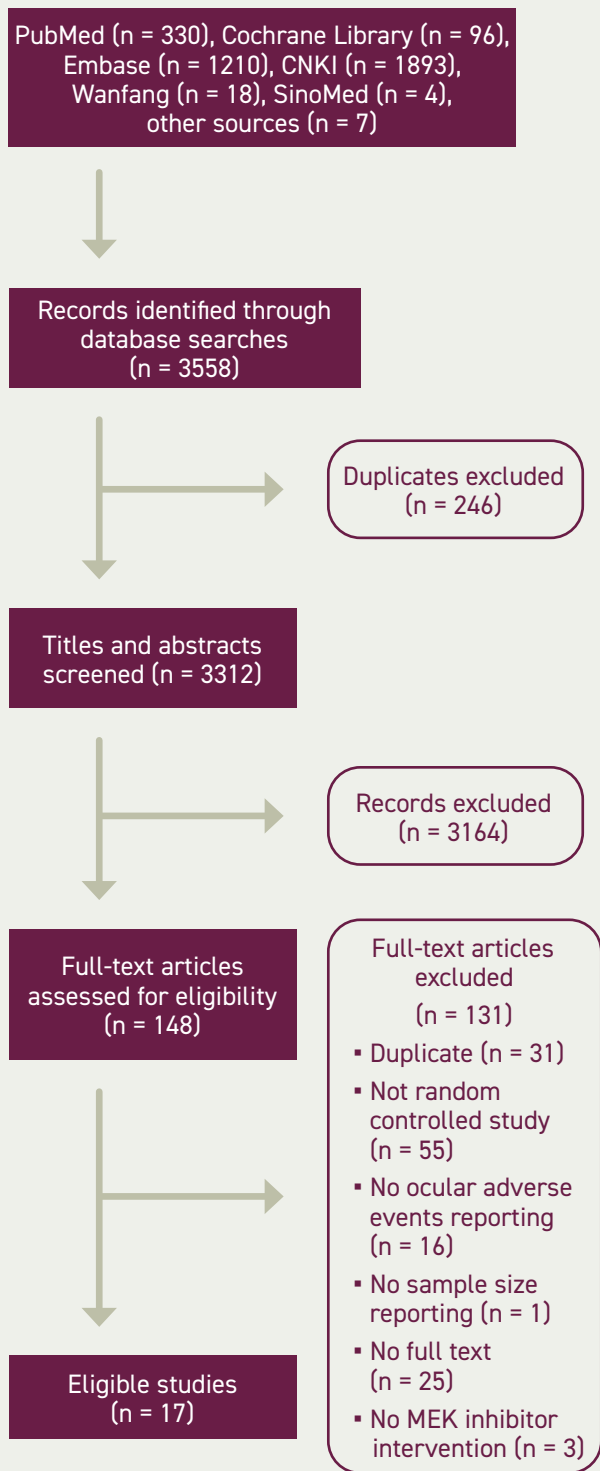
Two review authors (JH and HZ) independently assessed risk of bias for each study using the criteria outlined in the *Cochrane Handbook for Systematic Reviews of Interventions*. We resolved disagreements by discussion or by involving a third review author (JC). We assessed the risk of bias according to the following domains: random sequence generation, allocation concealment, blinding of outcome assessment, incomplete outcome data, selective outcome reporting, and other biases. We graded each potential source of bias as high, low, or unclear risk and provided a quote from the study report together with a justification for our judgment in the risk of bias table. Publication bias was evaluated using a funnel plot of the effect sizes and standard errors of the studies. The Egger regression test was used to examine funnel plot asymmetry. Publication bias was considered to be present if the funnel plot was asymmetrical or the *P* value from the Egger test was less than .10.

## Results

### Systematic review and selection

The electronic searches identified 3558 records by searching databases and hand-searching relevant bibliographies. Relevant studies were identified according to the flow diagram in **Figure 1**. We excluded 246 duplicate records and screened 3312 records, of which 148 were identified as potentially eligible and obtained as full-text manuscripts. After a full-text screening, we considered

FIGURE 1. Literature Research



CNKI, Chinese National Knowledge Infrastructure.

17 studies eligible for inclusion in this review.

**Study characteristics**

After reading all the text, 17 studies (9 with double-blinded design, 6 with open-label design, 1 with single-blinded design, and 1 with design not mentioned) were included in the final analysis according to the selection criteria, which contained 16 RCTs (Table 1) and the coBRIM clinical trial, which reported secondary end points in 2 studies. Among these studies, 8 were phase 3 and 9 were phase 2, and all included treatment with MEK inhibitors: 3 with a single MEK inhibitor, 9 with a combination of MEK and other targeted inhibitors (such as BRAF inhibitors or epidermal growth factor receptor [EGFR], tyrosine kinase inhibitors, and estrogen antagonists), and 5 with a combination of MEK inhibitors and chemotherapy (such as dacarbazine, gemcitabine, or docetaxel). The MEK inhibitors covered in this study included trametinib, selumetinib, cobimetinib, binimetinib, and pimasertib. In all trials, the pathologic conditions included were colorectal cancer, bladder cancer, melanoma, pancreatic adenocarcinoma, NSCLC, or breast cancer. The criteria used for ocular AE classification was the National Cancer Institute Common Toxicity Criteria for Adverse Events version 3 or 4.

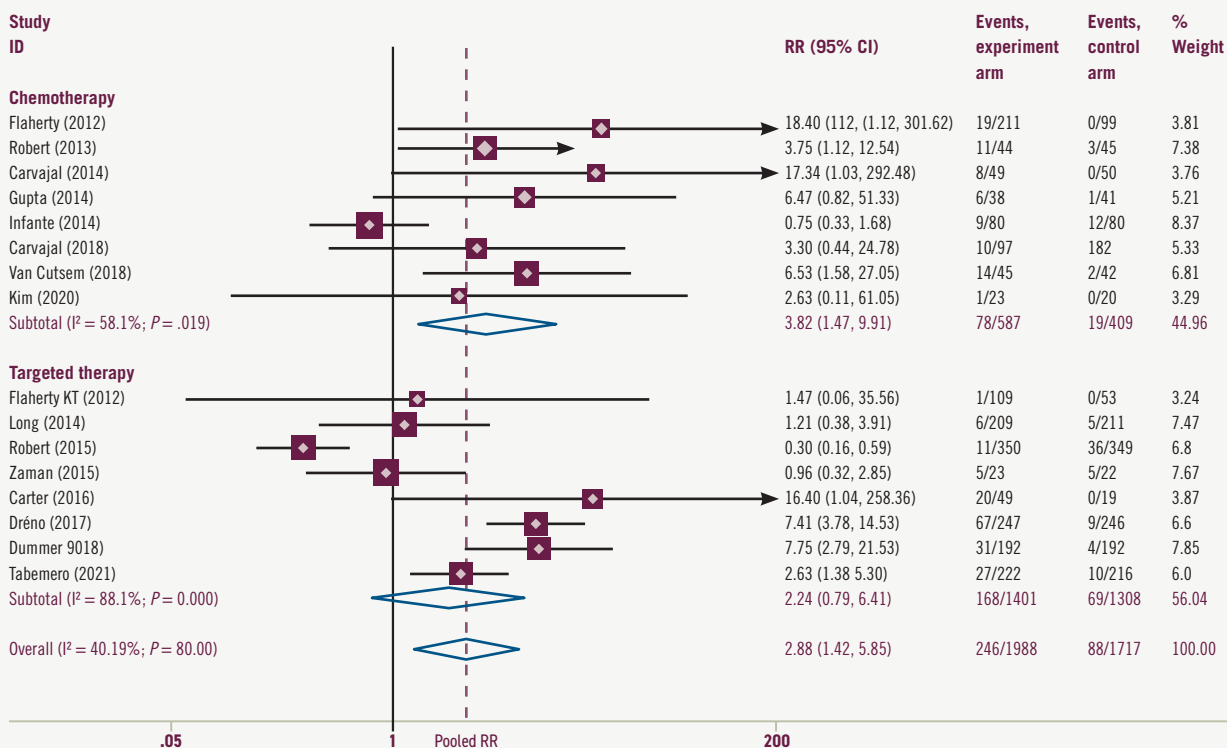
**Overall ocular AEs**

We performed data analyses for the following comparisons and subgroup analyses. Where applicable, we performed prespecified sensitivity analyses as noted in the Sensitivity Analysis and Risk of Bias section. The use of MEK inhibitors with or without other targeted inhibitors or chemotherapy (vs targeted therapy or chemotherapy without MEK inhibitors) was significantly associated with a nearly 7.3% increased risk of the overall ocular toxicities in a random-effects model meta-analysis of 16 RCTs (RR, 2.88; 95% CI, 1.42-5.85;  $P < .05$ ) (Figure 2). The risks of all grades of ocular toxicities were 12.4% and 5.1% in the experimental and control arms, respectively.

Subgroup analyses showed that MEK inhibitor monotherapy or therapy with MEK inhibitors plus chemotherapy (vs chemotherapy with or without placebo) was significantly associated with an 8.7% increased risk of ocular AEs in 8 RCTs (RR, 3.82; 95% CI, 1.47-9.91;  $P < .05$ ) (Figure 2). The risks of all grades of ocular toxicities in this chemotherapy subgroup were 13.3% and 4.6% in the experimental and control arms, respectively.

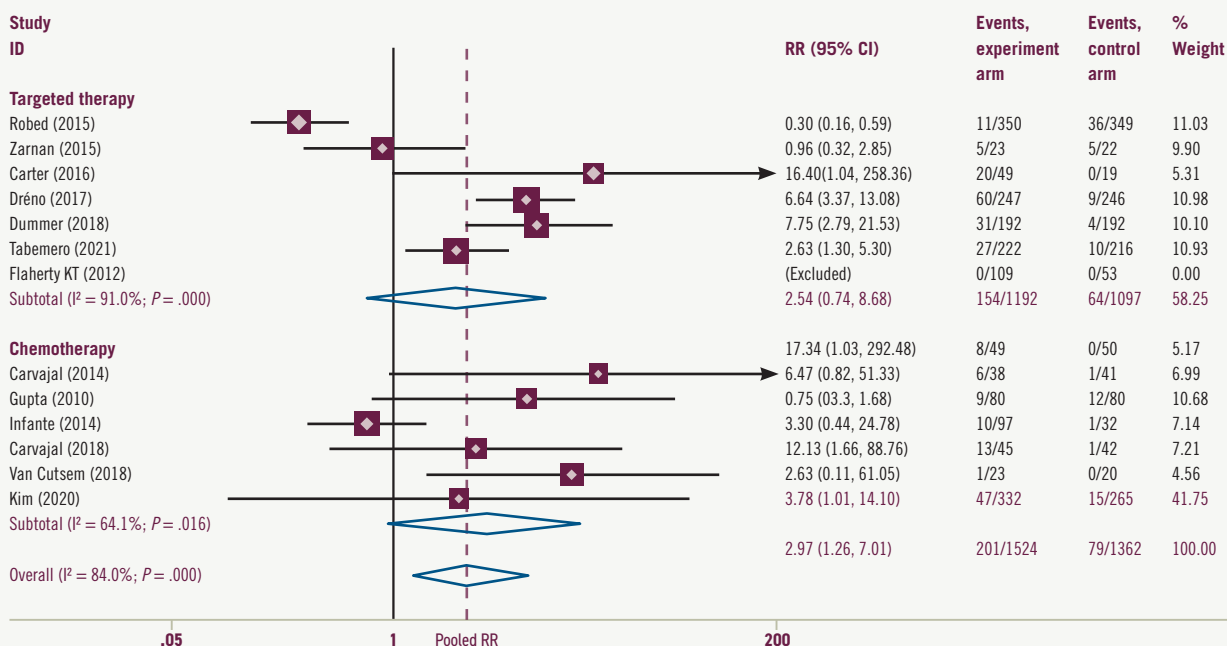
The results trend for all grades was similar in the targeted therapy subgroup, with 12.0% and 5.3% in the experimental and control arms, respectively. The

**FIGURE 2. Total Ocular Adverse Effect and Subgroup Analysis**



NOTE: Weights are from random effects analysis. RR, risk ratio.

**FIGURE 3. Total Ocular Grade 1/2 Adverse Effect and Subgroup Analysis**



NOTE: Weights are from random effects analysis. RR, risk ratio.

TABLE 1. Characteristics of the Included Studies

Source	Region	NCT No.	Phase	Cancer
Tabernero et al, <sup>8</sup> 2021	Worldwide	02928224	3	<i>BRAF</i> V600E–mutated metastatic colorectal cancer
Kim et al, <sup>9</sup> 2020	USA	02042443	2	Unresectable, locally advanced, or metastatic intra- or extrahepatic biliary system or gall bladder cancer
Carvajal et al, <sup>10</sup> 2018	Worldwide	01974752	3	Metastatic uveal melanoma
Dummer et al, <sup>11</sup> 2018	Worldwide	01909453	3	Locally advanced, unresectable, or metastatic cutaneous melanoma or unknown primary melanoma classified as stage IIIB, IIIC, or IV
Van Cutsem et al, <sup>12</sup> 2018	Europe	01016483	2	Metastatic pancreatic adenocarcinoma
de la Cruz-Merino et al, <sup>13</sup> 2017	Worldwide	01689519	3	<i>BRAF</i> V600 mutation–positive unresectable stage IIIC or IV melanoma
Dréno et al, <sup>14</sup> 2017	Worldwide	01689519	3	<i>BRAF</i> V600 mutation–positive unresectable stage IIIC or IV melanoma
Carter et al, <sup>15</sup> 2016	USA	–	2	KRAS wild-type advanced NSCLC
Zaman et al, <sup>16</sup> 2015	Switzerland, Belgium	–	2	Advanced-stage endocrine-sensitive (estrogen (ER) and/or progesterone receptors (PgR)≥10%) breast cancer
Robert et al, <sup>17</sup> 2015	Worldwide	01597908	3	Unresectable stage IIIC or IV melanoma with <i>BRAF</i> V600E or V600K mutations
Carvajal et al, <sup>18</sup> 2014	USA	01143402	2	Metastatic uveal melanoma
Long et al, <sup>19</sup> 2014	Worldwide	01584648	3	Unresectable stage IIIC or IV melanoma with a <i>BRAF</i> V600E or V600K mutation
Gupta et al, <sup>20</sup> 2014	UK	01256359	2	Unresectable stage 3 or 4 <i>BRAF</i> wild-type melanoma
Infante et al, <sup>21</sup> 2014	Worldwide	01231581	2	Previous untreated metastatic pancreatic adenocarcinoma
Robert et al, <sup>22</sup> 2013	Worldwide	00936221	2	Stage III and IV, <i>BRAF</i> –mutant, cutaneous, or unknown primary melanoma
Flaherty et al, <sup>23</sup> 2012	Worldwide	01245062	3	Metastatic melanoma with a <i>BRAF</i> V600E or V600K mutation
Flaherty et al, <sup>24</sup> 2012	USA and Australia	01072175	2	Metastatic melanoma with either <i>BRAF</i> V600E or V600K mutations

CTCAE, Common Terminology Criteria for Adverse Events; NCT, National Clinical Trial; NSCLC, non–small cell lung cancer; 5-FU/LV, 5-fluorouracil/leucovorin.

experimental arms of MEK inhibitors combined with BRAF inhibitors, EGFR inhibitors, or estrogen antagonists (vs BRAF inhibitors, EGFR inhibitors, or estrogen antagonist monotherapy with or without placebo) were associated with a 6.7% increased risk in 8 RCTs (RR, 2.24; 95% CI, 0.79-6.41; *P* > .05) (Figure 2).

In a random-effects model meta-analysis, MEK inhibitors with or without other targeted inhibitors or chemotherapy (vs targeted therapy or chemotherapy without MEK inhibitors) was significantly associated with a nearly 7.4% increased risk of grade 1/2 ocular toxicities (RR, 2.97; 95% CI, 1.26-7.01; *P* < .05) (Figure 3). As for

chemotherapy subgroups, the pooled results showed that MEK inhibitor monotherapy or MEK inhibitors plus chemotherapy (vs chemotherapy with or without placebo) increased the risk of the grade 1/2 ocular toxicities by approximately 8.5% (RR, 3.78; 95% CI, 1.01-14.10; *P* < .05) (Figure 3). In the targeted therapy group, therapy

	Intervention	Comparator	Intervention group sample, No.	Control group sample, No.	CTCAE criterion
	Encorafenib + binimetinib + cetuximab	Encorafenib + cetuximab	222	216	4.03
	Trametinib	5-FU/LV or capecitabine	23	20	4.0
	Selumetinib + dacarbazine	Dacarbazine + placebo	97	32	4.0
	Encorafenib + binimetinib	Encorafenib	192	192	4.03
	Gemcitabine + pimasertib	Gemcitabine + placebo	45	42	4.0
	Cobimetinib + vemurafenib	Placebo + vemurafenib	247	246	4.0
	Cobimetinib + vemurafenib	Placebo + vemurafenib	247	246	4.0
	Erlotinib + selumetinib	Erlotinib	49	19	4.0
	Fulvestrant + selumetinib	Fulvestrant + placebo	23	22	4.0
	Dabrafenib + trametinib	Vemurafenib	350	349	4.0
	Selumetinib	Temozolomide or dacarbazine	49	50	4.0
	Dabrafenib + trametinib	Dabrafenib + placebo	209	211	4.0
	Docetaxel + selumetinib	Docetaxel + placebo	38	41	4.03
	Gemcitabine + trametinib	Gemcitabine + placebo	80	80	4.0
	Selumetinib + dacarbazine	Dacarbazine + placebo	44	45	3.0
	Trametinib	Dacarbazine or paclitaxel	211	99	4.0
	Dabrafenib + trametinib	Dabrafenib	109	53	4.0

with MEK inhibitors tended to increase the occurrence of grade 1/2 ocular AEs, but this increase was not significant (RR, 2.54; 95% CI, 0.74-8.68;  $P > .05$ ) (Figure 3).

The results for grade 3/4 ocular toxicities were similar when pooling in the targeted therapy subgroup (RR,

7.23; 95% CI, 1.04-50.28;  $P < .05$ ) (Supplement S1). However, the risk-of-chemotherapy subgroup was presented in 1 article and thus could not be pooled effectively.

**Secondary end points**

Data on blurred vision were extracted

from 8 studies. The experimental group of MEK inhibitors was harmful in these studies (RR, 4.10; 95% CI, 2.55-6.58;  $P < .05$ ) and the same in the chemotherapy group (RR, 4.98; 95% CI, 1.36-18.17;  $P < .05$ ) and the targeted therapy group (RR, 3.95; 95% CI, 2.38-6.55;  $P < .05$ ) (Figure 4). The risk of grade

FIGURE 4. Blurred Vision Total Adverse Effect and Subgroup Analysis

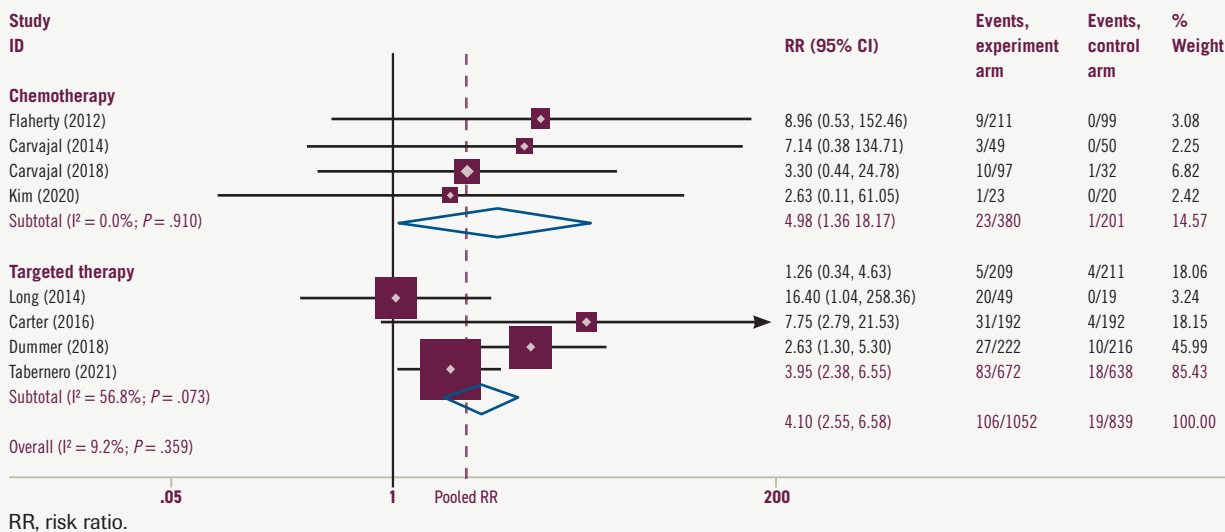
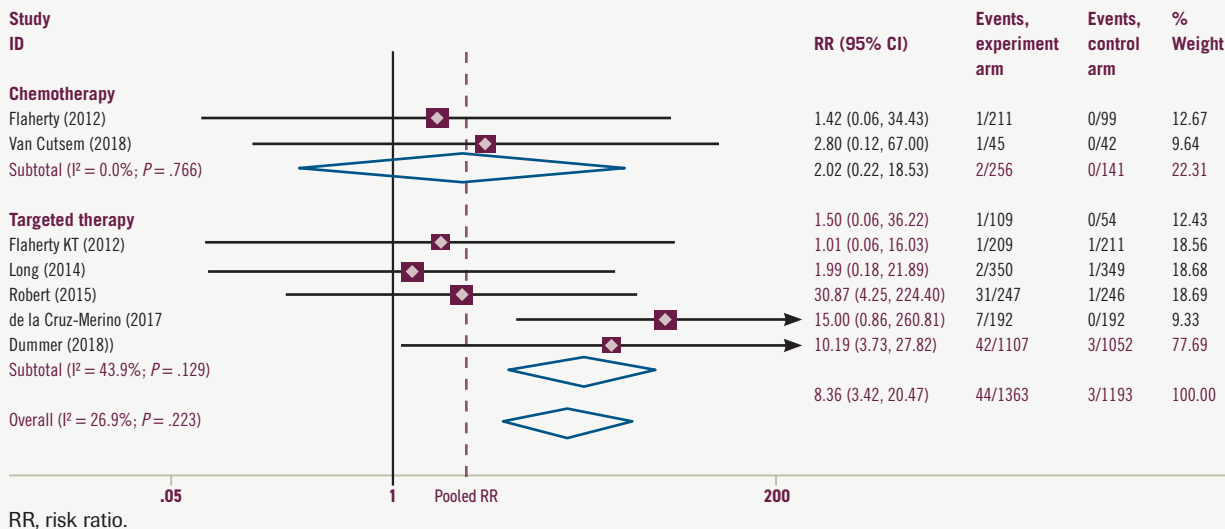


FIGURE 5. Chorioretinopathy Total Adverse Effect and Subgroup Analysis



1/2 AEs was 8.9% higher in the MEK inhibitors experimental group and was 9.6% and 7.3% higher (Supplement S2) in targeted therapy and chemotherapy groups, respectively. No risk of grade 3/4 blurred vision was reported in the included studies.

Data on chorioretinopathy was

available in 7 studies. MEK inhibitors combined with BRAF inhibitors significantly increased the risk by 3.5% (95% CI, 3.73%-27.82%;  $P < .05$ ) vs BRAFinhibitor monotherapy (Figure 5). The results for grade 1/2 chorioretinopathy were similar, and MEK plus BRAF inhibitors tended to increase risk

(RR, 3.14; 95% CI, 0.83%-13.92%;  $P > .05$ ), but not significantly (Supplement S3). The risk of grade 3/4 chorioretinopathy was present in 2 articles in the targeted group, an increasing risk tendency but not significant (Supplement S4). In the chemotherapy group, MEK inhibitors with

or without chemotherapy (vs chemotherapy alone) did not significantly increase the risk of chorioretinopathy.

Data for retinal detachment were extracted from 3 studies: 2 compared MEK inhibitors plus BRAF inhibitors vs BRAF inhibitors alone, and 1 compared pimasertib plus gemcitabine vs gemcitabine plus placebo. The pooled meta-analysis of these 3 studies showed that the MEK inhibitors group increased the retinal detachment risk by 10.1% (RR, 8.98; 95% CI, 3.92-20.57;  $P < .05$ ) (Supplement S5) compared with the no MEK inhibitors group.

### Sensitivity analysis and risk of bias

To further explore the potential heterogeneity from any single study, sensitivity analysis was performed and showed that the present results were significantly affected by removing 1 study, and the pooled analysis showed increasing ocular toxicities risk in the MEK inhibitors group (Supplement S6). We summarize the risk of bias assessments for the primary outcome of this review in Supplements S7 and S8. We ran a comprehensive search and considered the risk of having missed published reports to be low. The funnel plot of data from the 16 studies included in the meta-analysis was symmetrical (Supplement S9). The  $P$  value for the Egger test was .199; there was no publication bias in the meta-analysis (Supplement S10).

### Discussion

#### Clinical manifestations of the MEK-associated ocular adverse effect

During the past decade, newer targeted agents have been developed to exploit tumor-specific genetic alterations in signal transduction pathways, which have taken anticancer therapy into a new era. MEK inhibitors, a crucial part to break the MAPK pathway and a great

partner for BRAF inhibitors, especially trametinib, have been developed and approved for use in combination with dabrafenib for early melanoma, specifically for unresectable or metastatic solid tumors with *BRAF* V600E mutations.<sup>25</sup> As the indications expand, the clinical safety of MEK inhibitors should be carefully examined.

Ever since the first MEK inhibitor, CI-1040, was clinically evaluated, ocular toxicities have been regularly reported for this class of drugs.<sup>26</sup> Common ocular toxicities included blurred vision and visual disturbances, and these tended to arise quickly after dosing in the first studies with the MEK inhibitors CI-1040, PD0325901, and selumetinib.<sup>27,28</sup> Thus, researchers of the phase 1 trials of trametinib suspected these toxicities to be related to the peak concentration. However, because these toxicities are very similar to those reported in newly developing MEK inhibitors, there seems to be a class effect.

In general, most patients with ocular toxicities identified various clinical manifestations, including reduced visual acuity, blurred vision, dyschromatopsia, chorioretinopathy, retinal detachment, and photophobia.<sup>17,29</sup> Herein, blurred vision, chorioretinopathy, and retinal detachment were pooled according to the included studies as secondary outcomes, for they were commonly described as such in the clinical trials. In fact, other types of ocular toxicities, such as cataracts, photosensitivity reactions, macular edemas, and macular fibroses, were also mentioned in 1 clinical trial, but they could not be pooled effectively. In contrast, the secondary end points we chose in this systematic review are consistent with the United States Common Terminology Criteria for Adverse Events evaluation standard (Table 2). Blurred vision represents

a disorder characterized by visual perception of unclear or fuzzy images. Chorioretinopathy describes a disorder involving the choroid and retina. Retinal detachment was characterized by the separation of the inner retina layers from the underlying pigment epithelium. Of note, although these 3 toxicities have been classified as grades 1 to 5, most patients experienced grade 1/2 toxicities more often, according to the present results. What's more, MEK inhibitor-related retinopathy usually begins acutely within 1 week of taking the first dose. Clinical examination in patients with mild disease usually shows multifocal and bilateral small subretinal detachments, possibly with subretinal fluid accumulation. Moderate cases may have only multiple subretinal detachments. More severe cases may develop intraretinal fluid or cysts, as well as disorders of the outer retina. Clinical presentation is usually bilateral, although there are exceptions, and usually symmetrical. Symptoms vary widely; many patients are asymptomatic.

Retinal vein occlusion (RVO) is an uncommon but potentially serious AE reported in initial clinical trials of several MEK inhibitors, including cobimetinib and trametinib. Across all clinical trials, trametinib resulted in an RVO rate of 0.2%.<sup>30,31</sup> Predisposing factors included glaucoma, uncontrolled high blood pressure, and diabetes. In at least 1 patient, switching from continuous to intermittent dosing reduced the incidence of RVO.<sup>32</sup> At least 1 study has shown that MEK inhibitor-related RVO is associated with hyperhomocysteinemia, an inherited metabolic disease that predisposes to venous thromboembolism. These sparse data suggest that screening for hyperhomocysteinemia before initiation of MEK inhibitor therapy may be beneficial, but more data are needed.<sup>33</sup>



## PERSPECTIVE BY

David L. DeRemer, PharmD, BCOP,<sup>1,2</sup>; and Bently P. Doonan, MD, MS<sup>2,3</sup>

## Evaluating Treatment Options and the Multidisciplinary Care of Ocular Toxicities of MEK Inhibitors

Ocular toxicities associated with conventional cytotoxic chemotherapy and novel targeted therapies utilized in cancer care continue to evolve.

The authors of “Ocular Toxicities of MEK Inhibitors in Patients With Cancer: A Systemic Review and Meta-Analysis” provide a comprehensive analysis of 17 randomized clinical trials. Because the RAS-MAPK activation pathway is a common mutation in multiple malignancies, MEK inhibitor use continues to expand in treatment recommendations. Recent advancements include the BRAF/MEK inhibitor combination of dabrafenib (Tafinlar) plus trametinib (Mekinist) receiving FDA approval for a tissue-agnostic indication in solid tumors harboring a *BRAF* V600E mutation.<sup>1</sup> Other examples of expanding use of MEK inhibitors beyond *BRAF* V600E mutations include binimetinib (Mektovi) for *NRAS*-mutated melanoma and neurofibromatosis type 1-associated tumors, particularly progressive low-grade gliomas and plexiform neurofibromas.<sup>2,3</sup>

With this increasing clinical presence, clinicians need to be cognizant of these unique risks of therapy and appropriate monitoring strategies to mitigate toxicities.

Results from this meta-analysis report an increased risk of ocular adverse effects (AEs), specifically blurred vision, chorioretinopathy, and retinal detachment when MEK inhibitors are combined with additional targeted or traditional chemotherapy. Most of these ocular AEs are National Cancer Institute Common Terminology Criteria for Adverse Events grade 1 or 2 in severity. Grading of ocular AEs—given the diversity of toxicities—can be challenging; notably, improvements have been made in the classification of retinal vascular disorders, MEK

inhibitor-associated retinopathy, and blurred vision with Common Terminology Criteria for Adverse Events version 5.0.

Many patients are asymptomatic or present with mild symptoms depending on the ocular AEs, which can create challenges for clinicians in early clinical intervention. In the setting of suspected MEK inhibitor-associated retinopathy, MEK inhibitors can cause transient, dose, and time-dependent retinopathy. Elimination half-lives of MEK inhibitors vary (approximately 3.5 hours for binimetinib, 44 hours for cobimetinib [Cotellic], and 4.8 days for trametinib), so the timing of ocular AEs may differ. Interestingly, some patients experience these events immediately following the initiation of therapy, and the duration of therapy does not influence the development of ocular sequelae.<sup>4</sup> Adherence to product recommendations for dose reductions or discontinuations (temporary/permanent) based on toxicity is advised.

In many cases, MEK inhibitors can be safely resumed following the resolution of symptoms at a reduced dose without provoking repeat ocular AEs. These descriptive findings on ocular toxicity imply that there is a threshold for provocation in a dose-dependent manner and that alternative dosing strategies may be beneficial in patients with high baseline risks of ocular complications. The traditional paradigm in clinical trial design and drug development is to utilize anticancer drugs at maximum tolerated doses, so rarely do phase 3 trials incorporate multiple dosing strategies when seeking new indications of use.

However, there appears to be renewed interest in shifting to seeking minimum effective doses, particularly

### Differentiating metastasis from drug toxicity

MEK inhibitors as a class of anticancer agents are commonly used in melanoma, NSCLC, and other solid tumor

treatments. However, clinicians should distinguish visual disturbances caused by other medical etiologies (such as diabetic complications, hypertension complications, or concomitant medication)

from ocular toxicities caused by MEK inhibitors. If the patient has a history of diabetes, hypertension, other diseases, or a special medication history, an ophthalmologic evaluation should be

in targeted therapies.<sup>5</sup> A recent example of this strategy is with sotorasib (Lumakras), which received FDA accelerated approval for *KRAS* G12C non-small cell lung cancer.<sup>6</sup> The FDA issued a postmarketing requirement to evaluate 960 mg vs 240 mg daily dosing to assess objective response rates with less toxicity (CodeBreak201; NCT04933695). Because *KRAS* and MEK share the common pathway target of MAPK, further clinical investigation and use of MEK inhibitors would benefit from learning this lesson and exploring optimized dosing strategies to minimize common toxicities like those outlined in this manuscript.

In 2006, van Heeckeren et al wrote a brilliantly titled editorial, “Promise of New Vascular-Disrupting Agents Balanced With Cardiac Toxicity: Is It Time for Oncologists to Get to Know Their Cardiologists?” following the emergence of VEGF targeted therapies.<sup>7</sup> With the expanding use of MEK inhibitors and recent FDA approvals that include belantamab mafodotin-blmf (Blenrep), tisotumab vedotin-tftv (Tivdak), and mirvetuximab soravtansine-gynx (Elahere), we have reached the era where oncologists should “get to know” their ophthalmologists.

We would advocate for the development of collaborative practice partnerships due to the challenges of fragmented cancer care. With some novel agents requiring ophthalmic exams, including visual acuity and slit lamp exams at baseline and prior to each dose and the coordination of multiple eye drops (lubrication, corticosteroids, vasoconstrictor), these proposed partnerships to manage ocular AEs should be multidisciplinary. The establishment of integrated communication would foster improved coordination of patient care. For example, if a patient were to experience loss of vision or other visual disturbance while receiving a MEK inhibitor, it can be challenging to receive an ophthalmological evaluation within 24 hours as recommended. These proposed partnerships between oncology and ophthalmology could expedite consultations.

Clearly, all health care professionals need to be vigilant in their patient education sessions regarding the risk of ocular AEs and management strategies. ■

performed before antitumor treatment. The exact etiology can be quickly distinguished when eye symptoms worsen. Of note, apart from these etiologies,

tumor eye metastasis may be uncommon but can still happen in clinical practice and should be noted in patients with cancer. Oncologists and ophthalmolo-

gists should learn about the common intraocular metastatic lesions, often involving the uvea, which consists of the iris and ciliary body anteriorly

**DISCLOSURES:** DeRemer has nothing to disclose; Doonan receives research funding from Curis, Inc.

**AFFILIATIONS:** <sup>1</sup>Department of Pharmacotherapy and Translational Research and Center for Pharmacogenomics and Precision Medicine, College of Pharmacy, University of Florida, Gainesville  
<sup>2</sup>University of Florida Health Cancer Center, Gainesville  
<sup>3</sup>Division of Hematology and Oncology, Department of Medicine, University of Florida, Gainesville; University of Florida Health Cancer Center, Gainesville

**CORRESPONDING AUTHOR(S):**

David L. DeRemer, PharmD, BCOP, FCCP, FHOPA  
Clinical Professor  
Assistant Director, Experimental Therapeutics Group  
University of Florida College of Pharmacy  
University of Florida Health Cancer Center  
Office: 352-294-8891  
Email: dderemer@cop.ufl.edu  
ORCID: 0000-0002-2207-9552

Bently P. Doonan, MD, MS  
Assistant Professor  
University of Florida College of Medicine  
Division of Hematology and Oncology  
University of Florida Health Cancer Center  
Email: Bently.Doonan@medicine.ufl.edu  
ORCID: 0000-0001-5401-2910

**References**

1. FDA grants accelerated approval to dabrafenib in combination with trametinib for unresectable or metastatic solid tumors with BRAF V600E mutation. FDA. June 23, 2022. Accessed February 9, 2023. <https://bit.ly/3HYXkhe>
2. Dummer R, Schadendorf D, Ascierto PA, et al. Binimetinib versus dacarbazine in patients with advanced NRAS-mutant melanoma (NEMO): a multicentre, open-label, randomised, phase 3 trial. *Lancet Oncol*. 2017;18(4):435-445. doi:10.1016/S1470-2045(17)30180-8
3. Klesse LJ, Jordan JT, Radtke HB, et al. The use of MEK inhibitors in neurofibromatosis type 1-associated tumors and management of toxicities. *Oncologist*. 2020;25(7):e1109-e1116. doi:10.1634/theoncologist.2020-0069
4. Arora S, Surakiatchanukul T, Arora T, et al. Retinal toxicities of systemic anticancer drugs. *Surv Ophthalmol*. 2022;67(1):97-148. doi:10.1016/j.survophthal.2021.05.007
5. Piccart MJ, Hilbers FS, Bliss JM, et al. Road map to safe and well-designed de-escalation trials of systemic adjuvant therapy for solid tumors. *J Clin Oncol*. 2020;38(34):4120-4129. doi:10.1200/JCO.20.01382
6. FDA grants accelerated approval to sotorasib for *KRAS* G12C-mutated NSCLC. FDA. May 28, 2021. Accessed February 13, 2023. <https://bit.ly/3YEj1Kk>
7. van Heeckeren WJ, Bhakta S, Ortiz J et al. Promise of new vascular-disrupting agents balanced with cardiac toxicity: is it time for oncologists to get to know their cardiologists? *J Clin Oncol*. 2006;24(10):1485-1488. doi:10.1200/JCO.2005.04.8801

TABLE 2. CTCAE Grading for Eye Disorders

CTCAE term	Grade 1	Grade 2	Grade 3	Grade 4	Grade 5
Blurred vision	Intervention not indicated	Symptomatic; moderate decrease in visual acuity (best-corrected visual acuity 20/40 and better or ≤ 3 lines of decreased vision from known baseline); limiting instrumental ADLs	Symptomatic with marked decrease in visual acuity (best-corrected visual acuity worse than 20/40 or >3 lines of decreased vision from known baseline, up to 20/200); limiting self-care ADLs	Best-corrected visual acuity of 20/200 or worse in the affected eye	—
Retinopathy	Asymptomatic; clinical or diagnostic observations only	Symptomatic; moderate decrease in visual acuity (best-corrected visual acuity 20/40 and better or ≤ 3 lines of decreased vision from known baseline); limiting instrumental ADLs	Symptomatic with marked decrease in visual acuity (best-corrected visual acuity worse than 20/40 or >3 lines of decreased vision from known baseline, up to 20/200); limiting self-care ADLs	Best-corrected visual acuity of 20/200 or worse in the affected eye	—
Retinal detachment	—	—	Macular-sparing rhegmatogenous detachment	Macula-off rhegmatogenous retinal detachment	—

ADL, activity of daily living; CTCAE, Common Terminology Criteria for Adverse Events (version 5.0; November 27, 2017).

A single dash (—) indicates a grade is not available.

and the choroid posteriorly. Choroidal metastases typically present as raised amelanotic choroidopathy with patchy pigmentation of the RPE. They are often accompanied by an upper serous retinal detachment disproportionate to the lesion itself. Symptoms depend on the location of the metastases: peripheral metastases containing a small amount of serous fluid may be asymptomatic, whereas macular involvement or subretinal fluid can cause flash hallucinations (subjective perception of flashes, sparks, or color), visual distortion, floaters, blurred vision, difficulty focusing, and dyschromia (an abnormal ability to perceive colors). Although some of these symptoms may mimic drug toxicity, mydriatic fundus examination (often combined with ocular ultrasonography and optical coherence tomography) can often differentiate choroidal metastases from drug-induced retinopathy.<sup>34,35</sup> Orbital or optic nerve metastases can cause optic disc edema, which can be secondary to papilledema due to brain metastases.

In such cases, cross-sectional imaging of the head can assist in the diagnosis.<sup>36</sup> Retinal metastases can cause retinal inflammation and intraretinal hemorrhage, and vitreous metastases cause the accumulation of white blood cells in the vitreous, which may manifest as vitritis (inflammation of the vitreous body). Mydriatic fundus examination and vitreous biopsy can help differentiate true vitritis from vitreous metastases.<sup>37</sup>

**Management of ocular AEs associated with MEK inhibitors**

The US package inserts for trametinib and cobimetinib recommend that patients receive regular eye examinations during treatment and whenever new or worsening visual disturbances occur. Because most ocular toxicities are mild or moderate (and almost always reversible), patients and oncologists should pay attention to these AEs, but more comprehensive ophthalmology evaluations should be received at the onset of clinical symptoms. If retinal

detachment has been diagnosed, trametinib should be withheld; it should be restarted at the same or a lower dose only if the retinal detachment resolves within 3 weeks. Clinicians should discontinue the drug, or restart at a lower dose, if there is no improvement after 3 weeks, if the disease recurs, or if RVO occurs. For serous retinopathy caused by cobimetinib, treatment should be interrupted until visual symptoms improve. Treatment can be resumed at a lower dose only if symptoms improve within 4 weeks. Clinicians should permanently discontinue treatment if symptoms recur or RVO occurs. In a similar vein, if serous retinopathy is caused by binimetinib, treatment should be withheld and then resumed at a lower dose if symptoms improve within 10 days. Otherwise, permanently discontinue if no improvement or RVO occurs. Moreover, selumetinib was the same (Table 3). Currently, there are no validated treatment options available for retinal detachment and RVO. The fluid accumulation is usually reabsorbed

**TABLE 3. Management of Ocular Adverse Events Recommended During Treatment With MEK Inhibitors**

MEK inhibitor	Eye examination frequency	Management
Trametinib	Periodically, at any time new or worsening visual disturbances occur	Retinal detachment: Withhold trametinib for up to 3 wk. <ul style="list-style-type: none"> <li>▪ If improved, resume trametinib at same or lower dose.</li> <li>▪ If not improved, permanently discontinue trametinib or resume trametinib at lower dose.</li> </ul> RVO: Permanently discontinue trametinib.
Cobimetinib	Periodically, at any time new or worsening visual disturbances occur	Serous retinopathy: Withhold cobimetinib for up to 4 wk. <ul style="list-style-type: none"> <li>▪ If signs and symptoms improve, resume at the next lower dose level.</li> <li>▪ If not improved or symptoms recur at the lower dose within 4 wk, permanently discontinue.</li> </ul> RVO: Permanently discontinue cobimetinib.
Binimetinib	Periodically, at any time new or worsening visual disturbances occur	Serous retinopathy: Withhold binimetinib for up to 10 d. <ul style="list-style-type: none"> <li>▪ If improved and becomes asymptomatic, resume at same dose.</li> <li>▪ If not improved, resume at a lower dose level or permanently discontinue binimetinib.</li> </ul> RVO: Permanently discontinue binimetinib.
Selumetinib	Periodically, at any time new or worsening visual disturbances occur	Retinal detachment: Withhold until resolution. Resume at reduced dose. RVO: Permanently discontinue selumetinib.

d, days; RVO, retinal vein occlusion; wk, weeks.

in retinal detachment, with symptoms resolving and no need for treatment. RVO is a more serious AE requiring therapeutic intervention. Drug discontinuation should inform consent from patients first, for they have the right to decide. They may maintain eyesight or suffer blindness under the following MEK inhibitor treatment, drug discontinuation should be carefully evaluated for metastatic patients. A range of treatments,

including vascular endothelial growth factor receptor inhibitors, anticoagulants, corticosteroids, and thrombolytic agents, have attempted to solve this problem but have no validated evidence to date.<sup>38,39</sup> The lack of available treatment options requires oncologists, ophthalmologists, and patients to mind this problem, and favors ophthalmologic examinations before and after the start of MEK inhibitor treatment to achieve quick diagnoses and close monitoring.

**Conclusion**

MEK inhibitors are novel targeted anticancer agents of the MAPK pathway and have been approved to treat melanoma, NSCLC, and various *BRAF* V600-mutant solid tumors. However, they seem to cause common and unique ocular toxicities. Treatment with MEK inhibitors combined with targeted drugs or chemotherapy (vs targeted therapy or chemotherapy without MEK inhibitors) seems to increase overall ocular AEs, especially blurred vision, chorioretinopathy, and retinal detachment. To overcome this limitation, oncologists and ophthalmologists need to enhance communication to safeguard patient health during MEK inhibitor therapy. ■

**FUNDING:** This work was supported by a grant from the Leading Talent Cultivation Project of Henan Health Science and Technology Innovation Talents (No. YXKC2020009), Henan International Joint Laboratory of Drug Resistance and Reversal of Targeted Therapy for Lung Cancer (No. [2021]10), Henan Medical Key Laboratory of Refractory Lung Cancer (No. [2020]27), and Henan Refractory Lung Cancer Drug Treatment Engineering Technology Research Center (No. [2020]4). The funders had no role in the study design, data collection/analysis, decision to publish, or preparation of the manuscript.

**AFFILIATIONS:**<sup>1</sup>Department of Internal Medicine, The Affiliated Cancer Hospital of Zhengzhou University and Henan Cancer Hospital, Zhengzhou, China  
<sup>2</sup>State Key Laboratory of Ophthalmology, Zhongshan Ophthalmic Center, Sun Yat-sen University, Guangzhou, China

**CORRESPONDING AUTHOR:** Qiming Wang, MD, PhD  
 Department of Internal Medicine  
 The Affiliated Cancer Hospital of Zhengzhou University  
 Henan Cancer Hospital  
 Zhengzhou, China  
 Email: qimingwang1006@126.com

 **For references and supplementary figures, visit**  
[cancerjournal.com/MEK\\_3.23](https://cancerjournal.com/MEK_3.23)