

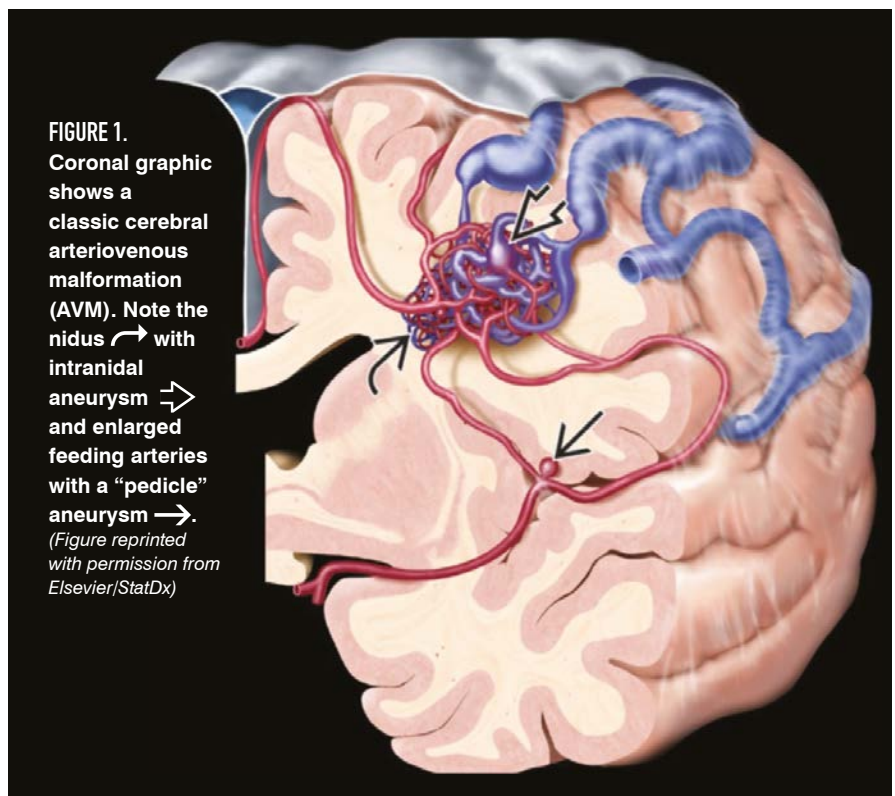
Demystifying AVMs

Risk assessment and management of brain arteriovenous malformations in pregnancy BY VIKTOR SZEDER, MD, PHD, MSC, FSVIN; AND DAVID KIMBALL, MD

Brain arteriovenous malformations (AVMs) are one of several vascular malformations that occur within the brain. Unlike most other such deformities, brain AVMs are particularly dangerous because their rupture can lead to intracranial hemorrhage. Patients who present with unruptured brain AVMs can have a variety of neurologic symptoms, including headaches, seizures, and stroke-like symptoms. A diagnosis of AVM poses many challenges for obstetricians and pregnant patients alike. In this article, we hope to demystify the disorder and guide clinicians through the management of these relatively uncommon lesions.

Pathology

Brain AVMs are connections between arteries and veins that lack



VIKTOR SZEDER, MD, PHD, MSC, FSVIN, is an associate clinical professor of radiology and neurosurgery and the director of the Fellowship Training Program in the Division of Interventional Neuroradiology at the David Geffen School of Medicine at UCLA in Los Angeles, California.

DAVID KIMBALL, MD, is an interventional neuroradiology fellow in the Division of Interventional Neuroradiology at the David Geffen School of Medicine at UCLA in Los Angeles, California.

an intervening capillary network. They shunt blood directly from the high-pressure arterial system to low-pressure veins, which are not designed to withstand such a high and forceful flow. In general, an AVM contains a central nidus that appears as a tangle of serpiginous blood vessels, usually in the center of the lesion (**Figure 1**). Importantly, there is no normal intervening brain tissue within the AVM nidus (**Figures 2A, 2B, and 3**).

In addition, AVMs can possess other characteristics that put them at an increased risk for hemorrhage, including intranidal or perinidal aneurysms. These aneurysms can be prone to rupture and lack an intervening nidus. In addition, venous outflow restrictions or venous dilatations can place particular strain on otherwise normal, relatively thin veins, which also put AVMs at a higher risk of rupture.

Etiology and epidemiology

The pathogenesis and pathology of brain AVMs are poorly understood. A debate exists as to whether they are congenital or acquired. They have historically been classified as congenital, although there is an increasing number of reports of de novo cases, which add weight to the notion that these are dynamic lesions that can form postnatally.^{1,2}

Brain AVMs are relatively uncommon, occurring in approximately 0.1% of the population, which is one-tenth the incidence of brain aneurysms.³ Initial presenting symptoms can range from new onset of headaches or any number of other focal neurologic signs. The prevalence of general headache in pregnant women has been described to be as high as 35% and is extremely nonspecific.⁴ A nonsevere headache

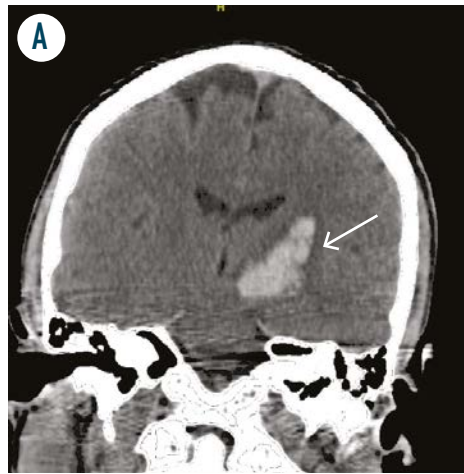


FIGURE 2A. Coronal CT head shows an acute intraparenchymal bleed in the left basal ganglia →. (Figure author provided)

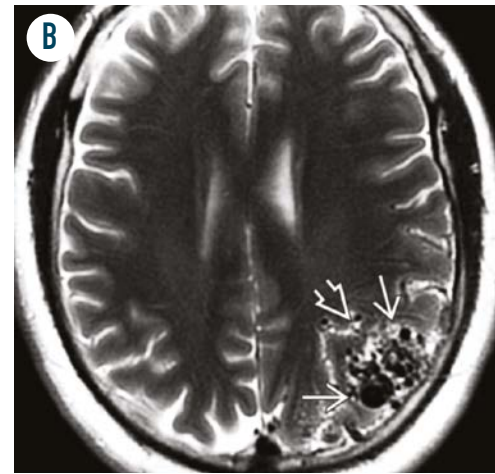


FIGURE 2B. Axial T2WI MR in the same patient shows a triangular wedge-shaped collection of flow voids →. The broad base of the wedge is at the cortical surface, whereas the apex of the triangle ⇨ extends into the deep sulci and subcortical white matter, pointing towards the lateral ventricle. (Figure reprinted with permission from Elsevier/StatDx)

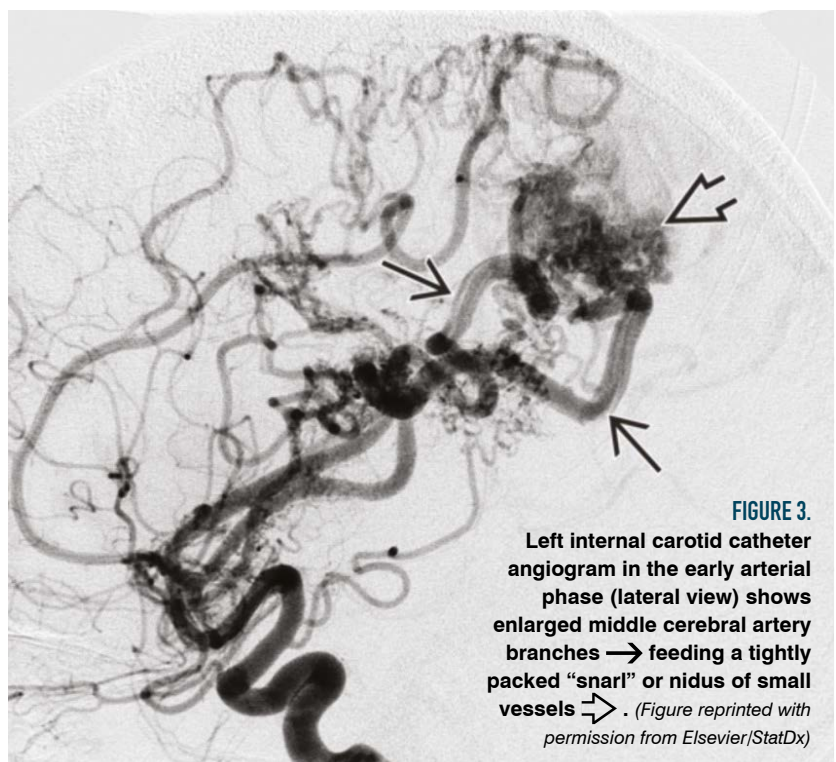


FIGURE 3. Left internal carotid catheter angiogram in the early arterial phase (lateral view) shows enlarged middle cerebral artery branches → feeding a tightly packed "snarl" or nidus of small vessels ⇨. (Figure reprinted with permission from Elsevier/StatDx)

without an abrupt onset (eg, a headache that is not “thunderclap”) is generally not worrisome. However, any new onset headache, particularly those that present with transient neurological symptoms during pregnancy, do require appropriate management and workup to rule out serious intracranial pathology.

Grading

Several classification schemes have been proposed for the grading of brain AVMs, but the most widely used is Spetzler-Martin,⁵ which assigns points in 3 categories: AVM size, location (in eloquent cortex such as the motor strip), and venous outflow anatomy (**Table**). Grades range from 1 (most “benign”) to 5 (most “aggressive”). The scale was initially developed as a tool to predict outcomes after surgical resection: a Spetzler-Martin grade 1 AVM could be easily resected, and a grade 5 AVM was considered inoperable. However, the grading scheme has been extrapolated upon and has been applied to other treatment modalities, such as radio or endovascular therapy.

Risk of rupture in pregnancy

The most feared complication of a brain AVM is rupture leading to intracranial hemorrhage. The mortality rate after intracranial hemorrhage from AVM rupture in all patients ranges from 12% to 67%, and 23% to 40% of survivors subsequently experience significant disability.^{6,7} In pregnant women, cerebral AVM bleeding has been associated with a 28% rate of maternal mortality, a 14% rate of fetal mortality, and with miscarriage in early pregnancy (presumably from the poor maternal prognosis, which generally requires

TABLE. Spetzler-Martin Grading

Size (cm)	Points
< 3	1
3-6	2
> 6	3
Venous drainage	
Superficial	0
Deep	1
Eloquence	
No	0
Yes	1
Total	5

(Table author provided)

an extended stay in an intensive care unit).^{8,9} It has been reported that most cerebral AVM hemorrhages occur between 20 weeks of gestation and 6 weeks postpartum,⁹ which coincides with maternal hemodynamic changes.

Dramatic physiologic changes occur in pregnancy. Plasma volume increases by 40% to 50% and red blood cell volume by 20% to 30%. There is also increased cardiac output, body weight, and rate of thrombosis. It may be reasonable to conclude that the risk of AVM rupture during pregnancy increases owing to these changes. However, there is no agreement in the literature about the risk of AVM rupture during pregnancy, with several studies suggesting that there is no connection between the two.

Liu et al showed no increased risk of hemorrhage in patients with cerebral AVM during pregnancy and puerperium.¹⁰ Horton et al showed that pregnant patients with brain AVM face a 3.5% risk of hemorrhage

during pregnancy, which is not an increase compared to nonpregnant patients.¹¹ Other studies cite a slightly increased risk of hemorrhage during pregnancy.^{12,13} For example, Porras et al demonstrated an annual hemorrhage rate of 1.3% in nonpregnant women versus 5.7% in pregnant women.¹² Similarly, a recent meta-analysis showed a 3.27 fold increase in the risk of intracranial hemorrhage during pregnancy and puerperium.¹³

Based on the data, we believe there may be a slightly increased risk of hemorrhage during the second and third trimesters and puerperium in patients harboring a brain AVM. However, the increased risk of hemorrhage is still quite low overall, approximately 5%.

Management

The management of a brain AVM can be challenging for the clinician and quite stressful for the patient and her family. There are four accepted management modalities: observation, surgical resection, endovascular treatment, and radiation therapy or a combination thereof (**Figure 4A and 4B**). However, one of the first management questions that must be answered is whether the AVM has ruptured (**Figure 5**).

Ruptured AVM

A ruptured brain AVM entails significant morbidity and mortality for mother and fetus.⁸ Patients with previous AVM rupture are at higher risk of re-rupture in subsequent years. Therefore, symptomatic AVMs in pregnant women should be treated as they would be in patients who are not pregnant. The timing here varies, and waiting for up to a month or more is accepted for surgical resection in AVMs that have bled. The time allows for the resorption of some intracranial

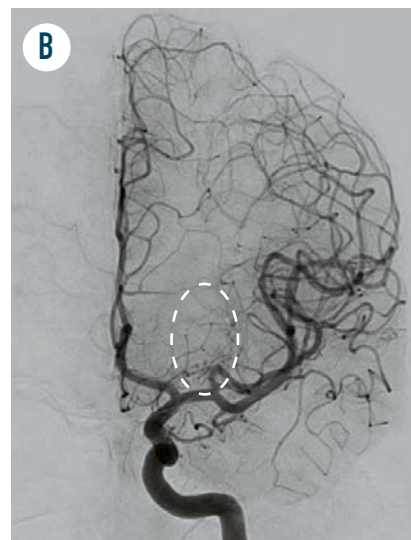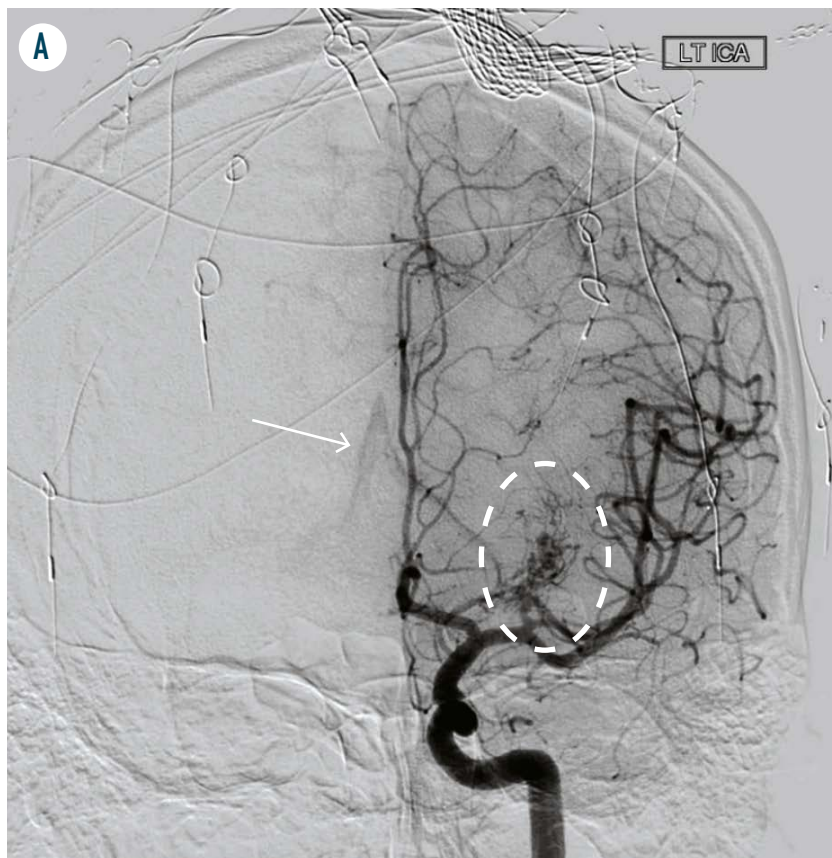


FIGURE 4A. Initial cerebral catheter angiogram shows a small left thalamic AVM (dashed oval). Notice the early draining vein (white arrow) in the center of the image—a characteristic AVM feature—an early drainage from the AVM nidus, which appears to cross midline. (Figure author provided)

FIGURE 4B. The patient was first treated with trans-arterial embolization and then with stereotactic radiosurgery. Follow-up angiogram at 3 years demonstrates no residual AVM (in the oval area marked by the dash) and no early draining vein (white arrow area in Figure 4A.) (Figure author provided)

blood products and reduces the edema in the associated brain parenchyma. For endovascular treatment or in the case of a clearly ruptured perinidal aneurysm, treatment may proceed immediately after the inciting event. In general, the decision about treatment time varies among centers, and the specific timing and treatment modality of a ruptured cerebral AVM in pregnancy should be made using a multidisciplinary approach to ensure the AVM’s hemodynamic stability and the mother’s safety.⁹

The type of bleeding from an AVM is also important. Most brain AVMs that rupture present with intraparenchymal hemorrhage. If there is only subarachnoid blood, it may be a sign of a ruptured perinidal or intranidal

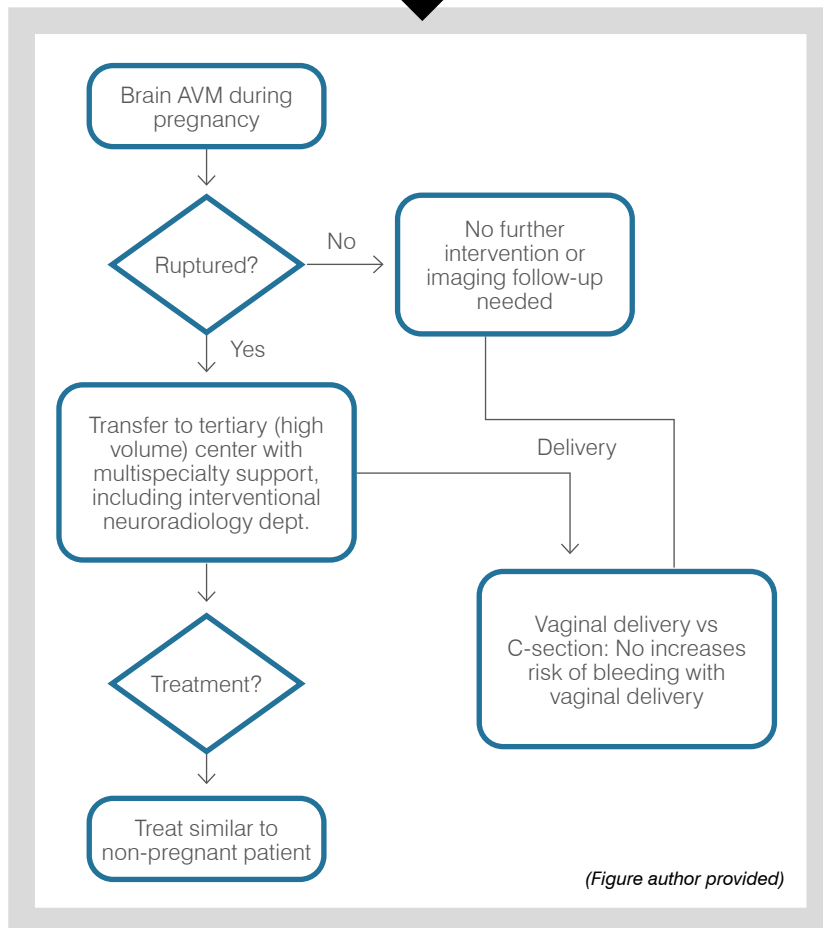
aneurysm, which should be treated and managed accordingly.

Catheter angiogram is the gold standard for characterizing and planning treatment of AVMs and their associated high-risk features. Catheter cerebral angiogram is thought to deliver approximately 0.17 to 2.8 mGy of radiation to the fetus, which is well below the accepted limit of 50 mGy.⁹ However, physicians generally take a “mother first” approach in cases of a ruptured brain AVM during pregnancy. Because of increased mother/fetus morbidity and mortality in these cases, the use of radiation should be weighed against the risk of further hemorrhage and detriment to the mother’s well-being. We therefore recommend performing

a catheter angiogram of the ruptured AVM to fully characterize and explore it.

Planning for the treatment of an AVM should be made by a multidisciplinary team on a case-by-case basis. In the paper by Porras et al, 9 pregnant women with ruptured brain AVMs were treated in various ways: radiation, surgery, endovascular means, or a combination thereof.¹⁴ The treatment of a ruptured

FIGURE 5. RUPTURED VS UNRUPTURED AVM



AVM is complex and beyond the scope of this paper. However, these patients are likely best managed at centers where all treatment modalities are offered and treating services (eg, neurosurgery, radiation-oncology, and interventional neuroradiology) can discuss how to formulate a plan that best fits the patient.

Unruptured AVM

An unruptured AVM can be discovered in different ways. The patient may present with seizure or focal neurologic deficits, or she may have known about

it before becoming pregnant. It may also be discovered incidentally during brain imaging for headaches or other unrelated pathology.

As previously mentioned, diagnosis of a brain AVM can cause significant stress and worry for everyone involved, and its risk of rupture during pregnancy is yet to be determined. Although it probably increases during pregnancy, it is still very small.

Most physicians agree that unruptured AVMs without high-risk features (eg, venous ectasia/stenosis or perinidal

aneurysm) should be managed conservatively and that no treatment (surgery, radiation, or endovascular treatment) is warranted in the pregnant patient.⁹ This is because the risk of treatment is greater than the risk of hemorrhage.¹⁵

A recent randomized controlled trial, the ARUBA trial, showed that medical management alone is superior to interventional therapy at preventing death or stroke in patients with unruptured brain AVMs who were followed for 33 months (no pregnant patients were included).¹⁵ However, the trial has received fierce criticism for considerable selection bias, poor generalizability, questionable clinical practices (only 15.8% of patients underwent surgical resection, the gold-standard treatment), and short follow-up (33 months) in light of the lifelong risk posed by the disease.¹⁶ Several extended trials are ongoing to further characterize the best treatment modalities in unruptured brain AVMs.

No clear guidelines exist about the management of the high-risk components (perinidal aneurysm, arteriovenous fistula, and venous outflow restriction) of an AVM during pregnancy. In these situations, a multidisciplinary approach should be taken, and the risks and benefits of treatment weighed on an individual basis.¹⁷ In our opinion, a conservative treatment approach should be taken in most cases of an incidentally discovered lesion, unless its high-risk features are considered relatively safe to treat.

Seizure prevention/management

Many patients with brain AVMs can have an increased risk of seizures, particularly if the AVM involves the temporal lobe. Seizure prevention and management is therefore particularly

Although the risk of hemorrhage in pregnant patients with brain AVMs increases slightly during the second and third trimesters and the puerperium, it remains quite low.

important in these patients. However, prescribing antiepileptic drugs in pregnancy can be extremely challenging for the clinician. Many of these medications have well-known teratogenic effects, and these effects must be conveyed to the mother.¹⁶ We would emphasize the need for referral to a neurologist and a high-risk obstetrician before prescribing or continuing the patient's antiepileptics.¹⁸

Imaging during pregnancy

We do not recommend screening otherwise asymptomatic patients for brain AVMs. Because observation is the most prudent management option of an unruptured AVM, screening pregnant patients leads to increased stress and anxiety for them. This recommendation extends even to those with a known diagnosis of hereditary hemorrhagic telangiectasia, an autosomal dominant condition that tends to occur in the lungs, brain, and liver. If brain imaging is required during pregnancy, we recommend first performing a brain MRI, which does not deliver any ionizing radiation to the patient or fetus. If vessel imaging is required, we recommend a brain MRA without contrast, or Time-of-flight MRA, as a first-line modality. Gadolinium-based contrast (MRI) is currently contraindicated in pregnant patients. Based on the clinical picture and the opinion of the neurointerventionalist or neuroradiologist, a CTA or cerebral angiogram may be recommended as the next step. Although these exams use ionizing radiation,

when performed on areas of the body other than the abdomen and pelvis, they deliver minimal radiation to the fetus.¹⁹ The absolute risks of fetal effects, including childhood cancer induction, are small at conceptus doses of 100 mGy and negligible at less than 50 mGy.¹⁹ It has been reported that fetal exposure after angiography and embolization of a brain AVM is somewhere between 0.17 mGy and 2.8 mGy—far below the safety threshold.⁹

Cesarean section vs vaginal parturition

Hemorrhage from a brain AVM during delivery is a major concern of obstetricians and patients alike. Available data would suggest that in most cases vaginal delivery does not carry a higher risk for hemorrhage than Cesarean section.^{11, 20-24} However, no data exists as to whether Cesarean section reduces the already low incidence of AVM-associated complications during childbirth. Thus, it is up to the clinician and patient to choose the best delivery method; an unruptured brain AVM should be considered but must be weighed against the rest of the clinical context and the patient's wishes.

Aspirin use

Low-dose aspirin has been used during pregnancy, most commonly to prevent or delay the onset of preeclampsia. The Hypertension in Pregnancy Task Force Report from the American College of Obstetricians and Gynecologists recommends daily low-dose aspirin

beginning in the late first trimester for women with a history of early-onset preeclampsia and preterm delivery at less than 34 0/7 weeks of gestation and for women with more than one prior pregnancy complicated by preeclampsia.

No clear, evidence-based recommendations or studies exist about the risk of brain AVM rupture in patients taking aspirin. However, based on the known safety of aspirin use in intracranial aneurysms, we would not recommend stopping aspirin or changing the antiplatelet regimen based solely on the presence of a brain AVM.

Conclusion

Although the risk of hemorrhage in pregnant patients with brain AVMs increases slightly during the second and third trimesters and the puerperium, it remains quite low. Therefore, we recommend observation of patients who present with an unruptured AVM. Ruptured brain AVMs in these patients should be treated like those in nonpregnant patients. Pregnant patients with brain AVMs, ruptured and unruptured, are best managed at centers where all complex treatments are offered and where neurosurgery, radiation-oncology, and interventional neuroradiology can together decide how best to develop treatment plans for individual patients. ■

FOR REFERENCES VISIT
contemporaryobgyn.net/AVMs