

Radiofrequency ablation for uterine fibroids

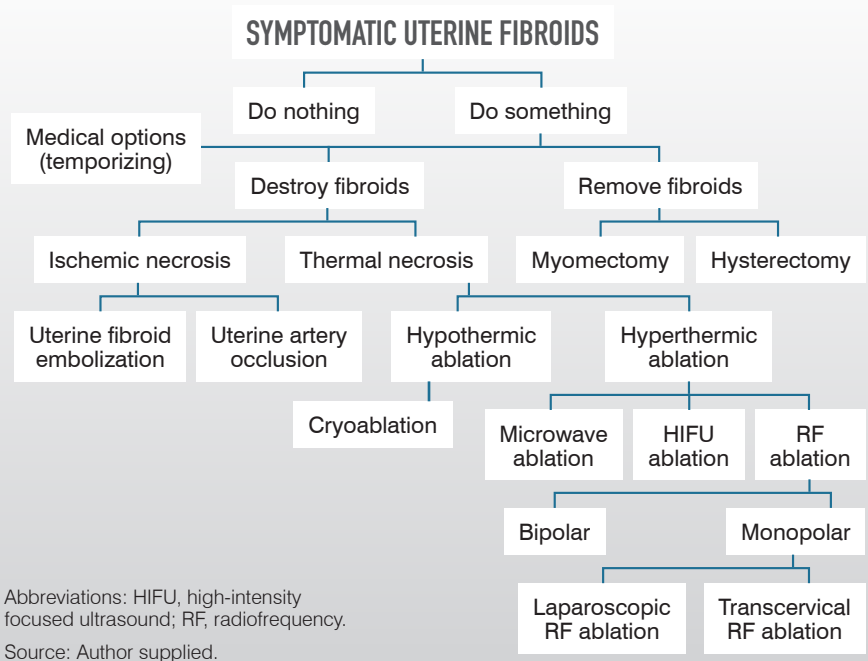
Understanding the technology behind a newer uterus-sparing option for the management of uterine fibroids.

by SHABNAM GUPTA, MD; AND JAMES ADAM GREENBERG, MD

Uterine fibroids (also known as leiomyomas or myomas) are the most common pelvic tumors found in women and the most common indication for hysterectomy.¹ There is a nearly 70% prevalence in premenopausal White women and over 80% prevalence in premenopausal Black women. These tumors can cause symptoms including abnormal uterine bleeding with heavy menses, pelvic pain (both menstrual and nonmenstrual), bulk symptoms (eg, abdominal distention, bowel or bladder dysfunction, early satiety), and reproductive issues (eg, recurrent pregnancy loss, infertility).²

Treatment options for fibroids can be divided into 3 approaches: temporizing measures to shrink fibroids, destruction of in situ fibroid tissue, or

FIGURE 1 Treatment Options for Management of Uterine Fibroids



JAMES ADAM GREENBERG, MD, is associate professor of obstetrics and gynecology at Harvard Medical School and chief of gynecology at Brigham & Women's Faulkner Hospital in Boston, Massachusetts.



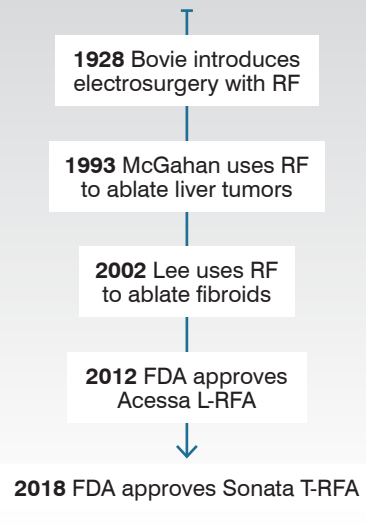
SHABNAM GUPTA, MD, is a minimally invasive gynecologic surgery fellow at Brigham & Women's Hospital and degree candidate at the Harvard T.H. Chan School of Public Health.

removal of fibroids (**Figure 1**). Temporizing measures often employ hormonal medications that exert influence on the hypothalamic-pituitary-gonadal axis. The gonadotropin-releasing hormone (GnRH)-agonist analogue (leuprolide) and GnRH-antagonist (elagolix and relugolix) work by decreasing pituitary secretion of luteinizing hormone and follicle-stimulating hormone, resulting in reduced ovarian follicular activity, anovulation, and low serum concentration of estradiol and progesterone. While fibroid size decreases in response to decreased estrogen and progesterone, these medications can have adverse effects, including hot flashes and reduced bone mineral density, which limit their long-term use. Additionally, these medications have a very limited effect on reducing fibroid size, which is not helpful for women affected by bulk symptoms.

Women who do not desire or do not respond to medical management, or those who have contraindications to these options, may elect surgical treatment. While hysterectomy is the only definitive surgical treatment, uterus-sparing procedures are often sought due to their less invasive and fertility-sparing nature. Surgical management of fibroids can be divided into resective and nonresective procedures. Myomectomy is a procedure in which fibroids are resected from the uterus via transabdominal, laparoscopic, or hysteroscopic approaches.

Techniques to reduce the size of fibroid tissue without overt resection include uterine fibroid embolization, focused ultrasound (FUS), which can be performed under magnetic resonance guidance (MRgFUS) or ultrasound guidance (USgHIFU), and radiofrequency (RF) ablation (RFA). Here, we will focus on nonresective RFA technology for

FIGURE 2
Timeline of Radiofrequency Use in Surgery



Abbreviations: L-RFA, laparoscopic radiofrequency ablation; RF, radiofrequency; T-RFA, transcervical radiofrequency ablation.

management of uterine fibroids, with an emphasis on understanding the basic principles underlying this technology.

History of electrosurgery

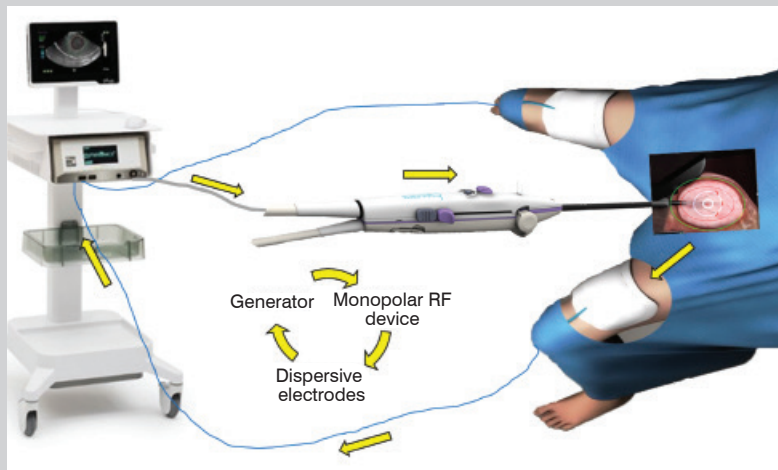
Electrosurgery first came about in the 1920s. William Bovie, PhD, was an American inventor and scientist. He completed his PhD in plant physiology at Harvard University in 1914. He was credited with conceptualizing biophysics and inventing a crude monopolar RF electrode in 1928 (now widely used in surgery and called the Bovie). In the 1990s, RF energy was first suggested to ablate liver tumors. Since then, RFA has been applied to treat cancers in the adrenal gland, breast, kidney, bone, lung, pancreas, and thyroid, and it is also used for nerve ablation in the treatment of pain syndromes. Bruce Lee, MD, was first reported to use RFA on uterine fibroids in 2002. He spearheaded the creation

of a laparoscopic ultrasound-guided approach to treat fibroids using RF energy, known as the Accessa procedure (Hologic). This device received FDA approval in 2012. In parallel, another technology focused on a transcervical approach to RF fibroid ablation began its development in 2005. That technology, Sonata (Gynesonics), a RFA device using an incisionless transcervical approach to ablate fibroids, was cleared by the FDA in 2018 (**Figure 2**).

How does RFA work?

RF waves have the longest wavelength, lowest frequency, and lowest energy on the electromagnetic spectrum (RF range, 3 kHz-300 GHz; medical RF range, 450 kHz-500 kHz). These characteristics make application of RF waves an ideal candidate for controlled and predictable ablation of human tissue. A generator creates alternating current that is transmitted to target tissue via exposed electrode (**Figure 3**). Current travels back to electrode return pads (grounding) to complete the circuit. In electrosurgery, typically there is a cathode or point where electrical current leaves a polarized electrical device. This is known as the active electrode, and the RFA probe tip functions as the cathode in the system. The electrical current transfers energy to surrounding structures through a process termed energy flux. A small cross-sectional area of the probe tip leads to high energy flux at the area in closest proximity to the active electrode. Monopolar electrical systems require return dispersive electrodes, which are typically used in the form of pads placed transversely on the patient's anterior thighs, in order to close the electrical circuit. The large cross-sectional area of the dispersive electrodes leads to a very small energy flux and therefore

FIGURE 3 The RFA Circuit



Abbreviations: RFA, radiofrequency ablation; RF, radiofrequency.
Source: Author supplied.

serves as a safe way to disperse the energy return in the circuit. It is important to ensure proper placement of dispersive electrodes because any break of the closed circuit can cause electrical shorts that result in patient burns.

Factors influencing size and shape of ablation

A few essential concepts should be considered when thinking about the use of RF waves to ablate tissue. Factors that influence the size and shape of the ablation zone include tissue temperature, tissue conductivity, and arrangement of electrodes.

TISSUE TEMPERATURE

The RF probe itself is not the source of heat. It generates an alternating electromagnetic field that causes adjacent molecules (composed of mostly water) to vibrate. These particles in motion generate heat, which is transmitted farther by tissue conductivity. The temperature drops exponentially as distance from the source electrode

increases. Further, temperature rise has predictable cellular effects. At temperatures greater than 60 °C, cell death occurs. Between 60 °C and 99 °C, tissue desiccation and protein coagulation occurs. At temperatures greater than 100 °C, vaporization and charring may occur. Both the temperature reached and the duration of exposure are important. Human tissue is very sensitive to temperature changes and the time to reach cell death differs depending on the temperature. For example, at 55 °C, tissue death occurs within 2 seconds. At 100 °C, cell death is effectively instantaneous. This is not a desired outcome in application of RFA, as charred tissue insulates and prevents transmission of heat. Instead, a slow, methodical deposition of energy is more effective in ablating target tissue rather than a rapid and high temperature rise.³

TISSUE CONDUCTIVITY

Safely calculating the size of the targeted-tissue ablation is crucial to both laparoscopic and transcervical RFA (L-RFA,

T-RFA), and both technologies assume maximal tissue damage when calculating the ablation times. One limitation of RFA is its need for good electrical and thermal conductivity to achieve tissue injury. In vivo, maximal ablations are challenging due to “heat sinks” and insulators. The electromagnetic waves that are needed to ablate tissue propagate only through viable cells. Heat sinks, such as blood vessels that reduce simple thermal conduction and/or charring of tissue that insulates against simple thermal conduction, can reduce tissue temperature and thus yield submaximal ablations. An appreciation for these principles has enabled engineers to develop devices with predictable ablation zones to maximize the target tissue ablation and minimize surrounding tissue damage when applying this technology to patients.³

ARRANGEMENT OF ELECTRODES

By understanding electromagnetic and thermal conductivity principles of tissue ablation, one can quickly see that a single electrode will yield a cylindrical ablation zone rather than the spherical injury that is desired. To overcome this limitation, engineers have developed several different electrode designs (plain, cooled, wet, expandable, and bipolar) with varying combinations employed to achieve the desired application.⁴ The details and advantages of these features go beyond the scope of this review, but both Acesa and Sonata employ plain, expandable, multitined electrodes.

L-RFA and T-RFA

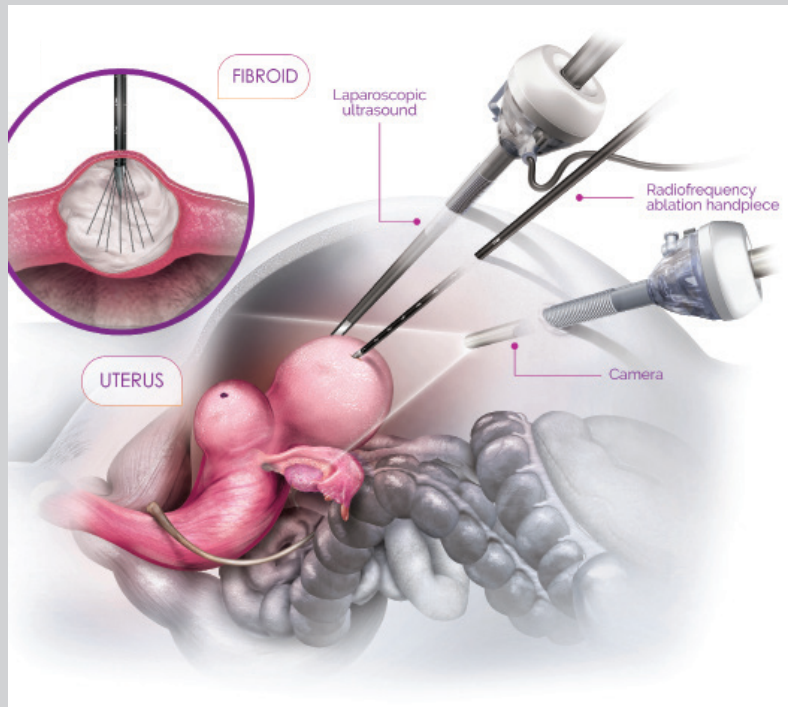
Both L-RFA and T-RFA are safe and effective procedures once surgeons have been appropriately trained on

their use. While both technologies utilize ultrasound guidance to direct placement of monopolar, expandable, multitined RF electrodes into myomas, they do differ in how they achieve this.

Laparoscopic RFA (Acessa procedure)

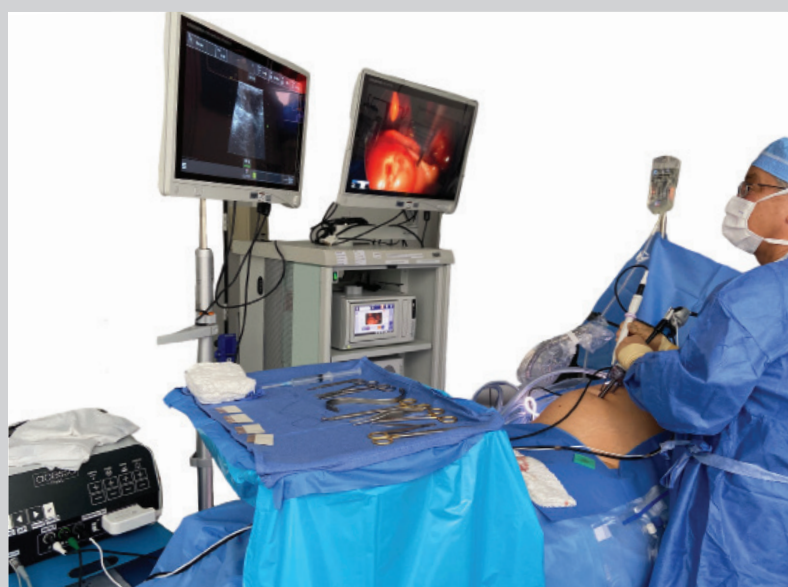The Acessa ProVu System enables percutaneous, laparoscopic sonography-guided RFA of uterine fibroids. A standard 5-mm laparoscope is used in combination with a 10-mm reusable laparoscopic ultrasound probe and a separate disposable RF handpiece, which enters the abdomen through a small adjacent percutaneous incision. The ultrasound probe is placed directly on the uterine serosa to identify the location and size of the fibroids. Next, using the Acessa Guidance System, electromagnetic spatial tracking is employed to orient and position the handpiece. The handpiece is advanced to the fibroid and carefully inserted 1 cm into the fibroid capsule. The electrode array is deployed into the fibroid and appropriate placement confirmed. The ablation process is initiated by depressing a foot pedal. The RF generator then begins to heat the tissue. Once the tissue target temperature (95 °C) is reached, the ablation time begins. After the ablation duration is complete, the foot pedal is again depressed to stop the procedure. The electrode arrays are then retracted, and the handpiece tip is allowed to cool for 60 seconds prior to removing from the target tissue. Hemostasis is obtained by switching the device to coagulation mode and continuously pressing the foot pedal to cauterize the penetrated tissue as the handpiece is removed from the uterus. The next fibroid can then be targeted in the same manner (**Figures 4 and 5**).

FIGURE 4 The Acessa Procedure Diagram



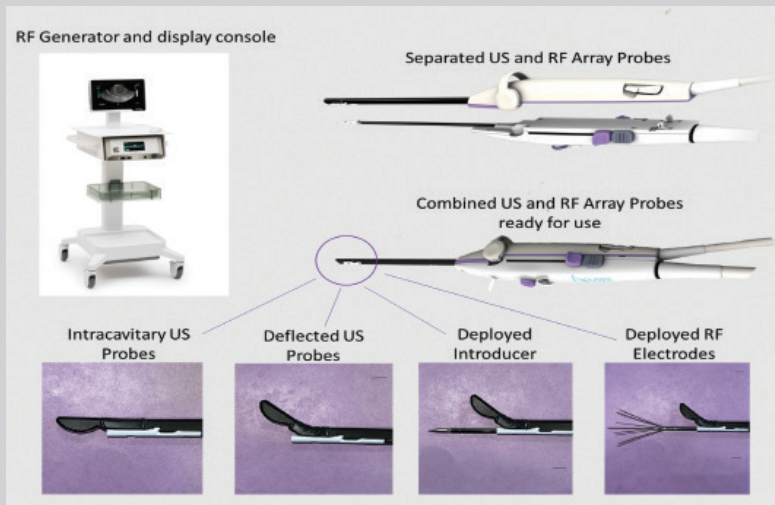
(Used with permission: Yu et al. JSLS. 2020)

FIGURE 5 The Acessa Procedure



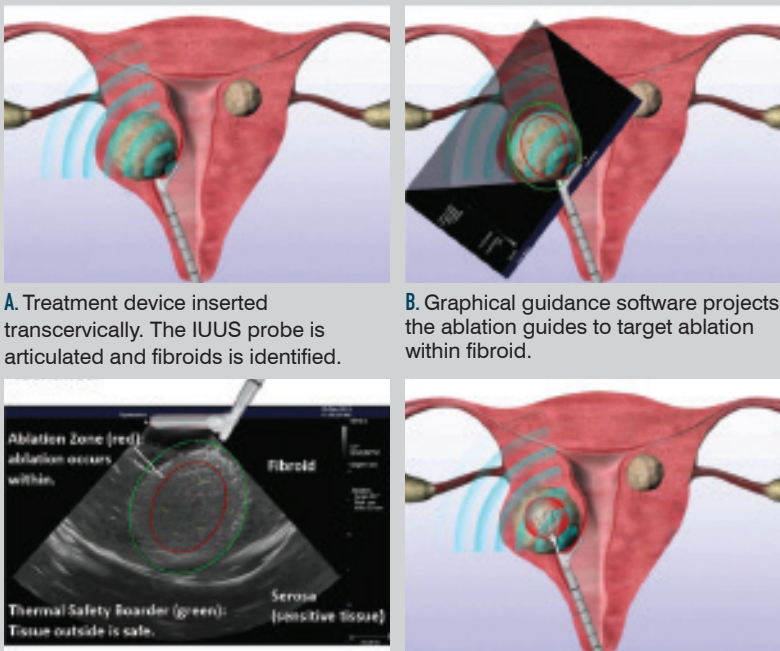
(Used with permission from Hologic)

FIGURE 6 Components of Sonata System



Abbreviations: RF, radiofrequency; US, ultrasound

FIGURE 7 The Sonata Procedure



A. Treatment device inserted transcervically. The IUUS probe is articulated and fibroids is identified.

B. Graphical guidance software projects the ablation guides to target ablation within fibroid.

C. Ablation guides control size and location of ablation. Tissue outside of the safety border is safe.

D. Electrodes deployed to a mechanical stop set to match the ablation guide setting, and ablation performed.

Abbreviations: IUUS, intrauterine ultrasound
(Used with permission: Galen DI .BioMed Eng Online.2015 and Brucker et al. IJGO.2014)

Transcervical RFA (Sonata System)

The Sonata System enables sonography-guided RFA of uterine fibroids using an incisionless, transcervical approach. The device design consists of a reusable curvilinear intrauterine ultrasound probe and a single-use RFA handpiece that combine into a single unit. The cervix is serially dilated to 27F to accommodate the 8.4-mm diameter of the assembled device (combined ultrasound probe and RFA handpiece).

The RFA handpiece also comes equipped with a port for infusing hypotonic fluid into the endometrial cavity as needed for acoustic coupling. In our experience, backfilling the bladder with sterile water can help achieve greater contrast of adjacent pelvic structures. The device is advanced to the fundus and a survey is performed to identify the size and location of fibroids. Once the surgical planning is complete, the first fibroid is identified on the screen.

The SMART (Setting Margins on Ablation in Real Time) Guide graphical overlay is visible on the ultrasound image. This provides the user with essential information for targeting the treatment area prior to deploying electrodes and initiating the ablation process. The inner red ellipse indicates the intended ablation zone. The outer green ellipse indicates the thermal safety border and distance from the needle electrodes at which tissue is safe from potential thermal damage. The ultrasound probe tip is articulated to 45° or 60°, depending on the angle needed for optimal visualization. The ablation size and depth can be adjusted to maximize the target area and minimize thermal injury to adjacent structures. The minimum size is 20 mm × 13 mm, and the maximum size is 49 mm × 42 mm.

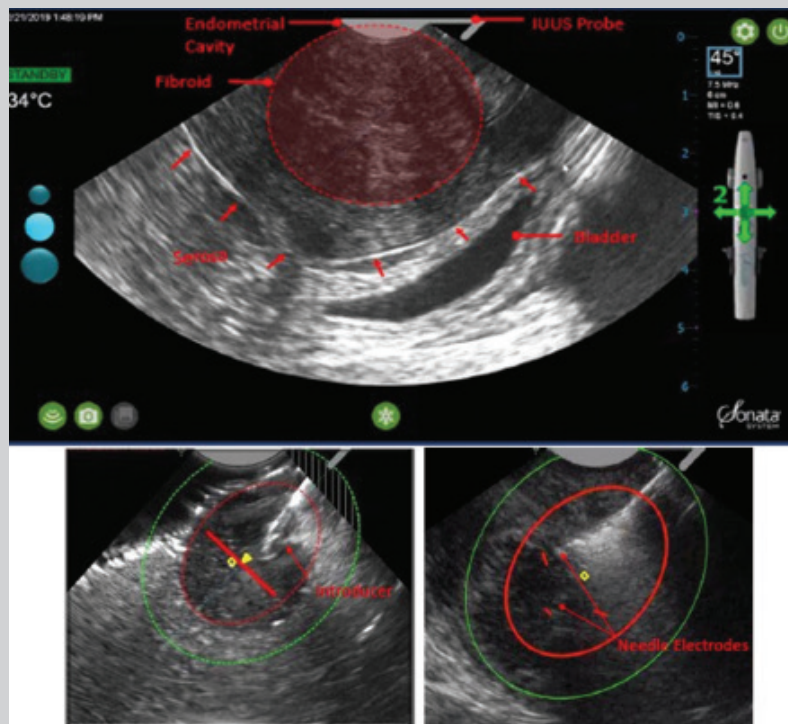
Once the desired ablation zone has been set, a sharp cannula is deployed from the shaft of the RFA handpiece, penetrating the fibroid tissue and stabilizing the device. The first safety rotation is then performed to confirm that the thermal safety border is within the uterine serosa, and that no unintended organs are within the green ellipse margins. Adjustments to the anticipated ablation zone are made as needed. The needle electrodes are then deployed, and a second safety rotation is performed. Traction on the tenaculum can help to delineate the serosal border and assist with visualization of adjacent bladder and bowel. Once safety has been confirmed, the device is held steady, and the footswitch is pressed to start the ablation process.

The Sonata System operates at 460 kHz. As the RF energy is applied to the tissue, the tissue temperature rises and results in subsequent thermal fixation and coagulative necrosis. Depending on the size of the ablation, RF energy delivery time ranges from 1.5 to 7 minutes after reaching the target temperature of 105 °C. Close observation of the display screen should be employed throughout the entire ablation process. Once the ablation is complete, the RF generator will automatically turn off. The needle electrodes and introducer can then be retracted, and the ultrasound probe can be articulated back to 0°. A subsequent ablation can then be performed on the same fibroid or on additional fibroids targeted in the same manner (Figures 6, 7, and 8).

Fibroid mapping

For both procedures, we have found that fibroid mapping at the start of the procedure helps surgeons develop a

FIGURE 8 The Sonata Procedure



(Used with permission from Gynesonics)

strategy for the procedure's ablations and improves with communication about what was done. Mapping is easy. Before any ablations are performed, a systematic ultrasound of the uterus is performed and the size, type, and location of each identified myoma is recorded. For T-RFA, we start with the ultrasound probe placed at the fundus and directed anteriorly. We then rotate the probe clockwise and record all the identified myomas in numerical order by their location on a clock with 3 o'clock at the patient's left. Once this is completed at the fundus, we pull the probe back to the mid-uterus and then lower uterine segment and repeat the mapping process. Having completed our mapping, we then proceed with the ablations and recording them based

on how the myomas were mapped (for example, our first ablation might be recorded on myoma No. 3 in our map).

Comparing L-RFA and T-RFA

At their core, L-RFA and T-RFA are almost identical with their reliance on ultrasound to guide the placement of an array of RF electrodes into myomas via a sharp, central trocar. However, the design differences necessitated to accommodate a laparoscopic vs a transcervical approach imbue each system with distinct advantages and disadvantages when comparing the 2 (Figure 9). In our limited experience, with its combined intracavitary ultrasound/electrode device, T-RFA tends to more easily and efficiently treat myomas that

FIGURE 9 Comparison of Acesa and Sonata

	Sonata	Acesa
Incisions	None	5 mm, 12 mm
Anesthesia	MAC	General
Procedure Time	●	●
Learning Curve	●	●
Myoma Type 0	●	●
Myomas Types 1, 2, 3, 4	●	●
Myoma Types 5, 2-5	●	●
Myomas Type 6	●	●
Myomas Type 7	●	●
Myomas > 10 cm	●	●

● Easy/good ● Mediocre ● Challenging

are smaller (< 8 cm) and closer to the cavity (FIGO types 1, 2, 3, 4) while the L-RFA's separate laparoscopic electrodes and ultrasound components allow it to better address larger myomas (> 10 cm) and myomas that are farther from the cavity (types 6, 7). Both are similar for the treatment of type 5 and type 2 to 5 myomas. It should be noted that the American College of Obstetricians and Gynecologists (ACOG) Practice Bulletin 228 (2021) indicated L-RFA and T-RFA are similarly effective.⁵

Individualizing patient care

Although the pathologies of patients with fibroids may be histologically similar, the approaches to addressing the symptoms related to their fibroids should be individualized based on the size and location of the fibroids and each patient's needs and expectations. Given the numerous nonextirpative interventions for treating uterine fibroids, it is imperative that clinicians manage patient expectations. While

seemingly intuitive, patients need to clearly understand that their fibroids are still in situ and that symptom improvement will likely be appreciated over time rather than immediately. Also, patients whose myomas have an intracavitary component should be counseled to expect both discharge and passage of tissue as the myoma sloughs off ablated material.

Contraindications for use of both L-RFA and T-RFA include current pregnancy, presence of intratubal implants, active pelvic infection, and/or suspected gynecologic malignancy or premalignancy. Additionally, these approaches should be used with caution in patients who have coagulopathy, metal implants in their lower extremities, or very thin thighs where the electrodes overlap. In addition, the safety and efficacy of these approaches have not been well established in women desiring future fertility and those with adenomyosis, although further studies are being conducted to better understand these populations.

Limitations also include no tissue sampling with current designs. Thus, clinicians must carefully select patients and counsel patients when appropriate on the very small risk of occult malignancy.

RFA and future fertility

While neither L-RFA nor T-RFA is contraindicated for use in women desiring future pregnancies, as of the writing of this review, neither L-RFA nor T-RFA is approved by the FDA for labeling that suggests there are adequate safety data in this regard. Reflecting that, the instructions for use for both Acesa and Sonata clearly state that the safety and effectiveness of their technologies in women who are planning future pregnancies has not been established.^{6,7} Nonetheless, an increasing body of data on pregnancies after both L-RFA and T-RFA suggests that these technologies may be compatible with safe future fertility as one might expect based on experience with the thermal ablation of myomas using MRgFUS, which in 2015 received FDA approval for use in patients desiring future fertility.⁸⁻¹⁰

Summary

The introduction of devices capable of safely delivering RF energy to ablate fibroids offers patients desiring uterine preservation an exciting new array of minimally invasive options that were previously unavailable. Both L-RFA and T-RFA are in their infancy, and gynecologists who take care of women with fibroids should acquaint themselves with these technologies so that patients can be appropriately counseled regarding the best options to address their symptoms. ■

FOR REFERENCES VISIT
contemporaryobgyn.net/RFA-for-UF