

BOOK REVIEW

Protocols for High-Risk Pregnancies, 7th Edition Prenatal testing for chromosomal abnormalities

Snapshot: Protocol 5

AUTHOR: Mary E. Norton, MD, departments of obstetrics, gynecology, and reproductive sciences, University of California, San Francisco.

SYNOPSIS: In this protocol, Norton reviews the pathophysiology of fetal aneuploidy and the wide range of tests for it. Included are perspectives on cell-free DNA testing, first-trimester combined screening, nuchal translucency (NT) sonography, and pregnancy-associated plasma protein A (PAPP-A) and human chorionic gonadotropin (hCG), as well as quad marker screening in the second trimester in appropriate cases, and combined first- and second-trimester screening.

Trisomies 21, 18, and 13 are the most common autosomal trisomies. Triploidy and deletions and duplications of portions of chromosomes also occur. With the advent of chromosomal microarray analysis, it is now possible to identify submicroscopic abnormalities associated with significant genetic diseases.

Key Messages


- All pregnant women, regardless of their age, should be offered prenatal screening and diagnostic testing for detection of chromosomal abnormalities.
- Chorionic villus sampling is typically performed at 10 to 14 weeks' gestation, whereas genetic amniocentesis is performed at 15 to 20 weeks.
- cfDNA testing, performed after 10 weeks' gestation, is more than 99% accurate for detection of fetal trisomy 21 and 98% for trisomy 18 with a combined false-positive rate of 0.13% to 0.25%.
- Expanded cfDNA panels, which are available from some laboratories, have not been clinically validated and are not recommended.

- About 85% of trisomy 21 cases can be detected at 10 to 14 weeks' gestation, based on a combination of maternal age, NT sonography, PAPP-A, and hCG. NT sonography should be performed only by credentialed sonographers and physicians.
- Sonographic markers of aneuploidy that may be visible in the first trimester include cystic hygroma, absent nasal bone, abnormal Doppler blood flow in the ductus venosus, and abnormal blood flow across the tricuspid valve with evidence of tricuspid regurgitation. However, first-trimester evaluation for these secondary markers is not recommended for general population screening.
- The optimal time for a genetic sonogram is 18 to 22 weeks. Identification of a major structural malformation

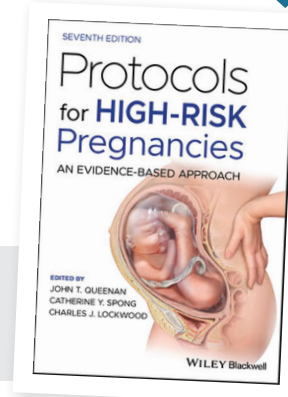
increases risk of trisomy 21 by 20- to 30-fold and should trigger genetic amniocentesis.

- Approaches to combined first- and second-trimester screening include sequential screening and integrated screening. A serum integrated screening approach has a relatively high detection rate but provides a later result. ■



 **WATCH** an interview with Queenenan and Spong here:
<http://www.youtube.com/watch?v=pdgqNU0tnk4>

BUY THE BOOK
VISIT WILEY.COM AND ENTER THE ISBN
[978-1-119-63529-1]



Read the complete chapter on preeclampsia from *Protocols for High-Risk Pregnancies: An Evidence-Based Approach, 7th Edition*, edited by John T. Queenan, MD, John C. Hobbins, MD, and Catherine Y. Spong, MD, now. CONTEMPORARYOBYGN.NET/SDPROTOCOLS