

Understanding abnormal uterine bleeding in adolescents

by OLUYEMISI A. ADEYEMI-FOWODE, MD, FACOG; AND EMILY P. A. BRANDER, MD, FRCSC

Introduction

Abnormal uterine bleeding (AUB) can be acute or chronic and refers to bleeding from the uterine corpus that is abnormal in volume, regularity, and/or timing.¹ Acute AUB is defined as an episode of heavy bleeding that is of sufficient quantity to require immediate intervention to prevent further blood loss.¹ For most individuals, chronic AUB is present for 6 months. Heavy menstrual bleeding (HMB) refers to excessive menstrual blood loss that interferes with a woman's physical, social, emotional, or material quantity of life.²

In adolescents, a typical menstrual cycle ranges from 21 to 45 days, lasts 7 days or less, and requires 3 to 6 pads or tampons per day because of soiling (more may be used for hygiene purposes).³ There are many causes that push a menstrual pattern outside these boundaries. The most common cause of AUB in adolescents is anovulation due to immaturity of the hypothalamic-pituitary-ovarian (HPO) axis. It can take

CASE 1

A 12-year-old girl presents to the emergency department. Menarche occurred 48 days ago and is ongoing. She reports changing her pad every 1 to 2 hours, passing quarter-sized clots, easy bruising, and shortness of breath. Her mother reports a brother with prolonged nosebleeds and that she herself had a hysterectomy due to postpartum hemorrhage. The patient is afebrile, her pulse is 124 bpm, her blood pressure is 100/61 mm/Hg, her respiratory rate is 22 breaths per minute, and her oxygen saturation is 99% on room air. She appears pale and lethargic and has Tanner IV breast and pubic hair development. An external genitalia exam reveals bright red blood at the introitus. Her pad, which has been on for the past hour, is 70% soaked.

up to 3 years after menarche for the HPO axis to mature.⁴ Within those years, investigation is warranted if menses occurs more frequently than 21 days; less frequently than 45 days; or occurs 90 days apart, even for 1 cycle; lasts more than 7 days; requires frequent sanitary product changes (soaking more than 1 every 1-2 hours); or is heavy and associated with a history of excessive bruising or a family history of bleeding disorder (BD).³

The American College of Obstetricians and Gynecologists (ACOG) has standardized the terminology used to classify causes of AUB with the acronym PALM-COEIN, categorizing the etiology of AUB as structural or nonstructural (**Figure 1**),^{4,5} with nonstructural causes predominating

in adolescents. A literature review looking at common causes of AUB by age group noted anovulation and BD were the 2 leading causes of AUB in adolescents.⁶ In a retrospective study on causes of AUB in adolescents hospitalized for HMB, hematologic disease ranked second at 33% next to anovulation (46%).⁷ Causes of anovulation can be physiologic or pathologic (**Figure 1**).^{4,5} Most women with BD report HMB as the most common manifestation of their disorder, and approximately half of adolescent girls with BDs present with HMB at menarche, with 12% requiring hospitalization due to anemia.^{2,8} Approximately 44% of adolescents who present with HMB may have an underlying coagulopathy.⁹ Von Willebrand disease



OLUYEMISI A. ADEYEMI-FOWODE, MD, FACOG, is assistant professor of obstetrics and gynecology in the Division of Pediatric and Adolescent Gynecology at Baylor College of Medicine in Houston, Texas.



EMILY P. A. BRANDER, MD, FRCSC, is a second-year fellow at Baylor College of Medicine in the Division of Pediatric and Adolescent Gynecology at Texas Children's Hospital in Houston, Texas.

(VWD), the most commonly inherited BD, affects 1% of the population, and is estimated to affect approximately 36% of patients with HMB.⁸

HISTORY

History and physical examination are essential for appropriate laboratory and imaging tests. Specific questions are helpful when obtaining a history from adolescents. Adolescents may not be able to describe their menstruation accurately, so using a pictorial blood assessment chart may be helpful in this case, though this tool has not been validated in the adolescent population.¹⁰ If a BD is suspected, screening tools can be incorporated into the history taking (Figure 2). Patients who screen positive should be further evaluated for a BD. It is best to ask permission and have the guardian leave the room temporarily and assure confidentiality before asking sensitive questions about lifestyle choices, sexual activity, and safety.

PHYSICAL EXAMINATION

Besides evaluating all systems, special attention should be paid to the pelvic examination to discern whether the bleeding is from the uterus or another area of the genital tract, such as a cervical/

vaginal or hymenal laceration. In adolescents with HMB, a speculum and/or bimanual exam is typically not required and may not be feasible. If the source of bleeding is unclear and the patient can tolerate it, a speculum and/or bimanual exam should be performed. If they are unable to tolerate it, traction on the labia majora in a down and out fashion will expose the hymen and often the lower third of the vagina (Figure 3). If bleeding is heavy and the patient is unstable, an exam under anesthesia is warranted to determine the source of bleeding.

LABORATORY TESTING

AUB due to anovulation, although common, is a diagnosis of exclusion. It is imperative to rule out pregnancy early in the assessment of any reproductive-aged woman, including the adolescent. An assessment of anemia and coagulation tests should be included. In cases of severe anemia, profuse bleeding, or hemodynamic instability, a blood type and crossmatch are advisable in preparation for blood transfusion. Testing for specific BDs such as VWD should be included if indicated. Second-tier confirmatory BD testing should be done in collaboration with a hematologist. Ideally, all tests of hormones and

coagulation function should be drawn before any treatment commences.

Endometrial tissue sampling in the adolescent population is typically not indicated, as endometrial hyperplasia or malignancy in this age group is rare. A history of unopposed estrogen exposure, such as obesity or polycystic ovarian syndrome (PCOS), coupled with failed medical management can inform this decision. Prior to tissue sampling, evaluating endometrial stripe thickness and assessing for the presence of a hematometra is useful.

IMAGING

Structural causes for AUB in adolescents are uncommon, and thus imaging studies are often low yield.¹¹ However, a patient who is not responding appropriately to treatment should have imaging performed. Ordering a pelvic ultrasound is up to the clinician’s judgment and must take into consideration the patient’s age, availability of equipment, and route of image capture (eg, transabdominal vs transvaginal). The transvaginal route is preferred to assess female reproductive structures, but the transabdominal route may be more appropriate in adolescents.^{2,6}

FIGURE 1. Causes of Abnormal Uterine Bleeding: Expanded to Include Key Causes of Anovulation in Adolescents⁵

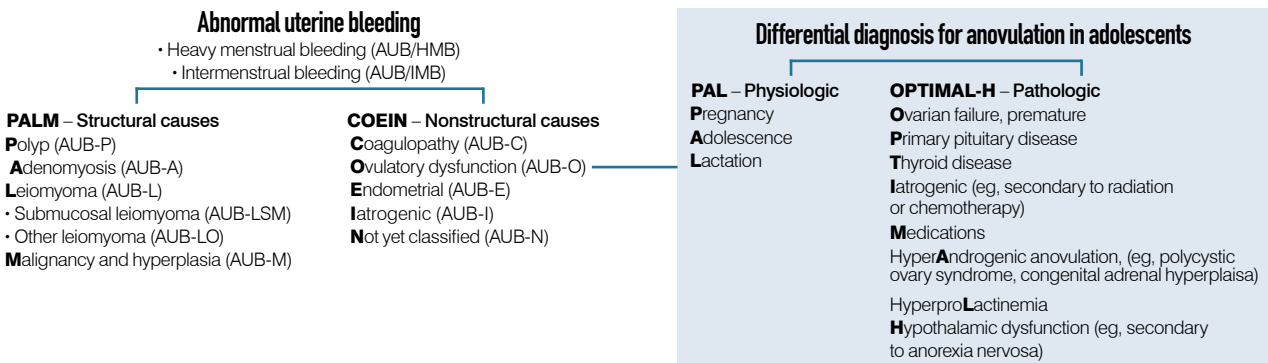
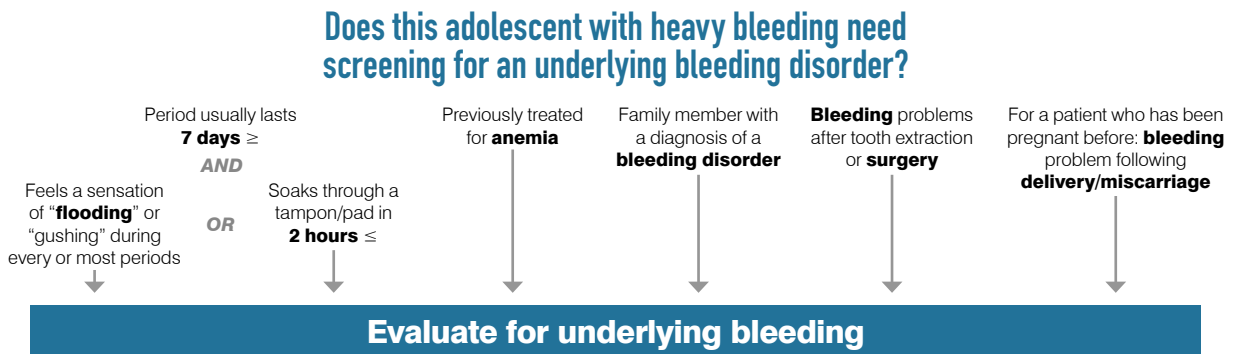


FIGURE 2. Bleeding Disorder Screening Tool



Clinical management

TREATMENT

The objectives of managing AUB are to control the current bleeding episode and to reduce blood loss in subsequent cycles. This goal can be achieved by medical or surgical means. In adolescents, medical management is preferred, given the presumed desire for future fertility.

Medical management

1. Management setting

When a patient has active profuse heavy bleeding (requiring > 1 pad per hour, as well as vital signs with evidence of hypovolemia or orthostatic hypotension) and/or severe symptomatic anemia (hemoglobin < 8 g/dL), inpatient therapy is warranted. Admission to an intensive care setting should be considered in the following scenarios: brisk bleeding; anemia that risks cardiovascular compromise (stroke or myocardial infarction); signs of systemic instability, such as tachycardia or hypotension; or underlying medical conditions.

When the bleeding is slow, the anemia is not severe, and the patient is asymptomatic and has no comorbidities, outpatient therapy is appropriate, with strict bleeding precautions given.

2. Volume expansion

In acute AUB, hypovolemia and anemia

should be addressed in concert. Treatment should begin with the judicious use of intravenous (IV) crystalloids. Transfusion of packed red blood cells (PRBCs) should be performed only if indicated. Guidelines from critical care associations advocate that transfusion of PRBCs be reserved for patients with active bleeding and hemoglobin levels less than or equal to 7.¹² Automatic administration of blood products to young women with anemia should be avoided. This will not only reduce not only the incurrent risks of transfusion reactions but also the risk of alloimmunization and hemolytic disease of the fetus and newborn in any future pregnancies. IV fluid and transfusion rates should be based on weight, and a pediatric intensivist or hematologist should be involved in child-sized patients. Initiation of oral or IV iron therapy is also recommended after an acute hemorrhage. A ferritin level and prior response to iron therapy can direct the route of administration. Adverse effects of iron supplementation include gastrointestinal upset, and thus a bowel regimen should be considered.²

3. Hormone therapy

a. Acute—medical

The mainstay of treating acute AUB is estrogen to stabilize the endometrial

lining. IV conjugated estrogen or alternatively combined oral contraceptive pills (COCPs) can be used. Bleeding typically slows significantly within 12 to 72 hours of administration of either IV or COCPs, but IV formulations work faster.¹³⁻¹⁵ Contraindications to estrogen must be ruled out. If bleeding is not slowing, consultation with a hematologist is warranted. Dosing of estrogen can be tapered when bleeding is controlled. As estrogen can induce nausea, an antiemetic should be given 30 minutes before each dose until the estrogen is tapered.

High doses of COCPs and oral progestin therapy are clinically equivalent for controlling HMB in the adult population.¹⁴ High-dose oral progestins can be used as an alternative and are indicated when estrogen is contraindicated or if a patient cannot tolerate the estrogen-induced nausea and vomiting.¹⁴ Conventional doses of progestins in the setting of acute bleeding will likely lead to treatment failure. Thus, high-dose progestin with a taper should be utilized.

After acute bleeding has been controlled, the goal is to maintain amenorrhea while the patient completes any investigations and normalizes their hemoglobin level and iron stores. The hormonal therapy should be continued at doses required to achieve amenorrhea for at least 4 to 6 weeks. Close

follow-up is recommended to evaluate response, taper to a maintenance dose, and determine when a withdrawal bleed can be safely planned. A withdrawal bleed is necessary to shed the disorderly proliferative endometrium that led to the heavy/prolonged bleeding. This is a common cause of failed hormonal therapy with breakthrough bleeding. Endometrial shedding leads to shedding of the endometrium to the level of the basalis, resulting in a better chance for success of maintenance therapy with hormonal options or to observe for normalization of cycles. Most hormonal options used for acute AUB can be used as maintenance therapy at lower doses.

b. Chronic—medical

In the office setting, a patient can present with prolonged AUB and signs of chronic anemia or with more recent HMB superimposed on menstrual irregularities. In the latter case, the patient may have a normal hemoglobin level despite low ferritin levels, indicating iron deficiency. The mainstay is hormonal control with concurrent iron supplementation, if necessary, to correct and prevent anemia.

c. Maintenance therapy

Long-term stabilization of the endometrium can be achieved with either COCPs or progesterone-only therapy.

i. COCPs

For adolescents, the optimal dose of estrogen in a COCP is at least 30 µg. Studies reveal lower rate of bone mass accrual in adolescents using lower-dose pills (< 30 µg) compared with those using pills with at least 30 µg of estrogen.¹⁶ In addition, lower-dose pills can increase risk of breakthrough bleeding (BTB).^{2,16} In patients with AUB caused by PCOS, COCPs will decrease hyperandrogenism

more effectively than progestins alone.¹⁷ Young patients can have difficulty adhering to daily medicines, so options with longer half-lives, such as the contraceptive patch or vaginal ring, can be considered. COCPs also come in chewable formulations, which is helpful in very young patients or patients who have difficulty swallowing pills.

ii. Progesterone-only options

Progesterone-only options for maintenance include pills, injectable depot-medroxyprogesterone acetate (DMPA), and long-acting reversible contraceptives (LARCs). However, any progesterone-only treatment has the risk of unscheduled BTB.¹⁸ Adolescents should be warned of this potential adverse effect to improve adherence. DMPA has potential adverse effects of weight gain and decreased bone mineral density (BMD).^{19,20} The decreased BMD is typically mild and substantially reversible upon discontinuation,^{17,21} but adolescence is a time of bone density accrual,¹⁶ so this should be taken into consideration when prescribing DMPA. Fears about its deleterious effects on bone health in adolescents led to a black box warning from the FDA in 2004.²¹ ACOG has since released a response urging that “the effect of DMPA on BMD...should not prevent

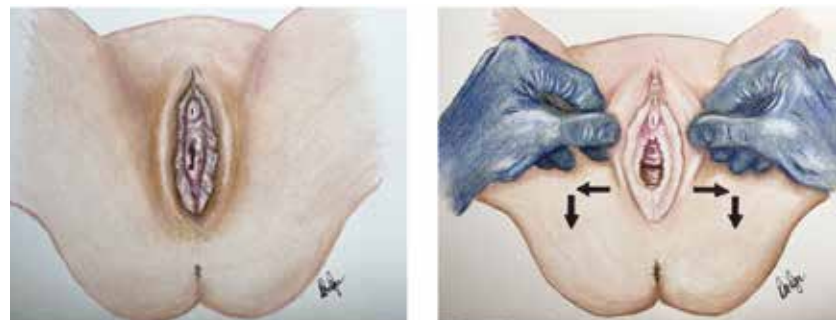
practitioners from prescribing DMPA or continuing use beyond 2 years.”²¹ The risk of unintended pregnancy should be weighed before discontinuing an effective therapy.

Because adherence can be an issue in this population, LARCs, such as a contraceptive implant or the 52-mg levonorgestrel-releasing intrauterine device (IUD), can be considered. During treatment of HMB, LARCs can be concomitantly used from contraception.²² Both methods can cause unscheduled bleeding, but the implant tends to cause more BTB and is not recommended first line for those patients with a proven BD.² IUDs are safe therapies to control AUB in adolescents and have high patient-satisfaction ratings.²³

4. Nonhormone therapy

Antifibrinolytics, such as IV or oral tranexamic acid (TXA), can also be used emergently for treatment of acute AUB,⁶ but they can also be used as cyclic monotherapy every month or in combination with hormone therapy in cases of chronic HMB.^{6,24} In patients with BDs, hormonal management alone might not be sufficient to control bleeding. There have been theoretical concerns for increased clotting risk with combined use of hormonal and antifibrinolytic medicines, but there is currently not

FIGURE 3. Labia Majora Traction



CASE 2

A 16-year-old girl with a history of obesity is referred to the gynecology clinic for complaints of irregular and heavy menstrual bleeding. She reports menarche at age 14, irregular menses occurring every 2 to 5 months that last 7 to 14 days. Her current menses started 12 days ago and remains heavy. She is also complaining of increasing weight gain despite exercise, acne on her face and back, and hair growing on her chin and lower back. She is afebrile, her body mass index (BMI) is 35 (99th percentile for weight), her pulse is 90 bpm, her blood pressure is 125/61 mm/Hg, her respiratory rate is 14 breaths per minute, and her oxygen saturation is 99% on room air. Examination reveals hirsutism and acne on her face and lower back. On external genitalia exam, mild clitoromegaly is noted. Her pad, which has been in place for 5 hours, is 40% soaked. Laboratory results from the referring provider are notable for hemoglobin level of 8.2 ng/gL and ferritin level of 5 ng/mL.

enough evidence to support this.² In addition to IV route, liquid and tablet formulations of TXA are available.

Patients with BDs related to platelet dysfunction should be counseled to avoid all nonsteroidal anti-inflammatories, especially when treating menstrual cramps, as these can further impair platelet function and result in heavier bleeding.

5. Surgical management

Surgical intervention is considered in the rare cases of persistent heavy bleeding with a lack of response to medical therapy or when severe heavy bleeding warrants an examination under anesthesia. This is because uterine surgery has a risk of adversely affecting the young patient's future fertility. Intrauterine balloons designed for obstetric use in adults are not appropriately sized for adolescents. Instead, a foley catheter should be used. There are reports demonstrating the use of a foley catheter balloon that can be easily inserted through the cervix and inflated for tamponade effect.²⁵ Suction evacuation of the uterus can be considered if an ultrasonography identifies a clot, decidual cast, hematometra, or with failure of medical therapy. Sharp curettage can result in increased bleeding in patients with a BD.

Interventions, such as endometrial ablation, uterine artery embolization, and hysterectomy, are considered last resort measures, given the presumed desire for future fertility in adolescents.

CASE 1 CONCLUSIONS

This case demonstrates the acute hemorrhage that can occur immediately with menarche, which may be an underlying BD rather than an anovulatory bleeding pattern. Work-up should include a blood count (type and screen), a bleeding panel (investigation of thyroid function), and coagulation factors and tests for VWD. A urine β -hCG test should be done to rule out pregnancy. A pelvic ultrasound can be considered, but is less likely to reveal a structural cause of AUB in adolescents. With severe anemia and ongoing bleeding, admission or outpatient therapy is a first decision point. The patient's treatment should consist of IV fluids, a blood transfusion in a monitored setting, and IV estrogen. This should stop the bleeding in 24 to 48 hours. IV or oral TXA can also be initiated on presentation. The patient can then be transitioned to oral therapy, typically with a COCP with a tapered dose. If the patient cannot have estrogen, acute therapy should include high-dose oral progestins with a slow taper.

After 4 to 6 weeks of hormonally induced amenorrhea, the patient is evaluated. If her anemia has recovered sufficiently, a withdrawal bleed can be considered before initiating maintenance therapy to decrease the risk of unscheduled bleeding. Treatment of iron deficiency should be initiated and continued as an outpatient. In these cases, involvement of hematology is beneficial, especially as most BDs require repeat and in-depth testing to diagnose.

CASE 2 CONCLUSIONS

This case suggests an anovulatory bleeding pattern. In addition to workup for acute bleeding as outlined in the prior case, PCOS screening should be included, given history and physical exam findings. PCOS is a diagnosis of exclusion, including a 17-OHP test to rule out congenital adrenal hyperplasia and excessive dehydroepiandrosterone sulfate production to exclude an adrenal hyperandrogenism. A pelvic ultrasound can be obtained if testosterone levels are very elevated, which is suggestive of an androgen-secreting tumor. Pelvic ultrasounds have a limited role in diagnosing PCOS in adolescents, as polycystic ovarian morphology can be physiologic in this population.

Treatment of acute menstrual bleeding can begin before transitioning to maintenance. For suspected PCOS, combined hormonal therapy helps decrease symptoms of hyperandrogenism. With a hemoglobin level above 7.0, a blood transfusion is not indicated, but iron supplementation should be given. Given the patient's BMI, in addition to hormonal therapy to control bleeding, lifestyle modification counseling is indicated. ■

FOR REFERENCES, VISIT
contemporaryobgyn.net/AUB