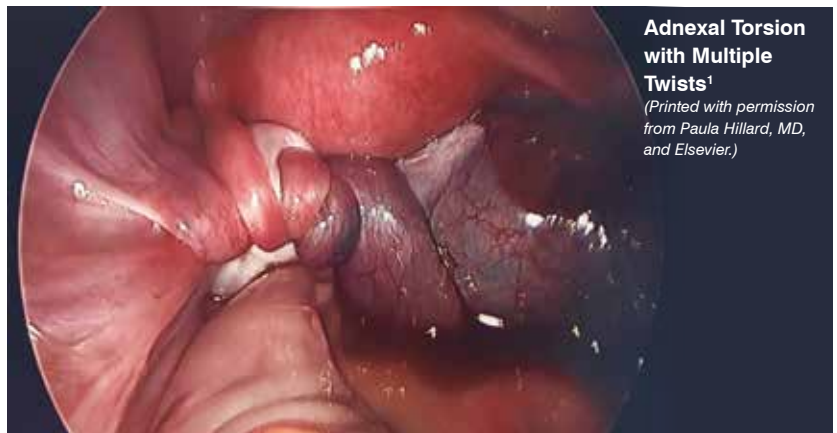

## Adnexal torsion requires careful diagnosis, management *by* STEPHANIE M. CIZEK, MD

**T**orsion of adnexal structures (including torsion of the ovary, fallopian tube, or both) is the fifth most common gynecologic emergency.<sup>1</sup> It can occur at any age, although it is more likely in individuals 10 years and older, with an average being age 30 years.<sup>1-3</sup> It is the sixth most common pediatric surgical emergency and is estimated to affect 5 of every 100,000 individuals aged 1 to 20 years; 16% of pediatric torsion cases will occur prior to age 1 year.<sup>1</sup> It can also occur in pregnant women, women post hysterectomy, and postmenopausal women.

### Why talk about torsion?

Both pediatric and adult patients are at risk for delayed or missed diagnosis of torsion. The main presenting symptoms of adnexal torsion are abdominal pain and nausea. Torsion pain is classically intermittent, leaving some patients clinically well appearing in between pain episodes. Imaging, particularly the presence of vascular flow to the



adnexa, can provide false reassurance that torsion is not present. Providers may erroneously ascribe torsion pain to a “ruptured cyst” or “hemorrhagic cyst.” Finally, particularly in the pediatric and adolescent population, gynecologic etiologies of pain are often not considered.

### How do patients with torsion present?

The presence of symptoms such as diarrhea, dysuria, abnormal vaginal

discharge, and vulvovaginal pain/itching are not typical for torsion (**Table 1**).<sup>1,4,5</sup> In neonates, torsion typically presents with nonspecific symptoms such as inconsolability or feeding intolerance, and the infant may have an abdominal mass on examination.<sup>1</sup>

Vomiting may be a good positive predictor of torsion. In a study of pediatric torsion, 83% of premenarchal patients and 100% of postmenarchal patients with a confirmed surgical diagnosis of



**STEPHANIE M. CIZEK, MD**, completed a fellowship in pediatric and adolescent gynecology and is now a clinical assistant professor in the Department of Obstetrics and Gynecology at Stanford School of Medicine in California.

**TABLE 1. Patient History:**  
Key Points for Adnexal Torsion<sup>1,4,5</sup>

<b>Acute lower abdominal pain</b>	Unilateral (right or left lower quadrant) Often intermittent over days (can be months)
<b>Nausea and vomiting</b>	Vomiting usually present in torsion
<b>Menstrual history (last menstrual period, typical cycle length/pain)</b>	Severe dysmenorrhea can also present as pain/vomiting Hemorrhagic corpus luteum usually later in menstrual cycle, may grow large if anovulatory cycling
<b>Sexual history</b>	Rule out STI/PID Determine whether emergency contraception is needed

PID, pelvic inflammatory disease; STI, sexually transmitted infection.

**TABLE 2. Patient Exam:**  
Key Points for Adnexal Torsion<sup>1</sup>

<b>Vital signs</b>	Often normal Mild temperature elevations possible; fever uncommon Tachycardia, hypertension possible during acute pain
<b>Abdominal pain</b>	May have minimal pain in intermittent phase between acute pain episodes
<b>Pelvic exam</b>	If indicated, assess other etiologies such as PID

PID, pelvic inflammatory disease.

torsion presented with vomiting as well as abdominal pain.<sup>4</sup>

In all patients, a pelvic exam should be performed judiciously and is not necessary to diagnose torsion (**Table 2**).<sup>1</sup> Pelvic exams may be most informative for sexually active patients to help distinguish pelvic inflammatory disease (which can also present as adnexal tenderness) from torsion (typically pain is worst in 1 adnexum and a mass may be palpable). In young or premenarchal patients, an external exam is needed if vulvar pathology or imperforate hymen are suspected (**Box**).

### What labs should be ordered?

If malignancy is suspected, then serum tumor markers should be ordered, even if urgent surgical management is performed. Young patients are more likely to have a germ or stromal cell tumor and should have a quantitative  $\beta$ -human chorionic gonadotropin test, as well as tests for  $\alpha$ -fetoprotein, lactate dehydrogenase, and inhibin A and inhibin B (**Table 3**).<sup>1,2</sup> All patients (any age) should have a cancer antigen 125 test if there is concern about malignancy.<sup>1</sup>

### What imaging tests should be done?

**Pelvic ultrasound:** Ultrasound is first line in the diagnosis of torsion and should be performed urgently in the emergency department setting when torsion is considered.<sup>2,6</sup> Although transvaginal pelvic ultrasound results in better imaging of the adnexa, transabdominal ultrasound is typically used in the pediatric and adolescent presexually active population. A full bladder for transabdominal ultrasound may be difficult in patients with developmental delay or in young children.

**CT and MRI:** These may be good second-line diagnostic tools; however, both have limited differences in sensitivity/specificity compared with ultrasound, may delay evaluation, and may incur higher cost.<sup>2,6</sup> CT is less preferred in pediatric patients because it involves ionizing radiation.

In a 2020 review, the addition of color Doppler imaging to ultrasound slightly improved both sensitivity and specificity but was not statistically significant.<sup>6</sup> The presence of Doppler arterial and/or venous flow does not rule out a diagnosis of torsion, because patients

with normal vascular flow per imaging may still have torsion (up to 60% in one study) (**Table 4**).<sup>2,7,8</sup>

Pediatric and adolescent patients are more likely to have torsion in the absence of an ovarian cyst (up to 46%) compared with adults.<sup>2</sup> In the absence of an adnexal mass, the only imaging finding may be volume differences from associated ovarian tissue edema of the torsed ovary or because a larger ovary itself may be a nidus

## Clinically Indicated Pelvic Exams (Bimanual/speculum) in emergency department

### Sexually active with...

- Abnormal discharge
- Concern for vaginal trauma, mass, foreign body
- Pelvic or abdominal pain without other clear etiology
- Forensic exam for abuse

### Everyone, regardless of age or coitarche status:

- Needs to consent to any genital exam
- Consider whether exam under sedation  $\pm$  vaginoscopy is more appropriate

**TABLE 3. Laboratory Evaluation for Adnexal Torsion<sup>1,2</sup>**

<b>Pregnancy test</b>	Rule out obstetric causes of pain Facilitate urgent surgery
<b>COVID-19 test</b>	Facilitate urgent surgery
<b>Complete blood count</b>	Often mild leukocytosis; significant leukocytosis less common If ruptured cyst on differential, hemoglobin/hematocrit to assess blood loss
<b>Urinalysis</b>	Rule out urinary tract infection as cause of pain
<b>Serum tumor markers</b>	If concern for malignancy
<b>STI testing</b>	As indicated for sexually active patients

STI, sexually transmitted infection.

**TABLE 4. Imaging Findings Concerning for Adnexal Torsion<sup>2,7,8</sup>**

<b>Adnexal mass</b>	Risk of torsion increases if adnexal mass > 5 cm is present Pediatric/adolescent patients are more likely to torse without a mass
<b>Ovarian stromal edema</b>	Venous occlusion leads to congestion of ovarian tissue
<b>Peripheralization of ovarian follicles</b>	Ovarian cortex, which contains follicles, is stretched around edematous stromal tissue
<b>Ovarian volume difference</b>	May be the only finding in patients without an adnexal mass
<b>Diminished vascular flow on Doppler imaging</b>	Interpret with caution because presence or absence of flow is nondiagnostic
<b>“Whirlpool sign” or “swirl sign”</b>	Visible presence of twisted adnexal vessels Highly specific but uncommonly detected

STI, sexually transmitted infection.

for torsion.<sup>9</sup> Volume differences are common and in torsion are typically notably significant (at least 2.5 times greater volume in the torted ovary).<sup>9</sup> Providers should use caution against overinterpreting volume differences in the setting of an adnexal mass: If there is a cyst, there is naturally a volume difference between the ovaries.

### How is torsion managed?

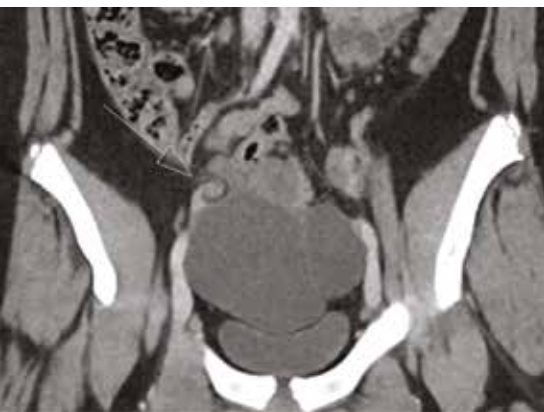
Surgery is the gold standard. The definitive diagnosis and the management of adnexal torsion is done with urgent surgery, typically using laparoscopy. Approximately 50% of patients taken to the operating room because of concern for torsion will have torsion found intraoperatively.<sup>2</sup>

There is no duration of symptoms that reliably predicts ovarian viability. In one study with a median time of 16 hours from symptom onset to surgery, follow-up ultrasound showed normal follicular development in 91% of previously torted ovaries.<sup>3</sup> In another study, patients with viable-appearing ovaries had a median time from presentation to diagnosis of 12 hours, and a median time from symptom onset to presentation of 3 days.<sup>3</sup> The lymphatic and venous obstructions are thought to occur prior to arterial blood flow obstruction, and some “loose” or “partial” torsion cases may have intermittent arterial blood flow, making it difficult to correlate pain onset with

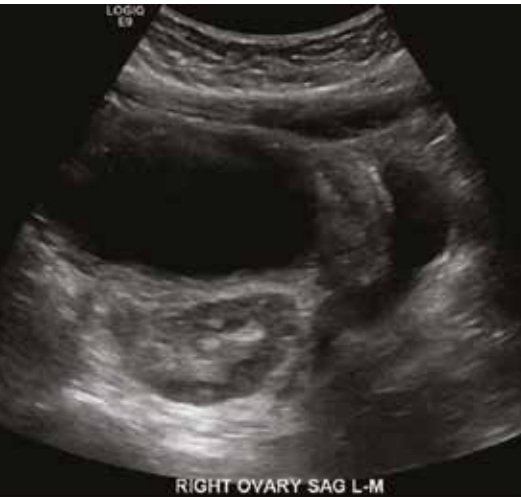timing of true tissue ischemia.<sup>1,3</sup> In a comparison of ovarian to testicular torsion, patients with suspected ovarian torsion waited 2.5 times as long for diagnostic imaging and 2.7 times as long to be taken to the operating room, and the salvage rate for the affected gonad was 14% for ovarian torsion and 30% for testicular torsion.<sup>10,11</sup>

**Nonsurgical management:** The benefit of urgent surgical management when torsion is suspected is salvage of viable tubal and/or ovarian tissue, and improvement in patient pain. In select situations, such as a patient who is a poor surgical candidate, then after careful informed consent and shared decision-making discussion, medical management of pain without surgery (or with delayed, planned surgery) may be considered or even recommended (Table 5).<sup>1,12-14</sup>

There is strong support for retaining torted ovaries in situ even in the setting of gross signs of necrosis. Even an ovary



**Figure 2. Whirlpool sign on CT scan (arrow). This patient had bilateral paratubal cysts and right adnexal torsion on laparoscopy. (Printed with patient permission)**



**Peripheralization of follicles (hypoechoic rim) around the edematous stroma of the right ovary (outlined with dots). This patient had a right paratubal cyst and right adnexal torsion on laparoscopy.** (Printed with patient permission)

appearing necrotic may continue to function, as measured by follicular development on ultrasound.<sup>1</sup> Concerns regarding the increased risk of venous thromboembolism with detorsion or infection if necrotic tissue is left in situ have not been substantiated.<sup>1</sup> Concern for malignancy is also often cited as a cause for oophorectomy, particularly in the pediatric population because at least 10% of pediatric ovarian masses are thought to be malignant.<sup>15</sup> However, a recent large study found only a 1.8% malignancy rate among pediatric patients with ovarian torsion.<sup>15</sup> A large multicenter study found that patients 10 years and younger (particularly those < 3 years old), those with public insurance, and those with chronic medical conditions were all more likely to undergo oophorectomy at the time of torsion, suggesting that many factors may play into surgical decision-making.<sup>16</sup>

### Can oophoropexy prevent recurrence of torsion?

Recurrence is thought to be approximately 5% to 6%. Patients who initially had torsion of a normal ovary have the highest rates of recurrence (15% vs 3% in one study examining recurrence of idiopathic torsion vs torsion in the presence of an adnexal mass).<sup>17</sup>

**Oophoropexy:** The role of oophoropexy in preventing recurrence of torsion is controversial. Oophoropexy aims to reduce the risk of torsion either by fixing the ovary to a structure in the pelvis or shortening the utero-ovarian ligament. There are scant data comparing different oophoropexy techniques, which makes interpretation of efficacy data difficult. Recurrent torsion rates after oophoropexy are estimated to be between 9% and 17%. Because recurrence is highest in torsion of a normal ovary, this population, along with other patients at higher risk (those with bilateral torsion, recurrent torsion, prior oophorectomy, or anatomic risk factors such as long infundibulopelvic ligaments) may potentially benefit most from oophoropexy.<sup>17</sup>

### Conclusion

A swift and accurate diagnosis of torsion requires a high index of suspicion, effective communication, and continuing education of all specialties involved. Gynecology and emergency department providers should keep torsion high on the differential and understand that imaging does not provide definitive evidence against torsion. Operating room staff and anesthesiologists should be aware of the urgent nature of torsion and the intermittent nature of symptoms that may make a patient appear less “urgent” for surgery. Overall, it is

**TABLE 5.**

## Key Points in Management of Adnexal Torsion<sup>1,12-14</sup>

### Oophorectomy is rarely required.

- Even for an ovary with concern for gross necrosis, there are no known risks to leaving the ovary in situ, and these ovaries may still be functional.

### Salpingectomy may be considered.

- In contrast to preservation of an ovary with concern for gross necrosis, there may be risks to leaving an extensively damaged fallopian tube in situ (ectopic pregnancy, decreased fertility); removal of a fallopian tube involved in torsion is considered on a case-by-case basis.

### Paratubal cyst torsion

- More common in pediatric/adolescent populations but can occur any age
- If ovary not involved in torsion, it may look normal on imaging.
- Drainage without cystectomy risks recurrence

### Consider delaying cystectomy.

- May be the only finding in patients without an adnexal mass
- Cystectomy at the time of detorsion is ideal.
- If surgical planes are compromised due to tissue hemorrhage/edema during acute torsion, consider detorsion alone, followed by imaging/return for second surgery if needed, rather than unnecessary oophorectomy.
- Consider surgical risks/candidacy/benefits of ovarian preservation (may differ if patient is age 45 years vs 15 years)

recommended that all providers keep torsion high on their differential. ■

**FOR REFERENCES VISIT**  
[contemporaryobgyn.net/ovarian-torsion](http://contemporaryobgyn.net/ovarian-torsion)