


DENTISTRY



By Jan Bellows
DVM, dipl. AVDC, dipl. ABVP

Dr. Bellows owns Hometown Animal Hospital and Dental Clinic in Weston, Fla. He is a diplomate of the American Veterinary Dental College and the American Board of Veterinary Practitioners. He can be reached at (954) 349-5800, or e-mail: dentalvet@aol.com.

Base dental decisions on proven successes

One of the biggest stumbling blocks for veterinarians expanding dentistry services is the seemingly overwhelming amount of disease and the options for care. Many throw up their hands in frustration. As with other veterinary disciplines, dental diagnosis and care is one-third recognition of disease, one-third understanding dental anatomy and medical principles, and one-third performing the care. Previous articles in *DVM Newsmagazine* covered diagnosing periodontal, endodontic and orthodontic problems. Future articles will cover therapy.

Below are general rules to incorporate into your dental practice. None of these rules are written in stone, only guidelines on what works in the majority of cases. Each animal is different, and delivery of care often is predicated by client/veterinarian/patient issues.

Periodontal disease

There are four recognized stages of periodontal disease, and each is treated differently.

■ Stage 1 appears as inflamed gingiva without evidence of support loss. Treat-

ment involves a thorough teeth cleaning and polishing (Figure 1).

■ Stage 2 indicates the early establishment of periodontal disease with less than 25 percent support loss. Treat as Stage 1 plus local application of antibiotics in areas of significant pocketing (Figures 3, 4).

■ Stage 3 periodontal disease is present when 25 to 50 percent support loss has occurred. When there is significant probing pocket depths present, an apical position flap can be used to decrease the pocket. If there are significant areas of gingival recession without pocket depths, then extraction or teeth cleaning plus stringent home care are options (Figures 5, 6, 7).

■ Stage 4 is diagnosed when greater than 50 percent support loss has occurred. Extraction is the treatment of choice in most cases. Flap exposure, apical position flap, bone implants and mucogingival surgery can be attempted in the right case with the right owners given a guarded prognosis (Figure 8).

Endodontics

There are four recognized classes of tooth fractures; treatment depends on age of the animal and age of the fracture.

Class 1 enamel defect usually requires no therapy other than crown restoration if the lesion does not extend into the dentin (Figure 9).

Class 2 near pulp-exposure fractures have entered the enamel and dentin approaching the pulp. Treatment depends primarily on the age of the animal — a young animal (less than 9 months of age) will have a large pulp chamber close to the dentin (Figures 10,11). Vital pulp therapy should be performed in these cases with frequent radiographic re-examination. The older animal with increased amount of dentin between the fracture and pulp either can have root-canal therapy performed or serial radiographs for signs of endodontic involvement before root canal or extraction (Figures 12, 13).

Class 3 pulp exposure carries the most options depending on presentation.

If the fracture is acute (up to two days in the young animal and two weeks in the animal older than 18 weeks) then vital pulp therapy can be attempted with a guarded prognosis. Extraction, or conventional root-canal therapy can be performed with a more-predictable outcome (Figure 14).

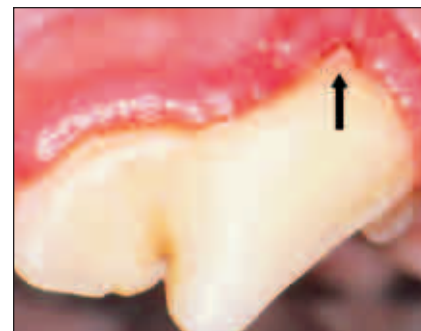

Figure 2: Stage 2 early periodontal disease. Arrows denote gingival recession.

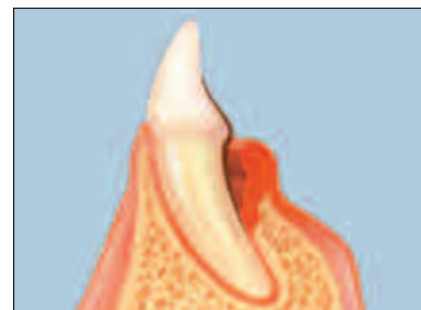

Figure 3: Note the significant periodontal pocket around the canine tooth.

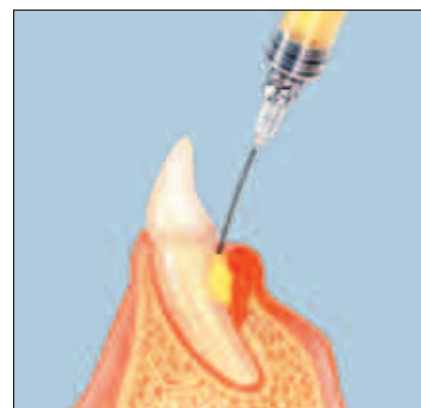


Figure 4: The pocket should be filled with antibiotic.

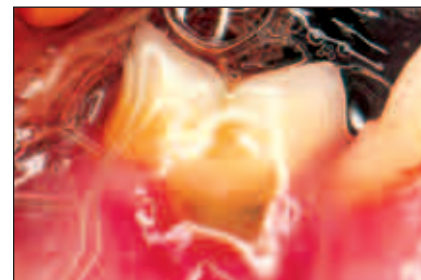

Figure 5: Stage 3 periodontal disease around a cat's mandibular molar.

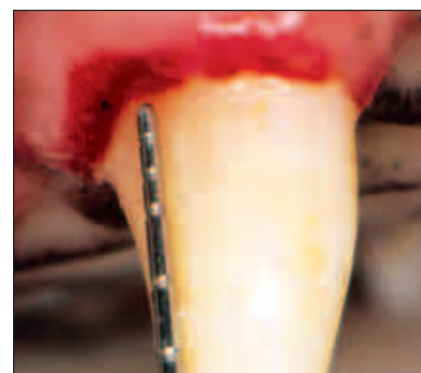

Figure 6: periodontal probe before insertion into a canine pocket.

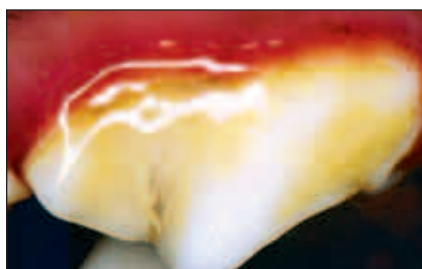


Figure 1: Stage 1 gingivitis affecting the canine maxillary fourth premolar.



If the fracture is older, then extraction, conventional or surgical root-canal therapy is the treatment of choice (Figure 15).

Patient age: If the animal is less than 9 months old, then vital pulp therapy can be performed in the non-infected tooth. In the infected tooth, apexification (the process of apical closure of the root by hard tissue deposition in a non-vital tooth by the action of cementoblasts and odontoblasts) is the desired outcome. If the animal is older than 9 months, and the apex is closed, then conventional or surgical root canal is the more-predictable procedure.

Class 4 root fracture usually is not treated if the fracture is near the apex; if it is closer to the crown, then the tooth is generally extracted.

Discolored tooth (pulpitis) occurs secondary to significant trauma and pulp death. Root-canal therapy or extraction is indicated (Figure 16).

Feline resorptive lesions

There are five recognized stages of resorptive lesions, from cementum-only lesions to significant loss of the crown. For predictable long-term results, treatment is the same for all stages, e.g. extract the effected teeth after radiographs (Figures 17, 18).

Orthodontics: tooth number and position

Does the patient have too many or too few teeth? In the normal, mature dog, there should be 42 teeth. The cat should have 30. Six incisors should exist for the dog between the maxillary and mandibular canines (Figures 19, 20). Between the maxillary canine and fourth premolars, there should be three teeth (first, second and third premolars), and between the mandibular canine and first molar, there should be four teeth (first through fourth premolars).

Any more or fewer teeth need radiographic evaluation for either extraction, operculectomy (removal of the hood above the impacted tooth), or no therapy if the tooth is absent (Figures 21, 22).

All persistent primary (deciduous) teeth should be removed at the time of diagnosis to prevent abnormal location of the adult teeth (Figure 23).

Interfering teeth should be moved, extracted or crown reduced. (Figure 24). ■

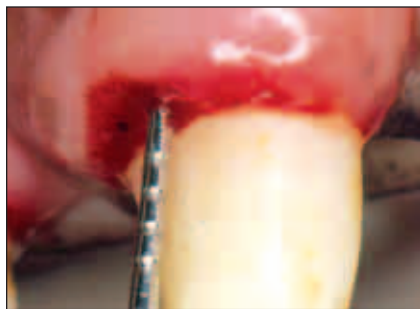


Figure 7: 6 mm probing depth means Stage 3 periodontal disease.

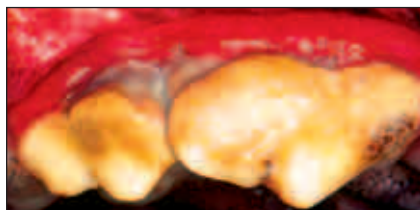


Figure 8: Stage 4 periodontal disease of the maxillary fourth premolar in a dog.

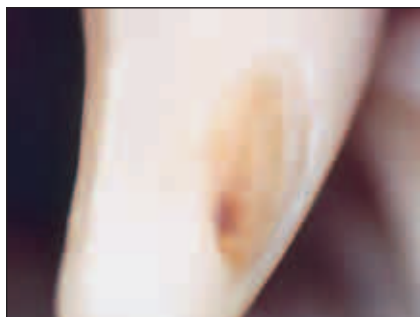


Figure 9: Class 1 enamel-only fracture.

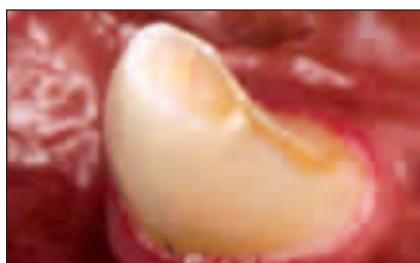

Figure 10: Class 2 near-pulp exposure in an immature tooth.

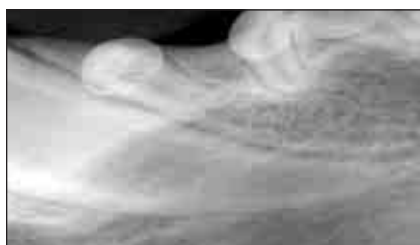

Figure 11: Radiograph showing the thin dentin and large root canal.

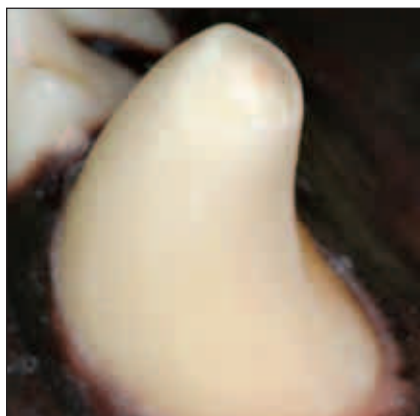

Figure 12: Class 2 fracture in a mature canine tooth.

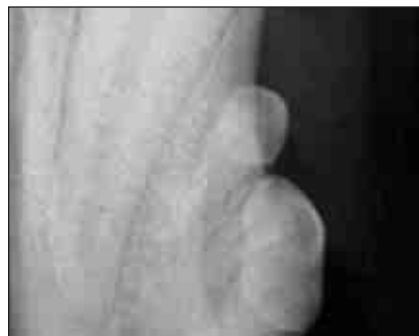

Figure 13: Smaller pulp cavity compared to Figure 11.

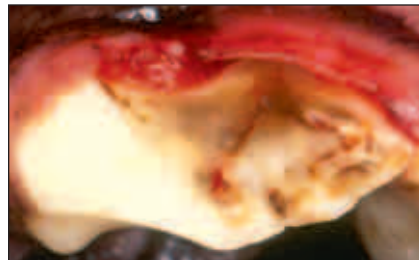


Figure 14: Class 3 pulp exposure of an acute slab fracture.

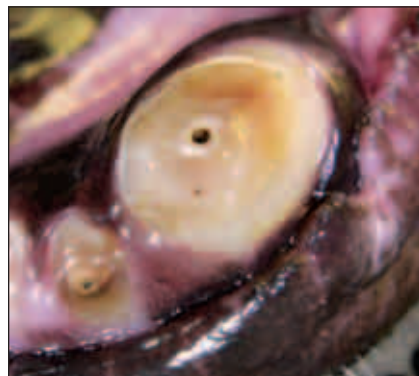

Figure 15: Exposed pulp in a chronically fractured canine.

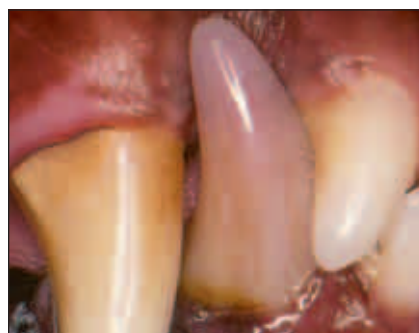

Figure 16: root fracture.

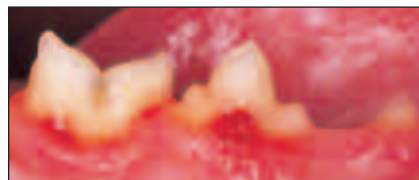

Figure 17: Feline mandibular third, fourth and first molar effected by resorptive lesions.

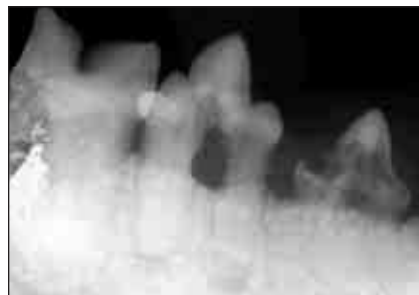

Figure 18: Radiograph confirming resorptions.

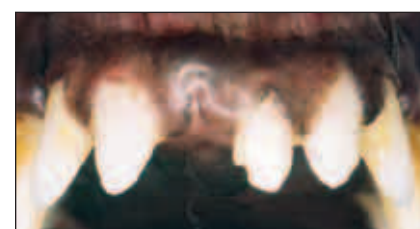

Figure 19: Clinically missing maxillary right central incisor.

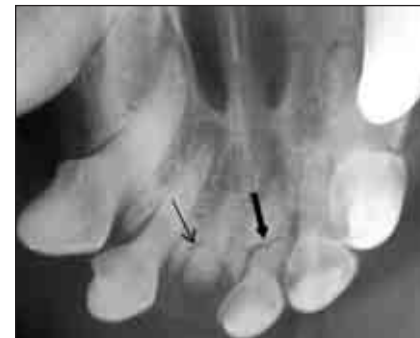

Figure 20: Radiograph showing missing crown of right maxillary central incisor and fractured root in left maxillary central incisor.

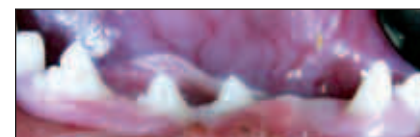


Figure 21: Clinically missing right mandibular first premolar.

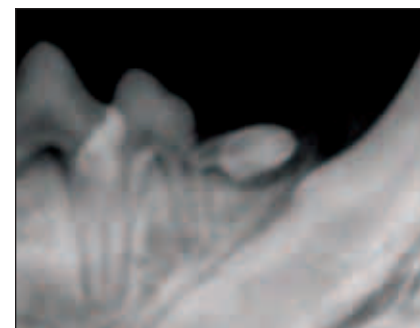

Figure 22: Horizontally deviated right maxillary first premolar.

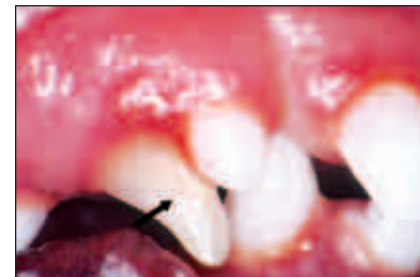

Figure 23: Persistent primary first premolar.

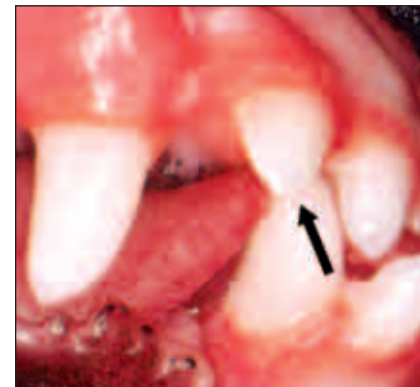


Figure 24: Interference between the mandibular canine and lateral incisor.