



Viewpoint

By Jan Bellows, DVM, DAVDC, DABVP



The IDEXX National Oral Disease and Retrovirus Prevalence study demonstrates a correlation between clinical signs

of oral disease and positive retrovirus status as determined by an in-house test. In the study, one-seventh of cats affected with gingivitis and one-fourth of those

with stomatitis were retrovirus-positive. These results have important clinical implications.

Illness in retrovirus-infected cats is often secondary disease

due to immunosuppression rather than a direct effect of retrovirus infection. Previous studies have shown that neither FeLV nor FIV causes gingivitis, stomatitis, or feline oral resorption lesions.¹ However, the IDEXX study implies that a significant number of cats affected by retroviruses present to veterinarians with clinical signs of oral disease. Interestingly, oral disease in people has been cited as an early indicator of HIV infection.

One direct clinical implication of this study is that all cats with unknown retroviral status presenting with oral disease should be tested for FeLV and FIV infection.

Not only does a diagnosis help practitioners formulate the best treatment plan, it also allows them to communicate essential information to clients about their pet's prognosis.

Dental procedures involve saliva and blood, and both FeLV and FIV are transmitted through these fluids. Dental instruments and endotracheal tubes should be thoroughly cleaned and sterilized between uses, and disposable prophylaxis angles should be used to avoid cross-contamination.

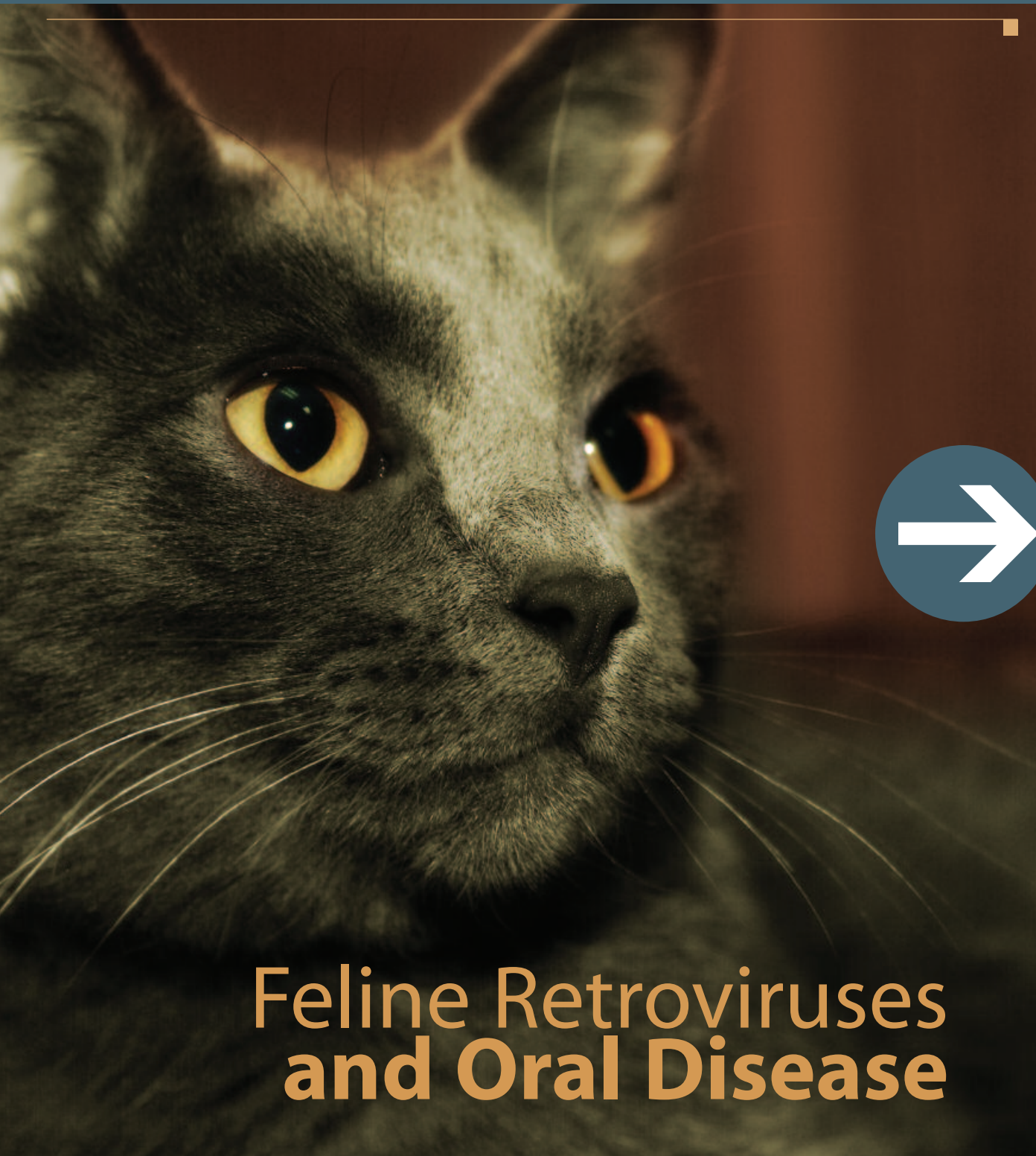Perioperative antibiotic administration may be appropriate for retrovirus-infected cats undergoing dental procedures, while corticosteroids should not be used to manage stomatitis. Cats with stomatitis and FIV may benefit from a short course (three weeks) of zidovudine (5 mg/kg orally twice daily). However, this agent can cause bone marrow suppression, particularly with long-term use, so complete blood cell counts should be monitored closely. Bovine lactoferrin (350 mg applied topically or mixed with milk or a small amount of food) may also improve oral health in retrovirus-infected cats.

If a cat has oral disease, determining its retrovirus status can help you make appropriate treatment decisions and improve the patient's long-term quality of life. I look forward to further research in this area.

1. Harvey CE, Emily PP. *Small Animal Dentistry*. St. Louis, Mo: Mosby, 1993;151.

All cats with unknown retroviral status presenting with oral disease should be tested for FeLV and FIV infection.

spotlight on research



Feline Retroviruses and Oral Disease

Sponsored by
an educational
grant from

IDEXX
LABORATORIES



Feline Retroviruses and Oral Disease

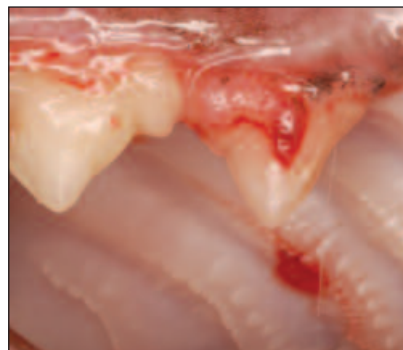A clear association

A new study demonstrates a correlation between feline oral health problems and retroviral infection. The IDEXX National Oral Disease and Retrovirus Prevalence study clearly illustrates that cats with oral disease have an increased risk of being retrovirus-positive.

The veterinary scientific literature has suggested a correlation between oral diseases and feline retroviral infections; however, for many years no large-population study had ever been conducted. From its interaction with veterinarians, IDEXX suspected that feline oral disease patients were not being appropriately considered as high-risk for being retrovirus-positive. So the company undertook a nationwide study to examine this issue in greater detail.

What the research means for veterinarians

The study found a significant correlation between feline retrovirus infection and oral disease. Based on these results, practitioners should begin to incorporate retrovirus testing into their oral health protocols—specifically, testing cats for feline leukemia virus (FeLV) and feline immuno-



A feline odontoclastic resorption lesion (FORL).

deficiency virus (FIV) infection before dental procedures. What's more, retrovirus infection critically affects patients' overall health, so testing this higher-risk population can provide valuable information regarding long-term care.

To ensure cats' safety, veterinarians must answer the question of whether their feline oral disease patients are retrovirus-positive. And the only way to find this out is through retrovirus testing.



Key Points

- Cats with oral disease are more than twice as likely to test positive for retrovirus infection as the general cat population.
- Knowing a cat's retrovirus status has important implications for dental care and overall health.
- All cats with oral disease should be tested for FIV and FeLV infection.

Common Feline Oral Diseases

- **Gingivitis:** Gingival inflammation, edema, and bleeding on probing.
- **Periodontitis:** Inflammation of the periodontal ligament, alveolar bone, and cementum.
- **Feline odontoclastic resorption lesion (FORL):** A tooth defect usually located at the labial or buccal surface near the cemento-enamel junction.
- **Stomatitis:** Signs include glossitis, gingivitis, periodontitis, dysphagia, weight loss, and ptyalism.

Oral Disease and Retrovirus Prevalence: A Study by IDEXX

Purpose

A study was conducted to determine the prevalence of retrovirus infection in feline oral disease patients.

Methodology

- Private veterinary practitioners were recruited to test feline patients that presented with oral disease.
- The IDEXX SNAP FIV/FelV Combo Test was used to test this cat population from January 2006 through April 2006.
- Results were returned by fax for analysis.
- Prevalence was calculated as the percentage of positive test results reported out of the population of orally diseased cats tested.

Results

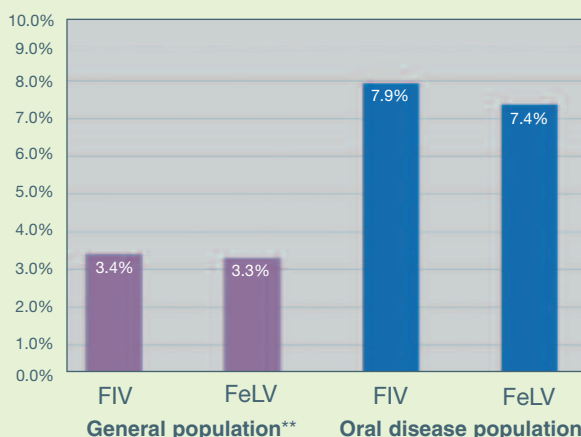
- A total of 8,982 orally diseased cats were screened. Presenting cases included cats with gingivitis, stomatitis, plaque, calculus, periodontal disease, feline odontoclastic resorption lesions, and other oral diseases as defined by the practitioner.
- Of 8,982 cats tested, 1,276 were retrovirus positive—a prevalence of 14.2% (Figure 1).
- Of the 7,809 study cats with gingivitis, 1,113 were retrovirus-positive. Of the 1,954 with stomatitis, 467 were retrovirus-positive (Figure 2). Some cats had both gingivitis and stomatitis.

Discussion

Recent studies have reported the prevalence of FeLV nationwide as 3.3% and the prevalence of FIV as 3.4%.¹ In the IDEXX study, the higher prevalence of retroviral infection in orally diseased cats indicates that almost one of every seven cats with oral disease has a retroviral infection. This study suggests that screening cats with oral disease for retroviral infection is important in understanding the underlying cause of this clinical presentation.

Figure 1
Oral Disease and Retrovirus Infection

In a nationwide study, 14.2% of cats with oral disease tested positive for retrovirus infection: FIV infection, FeLV infection, or both.* Here's a breakdown of FIV and FeLV infection rates compared with national prevalence.

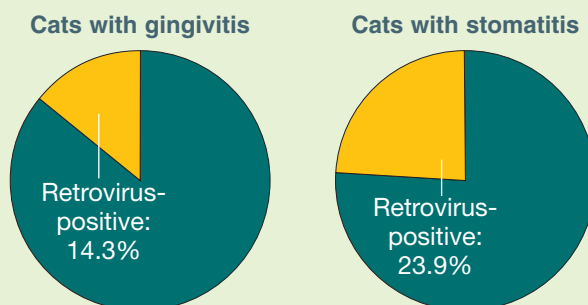


*A dual retrovirus-positive test was counted once—i.e., an FIV- and FeLV-infected cat was considered one retrovirus-positive cat, not two.

**Source: Levy JK, Crawford PC, Brien JL. Prevalence of FIV and FeLV in the United States, in *Proceedings. 7th Int Feline Retrovirus Res Symp*, 2004.

Figure 2
Gingivitis, Stomatitis, and Retrovirus Infection

The study also examined the correlation between specific oral diseases and retrovirus infection.



1. Levy JK, Crawford PC, Brien JL. Prevalence of FIV and FeLV in the United States, in *Proceedings. 7th Int Feline Retrovirus Res Symp*, 2004.