

To Grid or Not to Grid... Corneal Ulcers and Other Confusing Corneal Conditions

Mark Bobofchak, DVM, DACVO
Eye Care for Animals
Akron, OH

To Grid or Not to Grid... (Corneal Ulcers and other confusing corneal conditions)

Mark Bobofchak,
DACVO Eye Care for
Animals Akron, OH

1

Topics

- Ulcers
 - Indolent
 - Stromal
 - Descemetocoeles
 - Perforations
- Lacerations
- Autoimmune
- Dystrophy
- Degeneration
- Endothelial decompensation
- Corneal Sequestrum

2

Indolent ulcers

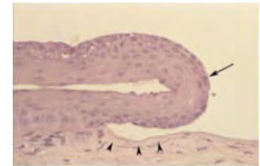
- “Boxer Ulcer”, Non-Healing Ulcer, SCCED, REE
- Older Dogs
 - > 6 years old
- Typical history
 - Progressive “redness”
 - Cloudiness
 - Intermittent blepharospasm
 - Good days and baddays
 - Often no known trauma



3

Indolent Ulcers

- Failure of epithelial-stromal adhesion complex formation
 - NOT BM dystrophy
 - Older dogs
 - Normal BM in unaffected cornea
- Loss of BM
 - Normally cannot manually debride
 - Delays wound healing
- Stromal changes
 - Superficial acellular hyalinized zone
 - Barrier to adhesion complex



IHC for laminin

4

Indolent

Medical Options

- **Topical antibiotics**
 - Epithelial cell toxicity?
- Serum?
- Remend?
- EDTA
- Chondroitin Sulfate
- Cyanoacrylate
- Substance P
- PSGAGs
- MMP inhibitors?
 - Doxycycline

Surgical Options

- Debridement
 - Cotton Swab vs. Blade
- Linear Grid Keratotomy
- Diamond Burr Debridement
- Multifocal Superficial Punctate Keratotomy
- CO2 Laser Keratotomy
- Thermokeratoplasty
- Keratectomy

5

Success Rates

- 80-90% heal within 2 weeks with DBD or LGK
- < 50% heal rate for swab debridement
- Near 100% heal with keratectomy, but rarely necessary

- Continue topical antibiotics 2-3 X daily and oral pain medication (NSAID or Tramadol)
- E-Collar and Warm compresses

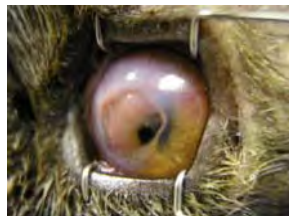- *Red and Blue is good for you, Yellow or Green needs to be seen*

6

Stromal

- Increased proteolytic enzymes
 - MMP 2 and 9
 - Inflammatory cells
 - Epithelial cells
 - Fibroblasts
 - Bacteria
- Often rapidly progressive
- Varying degree of pain
 - Breed

TREAT AGGRESSIVELY

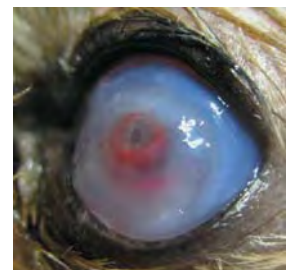

Size
Depth
Location
Corneal consistency
Vascularization?

7

Stromal Ulcers

- **Treatment Options**
 - Medical management
 - Temporary Tarsorrhaphy
 - Third Eyelid Flap
 - Conjunctival Pedicle Graft
 - Corneoconjunctival Transposition
 - Amniotic membrane / PSIS graft
 - Frozen Cornea Graft
 - Corneal Collagen Crosslinking with Riboflavin



8

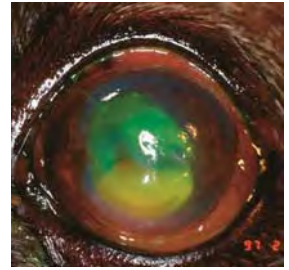
Medical Management

- Culture/Sensitivity and Cytology
- Antibiotics
 - Ideally based on c/s – Not always practical
 - Gram stain
 - Drops preferable to ointments
 - Frequent dosing initially (q 1-2 hrs for several days)
- Mydriatic (Atropine)
 - Pain control by reducing ciliary spasm
 - Prevents synechia
 - Caution with KCS patients

9

Medical Management

- Antiprotease/Anticollagenase
 - *Serum*
 - *EDTA*
 - *Doxycycline*
 - N-acetyl-cysteine
 - Ilomostat (Galardin)
- Frequent dosing (q 1-2 hours initially then decrease)
- Systemic pain control
 - Tramadol
 - NSAID



10

Medical Management

- E-collar
 - IMPORTANT
- Exercise restriction
- Warm compresses
 - NOT for descemetoceles!!
- Frequent rechecks until cornea is stabilized and stromal thickness is improving

11

Medical

Benefits

- Cheap
- No anesthesia
- May have reduced scar

Risks

- May progress to perforation
- Frequent drops
- Dependent on owner compliance
- Variable time to healing

12

Surgical options

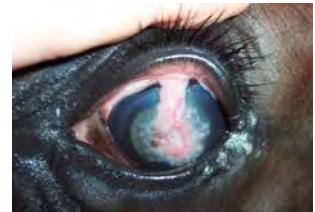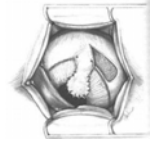
- Temporary Tarsorrhaphy
- Third Eyelid Flap
 - Protect cornea during healing
 - Liken to bandaging an open wound
 - Not directly fixing the defect
 - Treat as for medical management

13

Surgical Options

Conjunctival Pedicle Graft

- Effective technique
- Immediate tectonic support and blood supply
- Often leaves large scar
- Ideal for large, peripheral, or malacic ulcers



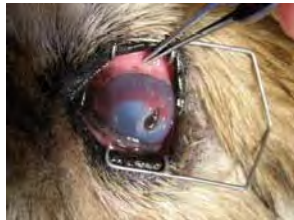14

Surgical Options

Corneoconjunctival Transposition

- Clear cornea into defect
- Thicker than CPG
- Conjunctiva adhered to peripheral cornea
- No immediate blood supply

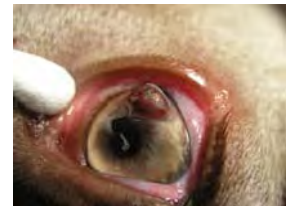Ideal for non-malacic, central corneal defects



15

Perforations

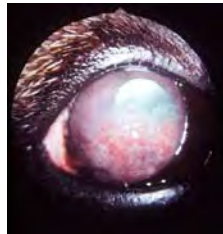
- Immediate surgery recommended
- Iris Prolapse into wound
 - Affects prognosis and difficulty of surgery
- If traumatic, evaluate for intraocular damage
 - Ruptured lens capsule
 - Retinal Detachment
- Surgical options
 - Direct suturing if laceration
 - Corneal or conjunctival graft



16

Autoimmune Disease

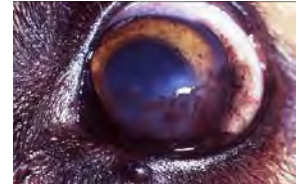
- Pannus (CSK)
 - German Shepherds
 - Grayhounds
- Progressive vascularization and pigment
- Ventrolateral limbus
- Third eyelid
- Mineral degeneration



17

Autoimmune Disease

- Pannus
 - Vascular ingrowth and CD4+ lymphocytes into anterior stroma
 - Epithelium unaffected
 - Cause unknown
 - UV exacerbates
- **Chronic** topical steroids or CSA/Tacrolimus



18

Autoimmune Disease

- Superficial Punctate Keratitis
 - *Dachshund*, Shetland
 - Multiple punctate opacities
 - +/- ulcers
- CSA/Tacrolimus
- Corticosteroids

19

Autoimmune Disease

- Eosinophilic Keratitis (cats)
 - Progressive stromal vascularization
 - Multiple superficial white plaques
 - Fluorescein adheres to white plaques
 - Typically non-painful
 - Multiple eosinophils / plasma cells on cytology
- Treatment
 - Topical +/- systemic steroids
 - Megestrol acetate as last resort
 - FHV management ???

20


Corneal Dystrophy

- Hereditary central corneal mineral deposits
- Cholesterol
- Often bilateral and symmetrical
- Not painful
- No vision impairment unless advanced

- No response to topical tx
- CBC/Chemistry to r/o metabolic disease
- Keratectomy as last resort

21

Corneal Dystrophy



Typical Breeds

- Beagles, Siberian Husky, Cavalier, Collie, Shetland Sheepdog, Airedale

22

Lipid Keratopathy

- Dense corneal crystallization due to systemic lipid disease
 - Hypothyroidism
 - Diabetes mellitus
 - Pancreatitis
 - Hyperlipoproteinemia
 - Postprandial plasma lipid elevation
- Unilateral or bilateral
- Avascular early
- Treatment
 - ID and treat underlying cause
 - Topical anti-inflammatories may worsen
 - Keratectomy as last resort



23

Corneal Degeneration


- Crystalline opacities due to corneal injury or disease
- Lipids, cholesterol, or calcium
- **Corneal vascularization**
- May ulcerate
 - Stromal ulcers may develop as crystals slough in older dogs
- ID and treat underlying condition
 - Avoid topical steroids
 - 1% EDTA may help with calcium degeneration
 - Keratectomy if severe

24

Endothelial

- **Dystrophy**
 - Hereditary
 - Boston Terrier
 - Chihuahua
 - Dachshund
 - Starts temporal
 - Progresses to entire cornea
 - Non-painful and typically visual
- **Degeneration**
 - Progressive edema
 - Predisposing condition
 - Uveitis
 - Lens luxation
 - Anterior iris synechiae
 - Variable pattern

25



- **Clinical signs**
 - Corneal edema only
 - Normal PLR
 - Lack of scleral injection, blepharospasm, or vision deficits

26

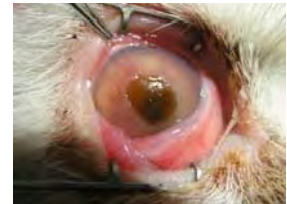Endothelial Disease

- **Treatment**
 - Treat underlying condition (degeneration only)
 - Topical 5% sodium chloride
 - Will not clear edema or stop progression
 - Decrease chance of recurrent ulceration due to bullae formation
 - Topical steroids
 - If underlying uveitis suspected
 - Thermokeratoplasty or Laser Keratoplasty

27

Corneal Sequestrum

- Unique to cats and horses
- Chronic corneal irritation
 - FHV
 - Entropion
 - Chronic ulcer
 - Iatrogenic (LGK)
- Persian, Colorpoint
- Melanin and degenerate corneal collagen
- Variable vascularization and discomfort

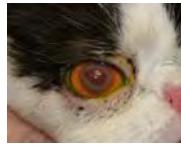
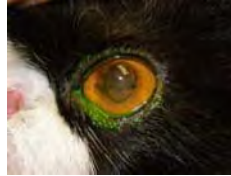
28

Corneal Sequestrum

Treatment options

- Medical management
 - Sloughing of plaque
 - Timing unknown
 - Discomfort
 - Risk of perforation
- Keratectomy
 - Preferred
 - Controlled removal
 - Graft placement if necessary
 - Good visual outcome



29

*Thank you for your time and
attention!!*

Questions??