

*OncLive*<sup>®</sup>

BASAL CELL CARCINOMA

MAY 23, 2022

VIRTUAL WORKSHOP

# SCIENTIFIC INTERCHANGE & WORKSHOP

## Multidisciplinary Management of Patients With **Basal Cell Carcinoma**

A 3D anatomical model of the skin layers, showing the epidermis, dermis, and subcutaneous tissue. A central, raised, nodular lesion representing a basal cell carcinoma is visible. The model is overlaid with a network of white and blue lines, circles, and dashed lines, suggesting a multidisciplinary or scientific approach to the management of the condition.

## EDITORIAL & PRODUCTION

**Vice President,  
Clinical Communications**  
Angelia Szwed, MS

**Director of Scientific  
Services, Oncology**  
Darrja Zangari, PharmD,  
BCPS, BCGP

**Director, Promotional  
Project Management**  
Lindsay McCay

**Medical Writer**  
Jason Lewis, PharmD

**Associate Editor**  
Thomas Kluxen, MA

**Assistant Editor**  
Jason Wright

**Vice President, Copy**  
Jennifer Potash

**Copy Chief**  
Paul Silverman

**Copy Supervisor**  
Nicole Lupo

**Medical & Scientific  
Quality Review Editor**  
Stacey Abels, PhD

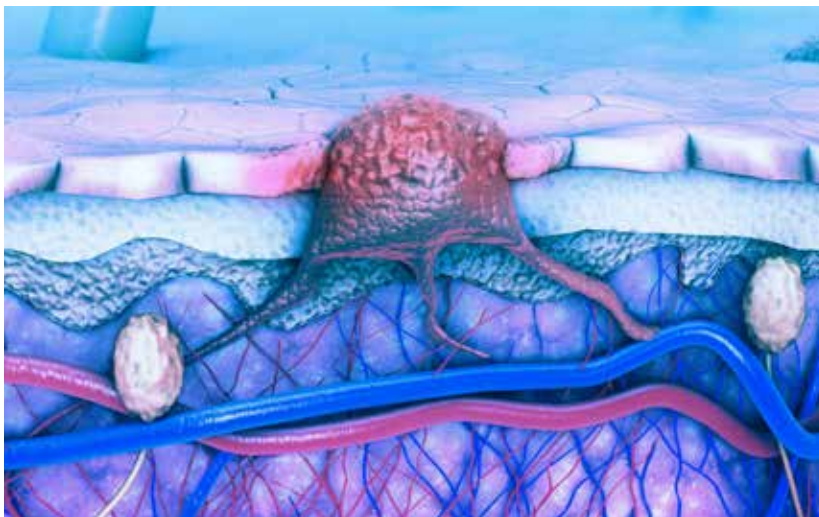
**Senior Copy Editors**  
Marie-Louise Best  
Cheney Baltz  
Kelly King

**Copy Editors**  
Georgina Carson  
Kirsty Mackay  
Justin Mancini  
Ron Panarotti  
Mercedes Perez  
Yasmeen Qahwash

**Creative Director,  
Publishing**  
Melissa Feinen

**Senior Graphic Designer**  
Kellie Ehrmann

## BCC



## GLOBAL AMBASSADOR STRATEGIES

**Executive Vice President,  
Global Ambassador  
Strategies**  
Donna Short, MA

**Executive Director,  
Global Ambassador  
Strategies—Oncology**  
Steven Frommeyer

**Executive Director,  
Global Ambassador  
Strategies—Oncology**  
Sharyn Foster, RPh, MBA

**Strategic Alliance  
Partnership Manager**  
Noelle Stango

## ONLIVE® MEDICAL

**Vice President,  
OnLive® Medical**  
Lisa Greene, BS, RN

**Business Development  
Associate, OnLive® Medical**  
Alyssa Tomaseck

## SALES & MARKETING

**Vice President, Sales,  
MJH Life Sciences®**  
Robert Goldsmith

**Vice President & Executive  
Producer, MJH Productions**  
David Lepping

**Senior Director, Sales**  
Albert Tierney

**Associate Directors, Sales**  
Phil Conover  
Morgan Michon

**National Accounts  
Associates**  
Mike DiGrazia  
Shane Marchesani

## OPERATIONS & FINANCE

**Circulation Director**  
Jon Severn

**Vice President, Finance**  
Leah Babitz, CPA  
**Controller**  
Katherine Wycoff

## CORPORATE

**President & CEO**  
Mike Hennessy Jr

**Chief Financial Officer**  
Neil Glasser, CPA/CFE

**Chief Operating Officer**  
Michael Ball

**Chief Marketing Officer**  
Brett Melillo

**Executive Vice President,  
Global Medical Affairs &  
Corporate Development**  
Joe Petroziello

**Senior Vice President,  
Content**  
Silas Inman

**Vice President,  
Human Resources  
& Administration**  
Shari Lundenberg

**Vice President,  
Mergers & Acquisitions**  
Chris Hennessy

**Executive Creative  
Director, Creative Services**  
Jeff Brown

## KEY TAKEAWAYS

- ▶ Surgical treatment options are the preferred approach for most cases of basal cell carcinoma (BCC). For patients with advanced disease (locally advanced and metastatic BCC [mBCC]), systemic treatment options and investigational strategies continue to reshape the future treatment landscape as they become available.
- ▶ Because locally advanced BCC is not well established within current guidelines, definitions may vary across practice sites. Histological subtype, tumor size and location, patient preference, and other relevant clinical factors are used to guide treatment decisions.
- ▶ A multidisciplinary treatment approach can be helpful in guiding therapy, managing treatment-related adverse events (AEs), and providing support for social aspects of therapy. Strategies involving multidisciplinary teams are recommended for patients with advanced BCC; members of these teams may include involve surgical oncologists, radiation oncologists, medical oncologists, dermatologists, nutrition specialists, and social work professionals.
- ▶ Most patients will experience an AE with Hedgehog inhibitor (HHI) therapy, but HHI intolerance is a significant treatment barrier that can lead to treatment interruptions and discontinuations. Resistance to HHIs and disease progression following HHI therapy can occur in some patients. Collectively, these highlight the need for alternative treatment options for patients with BCC.
- ▶ Immune checkpoint inhibitors (ICIs) offer an alternative systemic treatment approach for advanced BCC that can address needs unmet with use of HHIs. Cemiplimab is an FDA-approved treatment indicated for patients with locally advanced BCC or mBCC who have received an HHI or for whom an HHI is not appropriate, with the indication for mBCC granted through accelerated approval.
- ▶ ICIs are better tolerated than HHIs, which may help alleviate challenges associated with treatment adherence and improve quality of life. ICIs have demonstrated durable responses that may deepen over time; however, overall responses observed in patients with BCC are lower relative to those seen in patients with squamous cell carcinoma (SCC). Future investigation is needed regarding these observed differences to develop strategies to improve and better predict patient response.

FOUNDER  
Mike Hennessy Sr  
1960-2021



MJH Life Sciences, LLC | 2 Clarke Dr. | Suite 100  
Cranbury, NJ 08512 | (609) 716-7777

AN **MJH** life sciences® BRAND

# Multidisciplinary Management of Patients With Basal Cell Carcinoma

## INTRODUCTION

On May 23, 2022, *Onclive*<sup>®</sup> brought together a select group of physicians who specialize in the treatment of BCC to participate in a virtual workshop to discuss the treatment landscape and management of patients with locally advanced and mBCC. The goals of the interchange were to review and discuss current treatment patterns, evaluate existing treatment strategies and key findings from clinical trials, identify factors that influence clinical decision-making, and discuss opportunities for the development of novel therapies for this patient population.

## ADVANCED BCC TREATMENT LANDSCAPE

Nonmelanoma skin cancers, such as BCC and SCC, are the most commonly occurring cancers in the United States, with an estimated 5.4 million new cases diagnosed annually. BCC accounts for 80% of all new nonmelanoma skin cancers cases each year.<sup>1-3</sup> The majority of BCC cases can be cured using local therapy either alone or with a combination of approaches, including surgical excision, radiation therapy (RT), topical agents, and photodynamic therapy.<sup>4-6</sup>

There are limited treatment options available for advanced BCC. Approximately 20,000 BCC cases progress to an advanced stage of disease (locally advanced and metastatic) each year. There are inconsistent criteria for diagnosis and classification of locally advanced tumors, which adds complexity to the management of these BCC cases.<sup>4,7</sup>

Tumor location, size, and histological subtype are important factors used to classify and guide treatment of advanced BCC.<sup>8</sup> Over 26 subtypes of BCC have been reported in the

literature; however, certain histological subtypes (eg, morpheaform carcinoma, basosquamous carcinoma, and infiltrative carcinoma) are more aggressive and are more likely to progress to locally advanced stages.<sup>9,10</sup> Additionally, perineural invasion occurs more frequently with aggressive BCC subtypes; it is also associated with increased rates of morbidity and recurrence.<sup>11,12</sup>

Surgery and RT strategies can be limited in certain patient populations. Approximately 80% of advanced BCCs occur in regions of the head and neck. Patients with tumors in these loci or other cosmetically sensitive regions may be at an increased risk of deformities or loss of function.<sup>4</sup> Furthermore, patients with comorbid conditions (eg, Gorlin syndrome) can develop thousands of lesions, which may reduce the feasibility of surgical treatment options. RT also can induce new tumors in patients with Gorlin syndrome, which has led physicians to seek alternative treatment approaches for these patients.<sup>13</sup>

### STAKEHOLDER INSIGHTS

The definition of locally advanced BCC can vary among physicians and across oncology practice settings, which can cause challenges with communication between members of the oncology care team. Panelists shared that National Comprehensive Cancer Network guidelines do not provide a clear definition of locally advanced BCC. The availability of emerging targeted and immunotherapy options has influenced the categorization of locally advanced BCC. The European Association of

Dermato-Oncology guidelines provide recommendations for the treatment of BCC and stratify advanced BCC into categories on a scale of 1 to 5 (based on “treatability” of the tumors), which can be helpful for communication between providers. Experts on the panel highlighted the importance of engaging in shared treatment decision-making with patients and discussing all available options. Clinicians noted that patients can provide helpful insights that are used to guide treatment in cases in which tumors may not meet locally advanced tumor criteria or tumors are located in cosmetically sensitive regions.

## A MULTIDISCIPLINARY APPROACH TO BCC MANAGEMENT

The majority of BCC cases can be effectively managed by dermatologists, although a multidisciplinary approach is recommended for patients with advanced disease, including patients with locally advanced BCC or mBCC, and those who are ineligible for surgery or who have narrow histological clearance margins.<sup>8,14</sup> As part of the multidisciplinary approach, input from surgeons, radiation and medical oncologists, dermatologists, clinical trial coordinators, and other specialists is recommended.

### STAKEHOLDER INSIGHTS

In general, the 3 primary pillars of the multidisciplinary team across most practice sites remain medical oncology, surgical oncology, and radiation oncology. Although the level

of dermatologist involvement varies across sites of care, most panelists expressed greater dermatologist engagement when treating patients who have low-risk disease, who are in early treatment stages, or who are having long-term follow-up care. Additionally, the faculty noted that collaboration with other specialists, such as Mohs surgeons and head and neck surgeons, depends upon the patient's needs and the selected treatment strategy.

### ***Surgical Treatment Approaches***

Surgical approaches (eg, excision, curettage and electrodesiccation [C&E], and Mohs micrographic surgery) remain the mainstay of BCC treatment, with preference for surgical technique based upon the assessed risk of tumor recurrence.<sup>8,9</sup> A clearance margin (defined as the area of unaffected skin surrounding the tumor) of at least 4 mm is recommended for standard excision or C&E of most primary lesions. Narrow margins (< 4 mm) may be necessary in cases involving anatomic or cosmetic constraints; wide margins (6 mm) are preferred for treatment of recurrent tumors.<sup>8,15</sup>

C&E and standard excision (using 4-mm margins) are recommended for tumors associated with a low risk of recurrence. Standard excision is typically preferred over C&E in clinical scenarios involving cosmetically sensitive areas, partially due to the longer healing times and inferior cosmetic outcomes associated with C&E.<sup>8</sup>

Mohs micrographic surgery should be considered for patients with high-risk BCC and in clinical scenarios where tumor margins may be difficult to define. Compared with standard excision, Mohs micrographic surgery is associated with lower rates of 10-year recurrence, better tissue preservation, and smaller surgical defects.<sup>8,16-18</sup>

### **STAKEHOLDER INSIGHTS**

There was consensus among faculty members that C&E is best reserved for small (< 2 cm), superficial basal cells or superficially invasive, low-risk basal cells; it should be avoided in tumors with a high-risk histology (eg, morpheaform or infiltrative) where a complete margin assessment is needed. Standard excision with postoperative margin assessment is most appropriate for low- to moderate-risk BCC, where tumors may be slightly larger and deeper. Additionally, standard excision is a preferred treatment approach for tumors located in areas having sufficient tissue for 4-mm safety margins and for which excision may be completed using standard linear closure.

Because postoperative histology is reported to be different in roughly 25% or more of Mohs surgical cases, 1 participant remarked that tumor location is a major driver for treatment selection. Mohs micrographic surgical options were noted to be best reserved for high-risk tumors located in a high-risk region (eg, the mask areas of the face) or tumors with a high-risk histology. Faculty further highlighted that histological subtypes that appear to be low-risk upon initial biopsy may be deemed to be much more aggressive following a complete margin assessment.

### ***Nonsurgical Localized Therapy Approaches***

In clinical scenarios involving low-risk tumors where surgical therapy is not feasible, is contraindicated, or is not preferred by the patient, nonsurgical localized therapies are also viable treatment options.<sup>8</sup> Because nonsurgical treatments for BCC can be

administered easily in an office-based practice setting, dermatologists often serve a primary role in providing these therapeutic options.

Topical therapies most often used for superficial BCC include the immunomodulator imiquimod and the antimetabolite fluorouracil.<sup>8</sup> Photodynamic therapy is a noninvasive modality consisting of a 2-step treatment process in which a photosensitizer is applied topically and followed by 1 or more hours of incubation by light irradiation.<sup>8,18</sup> The subsequent reaction generates reactive oxygen species that preferentially target cancer cells and induce apoptosis or necrosis.<sup>18</sup>

Primary and adjuvant RT can also be effective treatment options for patients ineligible for surgical therapy and may include superficial RT, isotope-based brachytherapy, and external electron beam radiation.<sup>8</sup>

### **STAKEHOLDER INSIGHTS**

Faculty members agreed that imiquimod is typically the preferred first-line topical agent used for superficial low-risk tumors. It is selected particularly for younger patients (who have greater potential for cosmetic sensitivity with surgical approaches) or for older patients with numerous lesions (who may prefer to avoid resection). Emerging data evaluating the use of other topical agents, such as topical fluorouracil, in patients with BCC and topical sirolimus in patients with Gorlin syndrome is promising and may be considered treatment decisions for these patient populations are made.

The use of RT varies across practice sites and institutions and depends on the availability, level of engagement, and experience of the radiation oncologists on staff. At sites where radiation oncologists have greater

engagement in multidisciplinary boards, RT plays a larger role in the personalization of therapy, often being sequenced with neoadjuvant and surgical strategies. One faculty member added that adjuvant RT is routinely offered to patients with high-risk BCC involving extensive perineural invasion or large nerve involvement or when clear margins are not attainable postoperatively.

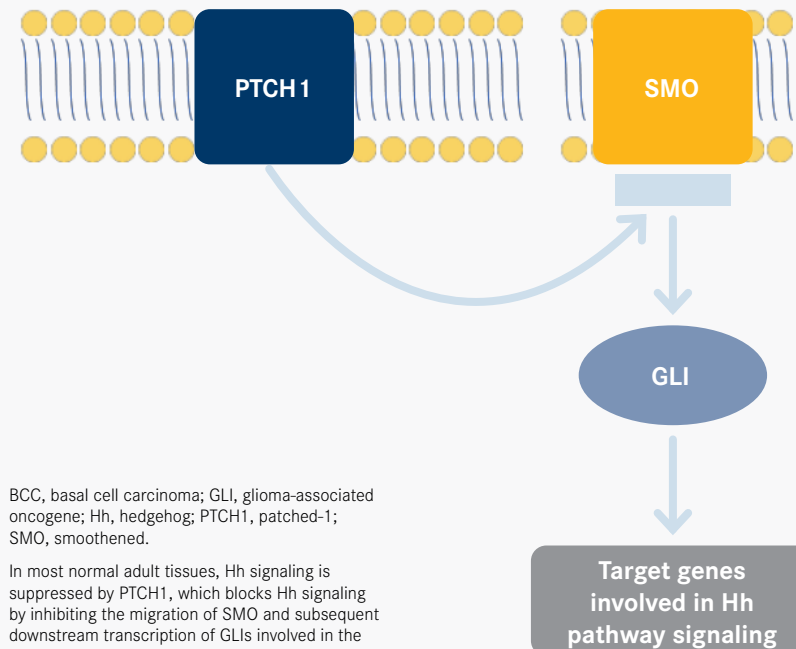
Overall, most practice sites reserve systemic agents for patients with high-risk basal tumors or those considered ineligible for surgery or RT. A multidisciplinary approach should be offered for patients receiving systemic treatment with HHIs, individuals being enrolled on clinical trials, or those receiving other treatment modalities.<sup>14</sup> The faculty members agreed that they often incorporate an HHI in preference to an anti-PD-1 agent in the neoadjuvant setting.

### SYSTEMIC THERAPY WITH HEDGEHOG PATHWAY INHIBITORS

The Hedgehog (Hh) signaling pathway plays a central role in normal embryonic development, and it is important in the maintenance and regulation of various tissues (FIGURE).<sup>7,19,20</sup> In most normal adult tissues, Hh signaling is suppressed by the patched-1 (PTCH1) protein, which blocks Hh signaling by inhibiting the migration of the smoothened (SMO) protein and subsequent downstream transcription of glioma-associated oncogene (GLI1) transcription factors involved in the transcription of Hh pathway target genes.<sup>7,19,20</sup> First described in patients with Gorlin syndrome, inappropriate reactivation of Hh signaling is a major driver of tumorigenesis.<sup>19</sup>

Abnormal activation of the Hh signaling pathway has been identified as a key contributing factor in the development of BCC. Approximately

**FIGURE.** SIMPLIFIED REPRESENTATION OF THE HH SIGNALING PATHWAY AND ITS ROLE IN BCC PATHOGENESIS<sup>7,19,20</sup>



80% to 90% of sporadic BCCs harbor loss-of-function mutations in *PTCH1*, resulting in failure of Hh signaling inhibition by the tumor suppressor PTCH1. Additionally, 10% of BCCs have activating mutations in *SMO*, which constitutively activates GLI1 transcription factor activity downstream as well as Hh signaling, contributing to BCC development.<sup>14,19-21</sup>

HHIs bind to and inhibit SMO, thereby inhibiting activation of GLI1 transcription factors and subsequent downstream transcription of Hh pathway target genes.<sup>7,14,22,23</sup> A portion of patients with advanced BCC can experience intrinsic resistance to HHI therapy.<sup>24</sup> Resistance to HHIs can also be acquired by the introduction of mutations in *SMO* that affect HHI binding or via other indirect mechanisms, including GLI1 transcription factor reactivation through the RAS/MAPK or PI3K/AKT signaling pathways.<sup>14</sup> Studies evaluating the use of HHIs in the BCC treatment setting

have shown that disease progression was a common reason for treatment discontinuation in patients with locally advanced and mBCC.<sup>24</sup>

### Vismodegib and Sonidegib

Vismodegib and sonidegib are FDA-approved HHIs for the treatment of adult patients with locally advanced BCC that has recurred following surgery or RT or for those who are not candidates for surgery or RT. Vismodegib is indicated for both mBCC and locally advanced BCC in this treatment setting.<sup>22,23,25,26</sup> In pivotal studies, both vismodegib and sonidegib have demonstrated objective response rates (ORRs) and improved progression-free survival (PFS); however, the majority of patients receiving an HHI will experience at least 1 treatment-emergent adverse event (TEAE), which can interfere with patient quality of life and may lead to treatment interruption or discontinuation.<sup>19</sup>

In the pivotal, multicenter, single-arm, phase 2 ERIVANCE trial

(NCT00833417), vismodegib treatment in patients with mBCC was associated with an ORR of 30% (95% CI, 16%-48%) (all of which were reported as partial responses [PRs]), median duration of response (DOR) of 7.6 months, and median PFS of 9.5 months (95% CI, 7.4-not estimable).<sup>27</sup> Patients with locally advanced BCC achieved an ORR of 43% (95% CI, 30%-56%), including 21% of patients who achieved complete responses (CRs). The median DOR was 7.6 months, and the median PFS was 9.5 months (95% CI, 7.4-11.9).<sup>25,27</sup>

STEVIE (NCT01367665), a multicenter, single-arm, open-label, phase 2 study, assessed the safety and efficacy of vismodegib in patients with locally advanced BCC or mBCC.<sup>28</sup> At a median follow-up of 17.9 months, the reported ORR was 68.5% (95% CI, 65.7%-71.3%) in patients with locally advanced BCC, including a CR in 33.4%; in patients with mBCC, the reported ORR was 36.9% (95% CI, 26.6%-48.1%), including a CR in 4.8%.<sup>29</sup>

The phase 2, randomized (1:2), double-blind BOLT study (NCT01327053) evaluated the long-term efficacy and safety of sonidegib in patients with mBCC and locally advanced BCC.<sup>26,30</sup> Key efficacy outcomes from the 30-month analysis of 79 patients treated with the FDA-approved 200-mg dose showed that compared with patients with mBCC, patients with locally advanced BCC achieved a higher ORR (8% vs 56%, respectively) and DOR (24.0 months [single patient] vs 26.1 months [median]).<sup>30</sup>

Reported AEs were similar among patients receiving vismodegib or sonidegib in all 3 studies (ERIVANCE, STEVIE, and BOLT trials) and most commonly included muscle spasms, alopecia, dysgeusia, weight loss, fatigue, nausea, loss of appetite, and diarrhea.<sup>27,29,30</sup>

## STAKEHOLDER INSIGHTS

According to the stakeholders, ideal candidates for treatment

with an HHI include patients with locally advanced BCC or unresectable BCC or those who are otherwise considered poor candidates for surgery or RT; patients who have had multiple BCCs, particularly those with Gorlin syndrome; or patients who have large BCCs that are borderline resectable and who may benefit from neoadjuvant therapy.

After discussing the pivotal trial data of the 2 HHIs, the overall consensus among faculty members was that both sonidegib and vismodegib are appropriate treatment options for patients with locally advanced BCC, and they could be expected to produce relatively similar response rates. Panel members agreed that data from the ERIVANCE study indicate a superior response with sonidegib in patients with locally advanced BCC vs mBCC. Some faculty members highlighted contrasting data from the STEVIE trial, which showed that vismodegib provided more comparable response rates in both locally advanced BCC and mBCC populations.<sup>28</sup> A stakeholder expressed a preference for off-label use of sonidegib for both mBCC and locally advanced BCC, noting that, in their experience, it has been better tolerated by patients and has had slightly improved efficacy. Another panelist noted that they most often forgo the use of targeted therapies in the neoadjuvant setting given their concerns for the potential introduction of skip lesions that are associated with a greater local recurrence rate.

### HHI Intolerance

There was consensus among stakeholders that HHIs can be difficult to tolerate, which may lead to challenges related to adherence.

An expert acknowledged that most patients receiving treatment with HHIs experience a potentially life-altering AE, with most occurring within 90 days of treatment initiation. Most TRAEs are managed with an alternate dosing regimen. When incorporating alternate dosing regimens, it is important to allow sufficient off time for the patient to recover from toxicities before reinitiating the treatment regimen. Drug-induced liver injury has been reported with HHIs; however, stakeholders noted that they haven't observed any cases in the practice setting.

As HHI intolerance can present a challenge, stakeholders discussed their management strategies to support patients. A panelist suggested holding treatment for 8 weeks and then reassessing whether to continue holding treatment until progression occurs or to reinitiate with a dose schedule of 8 weeks on and 8 weeks off of treatment. Another panelist shared the innovative strategy of mathematical oncology that has been implemented at their practice site; this incorporates multiple factors (eg, tumor size, imaging) to mathematically determine when a patient should reinitiate therapy.

Experts concurred that it is important to include a nutrition consult when starting treatment, because dysgeusia that occurs in most patients receiving HHIs can frequently lead to weight loss. The panel also acknowledged that numerous psychosocial challenges can arise for patients receiving HHIs, and they may impact medication adherence; the involvement of social workers in the multidisciplinary treatment process can be helpful for patients. Other management strategies discussed included use of L-carnitine and amlodipine for muscle spasms and addition of more spices to foods for improved palatability, although the experts recounted having borderline success with these approaches.

### HHI Resistance and Disease Progression

HHIs typically are effective in shrinking most tumors, but some patients may become resistant to these medications or experience disease progression. For clinical scenarios involving perineural invasion, the panel agreed that it would be reasonable to reengage with consolidation or definitive RT.

The faculty also discussed the use of chemotherapy in patients resistant to HHIs, with one expert having achieved PRs using carboplatin and paclitaxel for patients with mBCC. Additionally, although arsenic trioxide and azole antifungals were noted as potential strategies for clinical scenarios involving therapeutic resistance, they have not been used by experts on the panel.

A panel member also noted that, in clinical scenarios with no observed disease progression, transitioning to immunotherapy following a recovery period would also be an appropriate option.

### ADVANCEMENTS IN SYSTEMIC THERAPY WITH IMMUNE CHECKPOINT INHIBITION

PD-1 inhibitors may play a role in filling unmet needs among patients with advanced BCC, including patients who experience HHI intolerance, resistance to HHIs, or disease progression following HHI treatment; patients for whom an HHI is not appropriate; and patients with significant surgical morbidity and complexity.<sup>31-34</sup>

Cemiplimab is an FDA-approved treatment indicated for patients with locally advanced BCC or mBCC who previously were treated with an HHI or for whom an HHI is not appropriate, with the indication for mBCC granted through accelerated approval.<sup>35</sup>

Other ongoing clinical trials have been initiated to investigate the use of PD-1 inhibitors in patients with advanced BCC in the neoadjuvant or adjuvant settings, in combination strategies, and in HHI-

intolerant or -refractory patients.<sup>36-39</sup> A proof-of-concept, nonrandomized, open-label study investigated the combination of pembrolizumab in combination with vismodegib in 16 patients with unresectable or mBCC and demonstrated an ORR of 38% (95% CI, 15%-65%;  $P = .003$ ) and estimated 1-year PFS and OS rates of 70% and 94%, respectively.<sup>40</sup>

### Tumor Microenvironment

BCCs and SCCs have been identified as cancers that are most increased by immunosuppression.<sup>7,41</sup> BCCs have demonstrated increased levels of proinflammatory mediators, such as IL-10 and CCL22, which may contribute to the suppression of antitumor responses.<sup>42</sup> Tumor immune evasion may also occur via T-cell inactivation, resulting from the interaction of the PD-1 receptor on tumor-infiltrating T cells with PD-L1 and PD-L2 ligands expressed on tumor cells.<sup>43,44</sup> Collectively, these characteristics represent a dynamic

state in which immune stimulatory and immune suppressive forces coexist and compete; this may, in part, explain why the immune system is unable to completely eradicate BCC-associated tumors.<sup>42</sup>

Treatment strategies using checkpoint inhibitors are designed to reinvigorate T cell-mediated antitumor responses, and they have demonstrated efficacy in BCC and other nonmelanoma skin cancers.<sup>33,45</sup> Higher densities of CD8+ T cells, a common characteristic displayed by BCC infiltrates, correlate with increased response rates to immunotherapeutic agents (eg, PD-1/PD-L1 inhibitors).<sup>42,45</sup> In BCC, whole-exome sequencing has revealed a greater tumor mutational burden than seen in other known cancers, a characteristic that has generally predicted favorable response to IO.<sup>41,46</sup> Moreover, PD-1 blockade has demonstrated durable responses that can deepen over time, and treatment is generally well tolerated, even among older patients.<sup>31</sup>

**TABLE.**  
TUMOR RESPONSE PER ICR<sup>33,34,47</sup>

Outcome	laBCC (n=82)	mBCC (n=28)
<b>Best overall response per ICR</b>		
ORR, % (95% CI)	32.1 (22.4-43.2)	21.4 (8.3-41.0)
CR, n (%)	21 (25.0)	0
PR, n (%)	6 (7.1)	6 (21.4)
<b>Estimated PFS</b>		
6 mo, % (95% CI)	—	58.1 (37.1-74.3)
12 mo, % (95% CI)	56.7 (44.5-67.1)	49.8 (29.5-67.1)
24 mo, % (95% CI)	31.7 (20.4-43.5)	—
Median PFS, months (95% CI)	16.5 (8.6-21.4)	8.3 (3.6-19.5) <sup>a</sup>
<b>Estimated OS</b>		
12 mo, % (95% CI)	92.2 (83.4-96.4)	—
24 mo, % (95% CI)	80.3 (69.0-87.9)	—
Median OS, mo (95% CI)	NR	25.7 (19.5-NE) <sup>a</sup>

CR, complete response; ICR, independent central review; laBCC, locally advanced basal cell carcinoma; mBCC, metastatic basal cell carcinoma; NE, not estimable; NR, not reached; ORR, objective response rate; OS, overall survival; PFS, progression-free survival; PR, partial response.

<sup>a</sup> Median Kaplan-Meier estimate.

## CEMIPLIMAB IN ADVANCED BCC

An ongoing, nonrandomized, phase 2 study (NCT03132636) is investigating the safety and efficacy of cemiplimab, a fully human anti-PD-1 monoclonal antibody, for the treatment of patients with mBCC and locally advanced BCC who have experienced progression of disease or have been intolerant of prior HHI treatment.<sup>34,39</sup> Patients received cemiplimab, 350 mg intravenously (IV), every 3 weeks for up to 93 weeks until disease progression or unacceptable toxicity occurred or the patient withdrew consent.<sup>34,47</sup> All patients included in the study had a minimum of 1 measurable baseline lesion, an ECOG performance status of 0 or 1, and disease progression on HHI therapy, intolerance to HHI therapy, or unimproved stable disease after 9 months on HHI therapy.<sup>33,39,47</sup> Overall, patients had received HHI treatment with vismodegib (94%), sonidegib (16.7%), or both (10.7%). Results, discussed below, appear in **TABLE**.<sup>33,34,47</sup>

### Locally Advanced BCC Results

Long-term follow-up results for the locally advanced BCC cohort were presented at the 18th European Association of Dermato-Oncology Congress 2022.<sup>47</sup> At the data cutoff of May 20, 2021, a total of 84 patients were eligible for evaluation and data analysis, with a median duration of follow-up of 15.9 months (range, 0.5–39.7 months). Per independent central review (ICR), the ORR was 32.1% (95% CI, 22.4%–43.2%), with 7.1% of patients (n = 6) achieving a CR and 25.0% (n = 21) achieving a PR. The estimated PFS was 56.7% (95% CI, 44.5%–67.1%) at 12 months and 31.7% (95% CI, 20.4%–43.5%) at 24 months, and the median PFS was 16.5 months (95% CI, 8.6%–21.4%). The estimated OS was 92.2% (95% CI, 83.4%–96.4%) at 12 months and 80.3% (95% CI, 69.0%–87.9%) at 24 months, and the median OS was not reached.<sup>47</sup>

A total of 83 patients (98.8%) experienced a TEAE of any grade, of which fatigue (31.0%), diarrhea (23.8%), pruritus (21.4%), asthenia (20.2%), and arthralgia (19.0%) were the most frequently reported. TEAEs of grade 3 or greater occurred in 44 of 84 patients (52.4%), of which fatigue (4.8%) and urinary tract infections (3.6%) were most commonly reported. Grade 3 TEAEs led to treatment discontinuation in 8 patients (9.5%). Furthermore, serious TEAEs of grade 3 or greater were observed in 24 patients (28.6%). A total of 4 deaths occurred; however, none of these were considered to be related to treatment.<sup>47</sup> Overall, there were no new safety signals compared with previous analyses of cemiplimab in locally advanced BCC.<sup>33,47</sup>

### mBCC Results

At the data cutoff of February 17, 2020, 28 patients with mBCC were eligible for evaluation and analysis. ORR by ICR was 21.4% (95% CI, 8.3%–41.0%), and PR was achieved in 6 patients (21.4%). ORR by investigator assessment was 28.6% (95% CI, 13.2%–48.7%). The median time to response by ICR was 3.2 months (range, 2.1–10.5 months), with an observed DOR of 9 to 23 months; however, the median DOR was not reached. The reported disease control rate was 67.9% (95% CI, 47.6%–84.1%), with a durable disease control rate of 46.4% (95% CI, 27.5%–66.1%). Moreover, the estimated OS and PFS were 25.7 months (95% CI, 19.5 months to not estimable) and 8.3 months (95% CI, 3.6–19.5 months), respectively.<sup>34</sup>

Approximately 92.9% of patients experienced any-grade treatment-related AEs (TRAEs), of which fatigue (50.0%), diarrhea (35.7%), pruritus (25.0%), and constipation (25.0%) were the most frequently reported. Any-grade TRAEs were reported in 78.6% of patients and were most commonly reported as fatigue (42.9%), pruritus (25.0%), and arthralgia (17.9%). TEAEs and TRAEs of grade

3 or greater were observed in 42.9% and 17.9% of patients, respectively. Sponsor-identified immune-related AEs of any grade occurred in 28.6% of patients; the most frequently reported were autoimmune hepatitis, colitis, hypothyroidism, and pneumonitis (7.1% each). Only 1 patient (3.6%) experienced a sponsor-identified, immune-related AE of at least grade 3, which was reported as colitis. TEAEs leading to death occurred in 1 patient; this was attributed to staphylococcal pneumonia and determined not to be related to treatment.<sup>34</sup>

## STAKEHOLDER INSIGHTS

During a discussion of the efficacy outcomes of cemiplimab, stakeholders noted that the associated ORR appears to be durable in responders. The panel agreed that these data are encouraging, and they appear to support the use of PD-1 inhibitors from the perspective of a cumulative clinical benefit. One participant further pointed out that observed responses with PD-1 inhibitors are rather impressive, especially when considering the potential difficulty associated with the management of locally advanced BCC and mBCC. A panelist expressed that further investigation is needed to better understand the observed differences in response rate data for cemiplimab in the neoadjuvant setting; the data are not as robust for populations with advanced BCC relative to data shown for populations with SCC in other trials.

PD-1 inhibitors provide an option to address treatment limitations due to AEs associated with HHIs. The faculty discussed the improved tolerability profile of PD-1 inhibitors and emphasized the importance of considering the patient's quality of life when



deciding among treatment options. Severe toxicities associated with HHI therapy can be a greater concern for patients aged 70 years or older. Consequently, one expert indicated that they have shifted to the preferred use of anti-PD-1 therapy as first-line agents for this population in the neoadjuvant setting; they reserve HHIs for clinical scenarios in which a more rapid response is needed, as in the case of tumor-related organ damage or of tumor invasion of underlying tissues or a joint space. The panel acknowledged that HHIs remain preferred first-line systemic agents when the primary objective is a rapid response with maximal tumor shrinkage.

Because PD-1 inhibitors are administered IV, they may also offer an advantage in terms of adherence over orally administered HHIs, which allow for greater patient autonomy.<sup>48</sup> A participant expressed that frontline use of

anti-PD-1 agents in this clinical setting would also allow a more finite duration of therapy based on response vs intolerance.

### LOOKING AHEAD

The faculty concurred that immunotherapy has expanded treatment options for BCC and has helped to further transform the treatment landscape, and it will likely continue to grow as a therapeutic strategy for advanced BCC. Panelists agreed that the next major challenges will be to determine the best way to use, combine, and sequence immunotherapy with other available treatment options. Multidisciplinary efforts likely will play a major role to help accomplish this task and will be essential to better define ideal patient populations for various treatment modalities.

Cemiplimab is an FDA-approved treatment indicated for patients with locally advanced BCC or mBCC previously treated with an HHI or


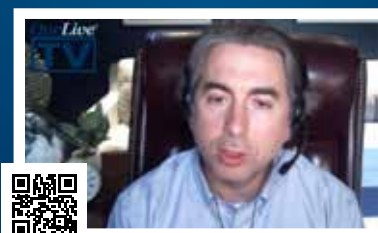
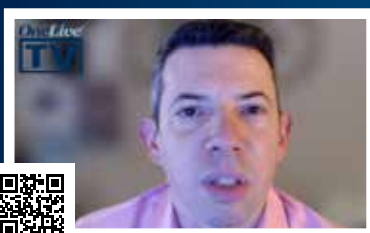
for whom an HHI is not appropriate, with the indication for mBCC granted through accelerated approval.<sup>35</sup>

Looking ahead, the faculty members agreed that further investigation is needed regarding methods aimed at enhancing immunotherapy response and predicting which patients may have durable responses. Stakeholders look forward to further investigation of immunotherapy in the neoadjuvant setting to shed more light on how it may affect cure rates, recurrence, and the need for subsequent surgeries. Moreover, further studies are needed to better define patients who would benefit most from early initiation or prolonged use of immunotherapy. ■

### REFERENCES

1. Key statistics for basal and squamous cell skin cancers. American Cancer Society. Updated January 12, 2022. Accessed May 31, 2022. <https://www.cancer.org/cancer/basal-and-squamous-cell-skin-cancer/about/key-statistics.html>

To hear more about **Basal Cell Carcinoma** from these experts and others, visit **Onclive.com**.



2. Asgari MM, Moffet HH, Ray GT, Quesenberry CP. Trends in basal cell carcinoma incidence and identification of high-risk subgroups, 1998-2012. *JAMA Dermatol.* 2015;151(9):976-981. doi:10.1001/jamadermatol.2015.1188
3. Gareau DS, Krueger JG, Hawkes JE, et al. Line scanning, stage scanning confocal microscope (LSSSCM). *Biomed Opt Express.* 2017;8(8):3807-3815. doi:10.1364/BOE.8.003807
4. Basset-Séguin N, Hauschild A, Grob JJ, et al. Vismodegib in patients with advanced basal cell carcinoma (STEVIE): a pre-planned interim analysis of an international, open-label trial. *Lancet Oncol.* 2015;16(6):729-736. doi:10.1016/S1470-2045(15)70198-1
5. Puig S, Berrocal A. Management of high-risk and advanced basal cell carcinoma. *Clin Transl Oncol.* 2015;17(7):497-503. doi:10.1007/s12094-014-1272-9
6. Migden MR, Guminski A, Gutzmer R, et al. Treatment with two different doses of sonidegib in patients with locally advanced or metastatic basal cell carcinoma (BOLT): a multicentre, randomised, double-blind phase 2 trial. *Lancet Oncol.* 2015;16(6):716-728. doi:10.1016/S1470-2045(15)70100-2
7. Cameron MC, Lee E, Hibler BP, et al. Basal cell carcinoma: epidemiology; pathophysiology; clinical and histological subtypes; and disease associations. *J Am Acad Dermatol.* 2019;80(2):303-317. doi:10.1016/j.jaad.2018.03.060
8. Work Group; Invited Reviewers; Kim JYS, et al. Guidelines of care for the management of basal cell carcinoma. *J Am Acad Dermatol.* 2018;78(3):540-559. doi:10.1016/j.jaad.2017.10.006
9. McDaniel B, Badri T, Steele RB. Basal cell carcinoma. StatPearls Publishing; September 20, 2021. National Center for Biotechnology Information. Accessed July 11, 2022. <https://pubmed.ncbi.nlm.nih.gov/29494046/>
10. Barton DT, Zens MS, Nelson HH, et al. Distinct histologic subtypes and risk factors for early onset basal cell carcinoma: a population-based case control study from New Hampshire. *J Invest Dermatol.* 2016;136(2):533-535. doi:10.1016/j.jid.2015.11.002
11. Leibovitch I, Huilgol SC, Selva D, Richards S, Paver R. Basal cell carcinoma treated with Mohs surgery in Australia III. Perineural invasion. *J Am Acad Dermatol.* 2005;53(3):458-463. doi:10.1016/j.jaad.2005.04.089
12. Pyne JH, Myint E, Hou R, Clark SP, Wong C, Gorji M. Basal cell carcinoma with perineural invasion: a prospective study examining subtype, tumor surface diameter, invasion depth, and anatomic site in 3005 consecutive cases. *J Cutan Pathol.* 2020;47(11):1033-1038. doi:10.1111/cup.13808
13. Nevoid basal cell carcinoma syndrome. National Organization for Rare Disorders. 2021. Accessed June 29, 2022. <https://rarediseases.org/rare-diseases/nevoid-basal-cell-carcinoma-syndrome/#:~:text=The%20nevoid%20basal%20cell%20carcinoma,known%20as%20basal%20cell%20carcinoma>
14. Wilson M, Johnson RP, Senft SC, Pan EY, Krakowski AC. Advanced basal cell carcinoma: what dermatologists need to know about treatment. *J Am Acad Dermatol.* 2022;86(6S):S14-S24. doi:10.1016/j.jaad.2022.03.022
15. Quazi SJ, Aslam N, Saleem H, Rahman J, Khan S. Surgical margin of excision in basal cell carcinoma: a systematic review of literature. *Cureus.* 2020;12(7):e9211. doi:10.7759/cureus.9211
16. van Loo E, Mosterd K, Krekels GA, et al. Surgical excision versus Mohs' micrographic surgery for basal cell carcinoma of the face: a randomised clinical trial with 10 year follow-up. *Eur J Cancer.* 2014;50(17):3011-3020. doi:10.1016/j.ejca.2014.08.018
17. Muller FM, Dawe RS, Moseley H, Fleming CJ. Randomized comparison of Mohs micrographic surgery and surgical excision for small nodular basal cell carcinoma: tissue-sparing outcome. *Dermatol Surg.* 2009;35(9):1349-1354. doi:10.1111/j.1524-4725.2009.01240.x
18. Condorelli AG, Motolese A, Borgia F, et al. Photodynamic therapy for superficial basal cell carcinomas: clinical features of partial responses and recurrences. *Photodiagn Photodyn Ther.* 2022;37:102727. doi:10.1016/j.pdpdt.2022.102727
19. Lacouture ME, Dréno B, Ascierto PA, et al. Characterization and management of hedgehog pathway inhibitor-related adverse events in patients with advanced basal cell carcinoma. *Oncologist.* 2016;21(10):1218-1229. doi:10.1634/theoncologist.2016-0186
20. Tay EY, Teoh YL, Yeo MS. Hedgehog pathway inhibitors and their utility in basal cell carcinoma: a comprehensive review of current evidence. *Dermatol Ther (Heidelb).* 2019;9(1):33-49. doi:10.1007/s13555-018-0277-7
21. Xie J, Murone M, Luoh SM, et al. Activating smoothed mutations in sporadic basal-cell carcinoma. *Nature.* 1998;391(6662):90-92. doi:10.1038/34201
22. Erivedge. Prescribing information. Genentech Inc; 2020. Accessed June 13, 2022. [https://www.gene.com/download/pdf/erivedge\\_prescribing.pdf](https://www.gene.com/download/pdf/erivedge_prescribing.pdf)
23. Odomzo. Prescribing information. Sun Pharmaceutical Industries Inc; 2019. Accessed June 13, 2022. <https://www.odomzo.com/themes/custom/odomzo/global/pdfs/pi.pdf>
24. Doan HQ, Chen L, Nawas Z, Lee HH, Silapunt S, Migden M. Switching hedgehog inhibitors and other strategies to address resistance when treating advanced basal cell carcinoma. *Oncotarget.* 2021;12(20):2089-2100. doi:10.18632/oncotarget.28080
25. A study evaluating the efficacy and safety of vismodegib (GDC-0449, hedgehog pathway inhibitor) in patients with advanced basal cell carcinoma. ClinicalTrials.gov. Updated May 20, 2015. Accessed May 28, 2022. <https://>

- clinicaltrials.gov/ct2/show/NCT00833417
26. A phase II study of efficacy and safety in patients with locally advanced or metastatic basal cell carcinoma (BOLT). ClinicalTrials.gov. Updated August 28, 2019. Accessed May 28, 2022. <https://clinicaltrials.gov/ct2/show/NCT01327053>
  27. Sekulic A, Migden MR, Oro AE, et al. Efficacy and safety of vismodegib in advanced basal-cell carcinoma. *N Engl J Med*. 2012;366(23):2171-2179. doi:10.1056/NEJMoa1113713
  28. STEVIE: a study of vismodegib in patients with locally advanced or metastatic basal cell carcinoma. ClinicalTrials.gov. Updated June 6, 2019. Accessed June 14, 2022. <https://clinicaltrials.gov/ct2/show/NCT01367665>
  29. Basset-Séguin N, Hauschild A, Kunstfeld R, et al. Vismodegib in patients with advanced basal cell carcinoma: primary analysis of STEVIE, an international, open-label trial. *Eur J Cancer*. 2017;86:334-348. doi:10.1016/j.ejca.2017.08.022
  30. Dummer R, Guminksi A, Gutzmer R, et al. Long-term efficacy and safety of sonidegib in patients with advanced basal cell carcinoma: 42-month analysis of the phase II randomized, double-blind BOLT study. *Br J Dermatol*. 2020;182(6):1369-1378. doi:10.1111/bjd.18552
  31. In GK, Nallagangula A, Choi JS, et al. Clinical activity of PD-1 inhibition in the treatment of locally advanced or metastatic basal cell carcinoma. *J Immunother Cancer*. 2022;10(5):e004839. doi:10.1136/jitc-2022-004839
  32. Davis CM, Lewis KD. Brief overview: cemiplimab for the treatment of advanced basal cell carcinoma: PD-1 strikes again. *Ther Adv Med Oncol*. 2022;14:17588359211066147. doi:10.1177/17588359211066147
  33. Stratigos AJ, Sekulic A, Peris K, et al. Cemiplimab in locally advanced basal cell carcinoma after hedgehog inhibitor therapy: an open-label, multi-centre, single-arm, phase 2 trial. *Lancet Oncol*. 2021;22(6):848-857. doi:10.1016/S1470-2045(21)00126-1
  34. Lewis, K, Peris, K, Sekulic, A, et al. Interim analysis of phase 2 results for cemiplimab in patients with metastatic basal cell carcinoma (mBCC) who progressed on or are intolerant to hedgehog inhibitors (HHIs). *J Cutan Med*. 2021;5(1):s3. doi:10.25251/skin.5.supp.3
  35. FDA approves cemiplimab-rlwc for locally advanced and metastatic basal cell carcinoma. News release. FDA. February 9, 2021. Accessed June 26, 2022. <https://www.fda.gov/drugs/resources-information-approved-drugs/fda-approves-cemiplimab-rlwc-locally-advanced-and-metastatic-basal-cell-carcinoma>
  36. Neoadjuvant-adjuvant pembrolizumab in resectable advanced basal cell carcinoma of H&N. ClinicalTrials.gov. Updated April 12, 2022. Accessed June 27, 2022. <https://clinicaltrials.gov/ct2/show/NCT04323202>
  37. Anti-PD1-antibody and pulsed HHI for advanced BCC. ClinicalTrials.gov. Updated March 18, 2021. Accessed June 27, 2022. <https://clinicaltrials.gov/ct2/show/NCT04679480>
  38. Nivolumab alone or plus relatlimab or ipilimumab for patients with locally-advanced unresectable or metastatic basal cell carcinoma. ClinicalTrials.gov. Updated March 25, 2022. Accessed June 27, 2022. <https://clinicaltrials.gov/ct2/show/NCT03521830>
  39. PD-1 in patients with advanced basal cell carcinoma who experienced progression of disease on hedgehog pathway inhibitor therapy, or were intolerant of prior hedgehog pathway inhibitor therapy. ClinicalTrials.gov. Updated March 23, 2022. Accessed May 28, 2022. <https://clinicaltrials.gov/ct2/show/NCT03132636>
  40. Chang ALS, Tran DC, Cannon JGD, et al. Pembrolizumab for advanced basal cell carcinoma: an investigator-initiated, proof-of-concept study. *J Am Acad Dermatol*. 2019;80(2):564-566. doi:10.1016/j.jaad.2018.08.017
  41. Jayaraman SS, Rayhan DJ, Hazany S, Kolodney MS. Mutational landscape of basal cell carcinomas by whole-exome sequencing. *J Invest Dermatol*. 2014;134(1):213-220. doi:10.1038/jid.2013.276
  42. Kaporis HG, Guttman-Yassky E, Lowes MA, et al. Human basal cell carcinoma is associated with Foxp3+ T cells in a Th2 dominant microenvironment. *J Invest Dermatol*. 2007;127(10):2391-2398. doi:10.1038/sj.jid.5700884
  43. Libtayo. Prescribing information. Regeneron Pharmaceuticals Inc; 2021. Accessed June 28, 2022. [https://www.regeneron.com/downloads/libtayo\\_fpi.pdf](https://www.regeneron.com/downloads/libtayo_fpi.pdf)
  44. About Libtayo. Regeneron Pharmaceuticals Inc; 2021. Accessed June 29, 2022. <https://www.libtayo360xp.com/pdf/Skin-Referral-Leave-Behind.pdf>
  45. Petitprez F, Meylan M, de Reyniès A, Sautès-Fridman C, Fridman WH. The tumor microenvironment in the response to immune checkpoint blockade therapies. *Front Immunol*. 2020;11:784. doi:10.3389/fimmu.2020.00784
  46. Stonesifer CJ, Djavid AR, Grimes JM, et al. Immune checkpoint inhibition in non-melanoma skin cancer: a review of current evidence. *Front Oncol*. 2021;11:734354. doi:10.3389/fonc.2021.734354
  47. Stratigos AJ, Sekulic A, Peris K, et al. Phase 2 study of cemiplimab in patients with locally advanced basal cell carcinoma after hedgehog inhibitor therapy: longer-term follow-up. Presented at: 18th European Association of Dermato-Oncology (EADO) Congress; April 21-23, 2022; Seville, Spain.
  48. Immune checkpoint inhibitors and their side effects. American Cancer Society. March 22, 2022. Accessed June 30, 2022. <https://www.cancer.org/treatment/treatments-and-side-effects/treatment-types/immunotherapy/immune-checkpoint-inhibitors.html#references>

# Expert Q&A Regarding the Management of Patients With Basal Cell Carcinoma



## EVAN J. LIPSON, MD

Associate Professor of Oncology  
Johns Hopkins University  
Baltimore, MD



## JASON J. LUKE, MD, FACP

Director  
Cancer Immunotherapeutics  
Center  
UPMC Hillman Cancer Center  
Pittsburgh, PA  
Associate Professor of Medicine  
Division of Hematology/  
Oncology  
University of Pittsburgh School  
of Medicine  
Pittsburgh, PA



## SOO PARK, MD

Medical Oncologist  
Assistant Professor of Medicine  
University of California,  
San Diego  
San Diego, CA

## INTRODUCTION

Editors from *OncLive*<sup>®</sup> spoke with Evan J. Lipson, MD; Jason J. Luke, MD, FACP; and Soo Park, MD. These experts in dermatologic malignancies provided insight on the current treatment landscape for patients with basal cell carcinoma (BCC), including the use of Hedgehog inhibitors and other emerging solutions.

*\*Interview transcripts are edited for readability.*

➤ TO WATCH THE VIDEO INTERVIEWS, VISIT [ONCLIVE.COM](https://www.onclive.com)

### ***OncLive*<sup>®</sup>: What is the current treatment landscape for patients with locally advanced unresectable or metastatic basal cell carcinoma?**

**EVAN J. LIPSON, MD:** The current treatment landscape for patients with locally advanced unresectable or metastatic [BCC] generally falls into 2 categories. The first is Hedgehog [Hh] pathway inhibitors. There are 2 drugs approved by the FDA for that purpose: sonidegib and vismodegib. Both of those are a standard-of-care therapy for often front-line patients with advanced BCC. The second option, which has typically been tested in the [Hh] setting, is anti-PD-1. Cemiplimab is the most well-known of the agents for basal cell. It is approved by the FDA for patients who have [been previously treated with an Hh pathway inhibitor] or [for patients in which Hh inhibitor therapy is not appropriate]. [Other treatment options include] targeted agents and some immunotherapy as well.

**JASON J. LUKE, MD, FACP:** In the context of refractory or unresectable [BCC], we think about 2 classes of therapeutics. The most common obviously being [Hh] inhibition with the smoothed inhibitors, which have been a standard of care going back almost a decade being our targeted therapy approach. That class of therapy unfortunately has some issues in terms of tolerability. The other class that is emerging and very exciting is immunotherapy. Similar to other cutaneous malignancies, anti-PD-1 antibodies and, particularly, cemiplimab, are now approved as a standard of care agent. When we think about which [treatment] to use in which patient, it comes down to [adverse] effect profile and the goals. Obviously with targeted therapy, we can get pretty rapid responses. Unfortunately, the [Hh] inhibitors are difficult on patients in terms of chronic toxicity. Whereas with immunotherapy, we have the rare but real long-term responders, albeit with a lower response rate up front. That's really where the

tension lies. Do we need that response right now, or are we going for the long game?

**SOO PARK, MD:** For patients with locally advanced unresectable or metastatic [BCC], typically we [treat with Hh] inhibitors. For patients who progress on an [Hh] inhibitor, cannot take it for any reason, or have intolerable [adverse] effects, we do have the option of cemiplimab, which is an immunotherapy that was approved last year for this patient population. Now we have 2 different treatment options, whereas before we just had 1.

**Onclive®: When a colleague encounters a patient with BCC, what advice would you give them for handling that multidisciplinary approach?**

**EVAN J. LIPSON, MD:** A multidisciplinary approach is critical when you're caring for patients with advanced BCC. In fact, I think our best advice to colleagues who practice outside of our geographic area and who encounter a patient with advanced BCC is to assemble a multidisciplinary team of experts [comprising] specialists from dermatopathology; dermatology, in particular Mohs surgeons; [and] practitioners from surgical oncology, oftentimes [including] head and neck reconstructive surgery. Oculoplastics oftentimes plays a role. Radiation oncology is important. Medical oncology, of course. Some of the therapies we use including radiation therapy and some of the [Hh] drugs negatively impact a patient's ability to eat, so a nutritionist is also someone to have on the team.

**JASON J. LUKE, MD, FACP:** [Management of a BCC] is predicated on multidisciplinary care of the patient because these patients are commonly diagnosed early in their course

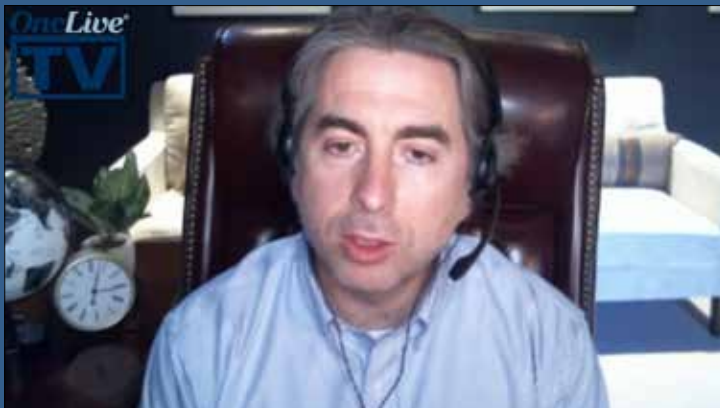with multiple skin cancers [with] basal cell being common. They are really in the purview of the dermatologist for much of their care until a lesion becomes more than the kind of lesion that can be easily managed in an outpatient visit. Very quickly thereafter, the team expands, and we need to get involvement with maybe the surgeon, radiation, oncology, [or] medical oncology. You have the number of therapeutics that are now available. Having all these people at a seat of the table is important because what constitutes a resectable lesion can vary quite a bit depending on regional practice patterns and the comfort levels of the doctors involved—whether or not you would want to use consolidate or primary radiation as the therapeutic approach, [for example]. Then considerations around the unresectable setting or neoadjuvant considerations. These are very complicated cases, and we really do need all hands on deck and all the expertise that we can bring to bear for each patient.

**SOO PARK, MD:** Because [BCC] is a nonmelanoma skin cancer, and the patient may have already seen a bunch of different physicians, I think it is always best for not only the medical oncologist but the surgical oncologist, the dermatologist, the dermatopathologist, and the radiologist [to] all get around and talk about the patient's case. Even if the patient [has metastatic disease], I do feel like they benefit from multidisciplinary discussion, so we can see how all treatment regimens or the ways we sequence treatments could potentially benefit the patient. Sometimes we can come up with a different type of regimen or a different sequence that gives a patient a longer time off therapy, longer durable response, or longer time to keep the disease at bay. »



Evan J. Lipson, MD

“Our best advice to colleagues who practice outside of our geographic area and who encounter a patient with advanced BCC is to assemble a multidisciplinary team of experts.”



Jason J. Luke, MD, FACP

“It’s very exciting that a whole new era is open with immunotherapy [in the treatment of advanced] basal cell [carcinoma]. There is just a lot to do to fully understand how to use it properly.”

**OncoLive®: Could you provide an example of a challenging clinical situation involving a patient with BCC and explain how that situation should be handled?**

**EVAN J. LIPSON, MD:** One challenging scenario that we occasionally encounter is when...an organ transplant recipient, typically a solid organ transplant, presents with a locally advanced [BCC]. This happens [frequently]. Aggressive skin cancers are very common in patients who have undergone organ transplantation and are chronically immunosuppressed. Typically, the use of an [Hh] pathway inhibitor is OK in those patients. There is really not a danger of damaging the transplanted organ. The same cannot be said for the use of anti-PD-1 immunotherapy in patients with solid organ transplants, and that is a real challenge. That is something that we’ve tried to address at Johns Hopkins. Just this past [American Society of Clinical Oncology Annual Meeting], Dr Kara Shank presented some of our results from that study [that looked] at the use of anti-PD-1 in combination with immunosuppressive medications to try to thread that needle where you are helping the immune system attack cancer but also encouraging it to leave alone the transplanted organ. I would encourage practitioners who run into that situation to refer patients for clinical trial participation for organ transplant recipients.

**JASON J. LUKE, MD, FACP:** In [BCC], the 2 obvious scenarios that are very difficult are primary diagnosis of an infiltrated lesions that has anatomical sensitivity [and] patients who are refractory at all available treatment service. For the former, we think about many basal cells being diagnosed in areas with high sun exposure. [The] neck commonly involves the face. Areas around the nose and mouth or around the eye can be particularly difficult to

deal with because you cannot do wide excisions; otherwise, you take out vital organs. Those can be very touchy, and those require very complicated conversations with the patient. Surgeons are willing to [perform surgery]. The question sometimes becomes: Should they? Because of the postoperative effects, these curative surgeries can be difficult for patients. We might need to think about neoadjuvant approaches to try to resect the area and [think about] how we are going to manage those patients over the long term. Finally, I just know quickly that if patients are refractory to both [Hh] inhibitors and immunotherapy, that is a huge unmet need as well. In those patients, we still do chemotherapy albeit with limited efficacy and well-known toxicity spectrum associated with chemotherapy.

**SOO PARK, MD:** Oftentimes we do see a patient who has a [BCC] that is considered to be locally advanced, potentially unresectable because the patient is not amenable to such an extensive resection, even though, technically, [according to] the surgeon, it is resectable. What we will sometimes do [with those patients] is give up-front [Hh pathway inhibitor therapy]....They typically have a good response to up-front [Hh pathway inhibitor therapy] to the point where the tumor does get much smaller to where they can get surgery, in which case it would be considered neoadjuvant. If they only get up-front [Hh pathway inhibitor therapy and] they have nearly a complete response, sometimes there is nothing to resect or you do not know what to resect. We will send them to our radiation oncologist colleagues, and they will consider consolidating the response with radiation. We have seen really good, durable responses with that. It is always a multidisciplinary discussion. I just want to stress, though, that this use of up-front [Hh] is not standard.

**OncoLive®: Generally, what has been seen with the use of cemiplimab in clinical trials for patients with BCC?**

**EVAN J. LIPSON, MD:** Cemiplimab is an anti-PD-1 agent, and the idea is to activate T cells against [the] tumor. Cemiplimab was tested in a study involving 84 patients with locally advanced [BCC] that had received [Hh] pathway inhibitor therapy. It was also tested in the metastatic setting, although we know a little bit more about its use in locally advanced patients. The overall response rate in the locally advanced setting was 31%, so perhaps a little bit lower than we were used to seeing with some of the other nonmelanoma skin cancers like Merkel cell carcinoma or cutaneous squamous cell cancer. In any case, the safety profile that was associated with cemiplimab in that study was consistent [with] what we have seen in previous studies of anti-PD-1 monotherapy; [there were] no safety surprises. With a median duration of follow-up of 15 months, the median duration of response had not been reached. This is typical of what we see with anti-PD-1. When the immune system has its hands wrapped around the cancer, oftentimes it can do so for long periods of time. The study results from that trial supported FDA approval of cemiplimab for patients who have received a [Hh] pathway inhibitor and experienced progression or toxicity that was intolerable or for patients for whom [Hh] pathway inhibitor therapy is not appropriate.

**JASON J. LUKE, MD, FACP:** [With] the approval of anti-PD-1 with cemiplimab in [BCC], we are really entering a new era. Very interestingly when we compare the use of immunotherapy for basal cell vs other cutaneous malignancies, there are some distinct features. Whereas in melanoma and cutaneous squamous cell carcinoma, we see [quick and robust] responses to anti-PD-1. In [BCC], for reasons that actually are not that clear, the response rate is actually lower, [around] 20% to 30%, and take longer to develop. Whereas we are used to seeing on the first scan that tumors are shrinking with PD-1 antibodies, with [BCC], many of the patients who had disease regression took 4 to 6 months before we saw that. This is an important point in practice, which is to say that you have to give it a little time; most of the patients will actually have stabilization initially and then [will regress] over time. It is just as important to level set and understand that in this disease setting, it looks slightly different [than] in some of the other [diseases that can occur] in the same organ. Immunotherapy and basal cell are going to take some time to mature in the response, but those patients who do get a quality response have long-term durable benefit much like we have seen in other kinds of cancers.

**SOO PARK, MD:** It has been studied in the locally advanced unresectable setting and in the metastatic group. We have seen partial responses that have lasted for a long time. I think that is encouraging, especially for an agent that is well tolerated compared to the [Hh] inhibitors, which are not very well tolerated. That is why patients have to go off them in a couple months, depending on what the patient can

tolerate. I think it will be interesting to see how cemiplimab performs in the up-front setting given the responses that we have seen after [Hh] inhibitor failure or intolerance; responses do seem to last for a good amount of time.

**OncoLive®: In terms of the future and additional research, where would you like to see things go in the coming years as they continue to progress?**

**EVAN J. LIPSON, MD:** Here at Johns Hopkins, we are investigating how immune checkpoint-blocking therapy could more prominently play a role in a treatment paradigm for patients with advanced BCC. For example, we are testing anti-PD-1 in a front-line setting, and it may be that patients who have already been treated with a [Hh] pathway inhibitor could be less likely to respond to anti-PD-1. We will see whether in the front-line setting we can increase the response rate that we've seen in previous trials. Additionally, we are testing the safety and efficacy of additional immune checkpoint pathway blockers [including] anti-LAG3, which is the new immune checkpoint pathway on the block, and anti-CTLA4, particularly ipilimumab, for patients in whom anti-PD-1 monotherapy is insufficient.

**JASON J. LUKE, MD, FACP:** In [BCC], we have an unmet need in as much as there are patients who develop refractory disease. I think that emphasizes a couple of areas. One is we could use better [Hh] inhibitors. Our current class is too toxic to continuously dose them. More potent and less toxic drugs would really be advantageous. Then much like many other diseases, the mechanisms or resistance to checkpoint immunotherapy are varied. We do not understand them in [BCC] yet, but as that research matures, we could come for them with combination regimens that could enhance the up-front benefit and hopefully limit resistance over the long period of time. It's very exciting that a whole new era is open with immunotherapy basal cell. There is just a lot to do to fully understand how to use it properly.

**SOO PARK, MD:** One [way I would like to see the landscape progress] is how patients would respond if we gave [them] first-line [therapies] instead of [Hh]. Another way I could see [a need for progress] is after a patient is on up-front [Hh] and they have to come off it for intolerance [due] to [adverse] effects, but they still need their tumor controlled. Maybe you can switch them to something like cemiplimab as a maintenance strategy given that even though cemiplimab may not completely get rid of the tumor, it is good at keeping the tumor controlled for a prolonged period of time. That may be enough for the patient not to really get symptoms from the tumor and be able to tolerate the [therapy]. I also see cemiplimab in combination with [Hh] or sequenced differently. There was a study in the past that looked at combining immunotherapy with [Hh]; there were some responses, but I don't think it was super encouraging. It was a small study, so I think learning how to combine cemiplimab with other agents, not just [Hh], could potentially benefit the patient. ■

