

Early amniotic membrane ring placement and new amniotic membrane ring design for a severe chemical burn patient.

Resident: Jae Kim, MD

Faculty Mentor: Mark McDermott, MD MBA

Kresge Eye Institute, Detroit MI

Abstract

A 53-year-old male presented to the ED with a chemical injury to both eyes from choline hydroxide (pH 14.9). The patient was diagnosed with a grade 3 chemical injury, based on Roper Hall Classification. The burn was copiously irrigated until the initial pH level of 8.5 normalized to 7.2. During the acute phase of chemical injury, we placed the Prokera immediately in conjunction with medical management. Despite active daily follow-up, after six months, the patient's visual acuity decreased from 20/50 and 20/40 at the initial presentation to 20/200 and 20/80 currently in the right and left eye, respectively. Early placement of the amniotic membrane ring can minimize the corneal damage for severe chemical injury. However, the limitations of the current amniotic membrane ring design leave room for possible improvement. The new support ring design presented in this report could maximize the membrane-to-cornea contact time, prevent the symblepharon, and provide the patient comfort.

History

A 53-year-old male with no significant medical or ocular history presented to the ED after getting splashed in his eyes with an unknown chemical. The patient, who works as a truck driver, was injured after one of the chemical containers popped open, while he was not wearing protective eye equipment. In the ED, the patient reported mild discomfort in both eyes but denied changes in vision or pain. The patient's fornices were swept thoroughly, and a pH strip determined an initial pH around 8.5. The eyes were immediately irrigated with a Morgan lens and normal saline, and after 5 liters of irrigation in each eye, the pH decreased to 7.2. After an investigation, we determined that the inciting agent was choline hydroxide, a chemical with a pH of 14.9.

Given the chemical's strong alkalinity, the immediate concern was corneal melting with possible perforation and the development of glaucoma from damaged trabecular meshwork and contraction of the anterior structure. Our patient was started on topical antibiotics, a cycloplegic agent, and a topical steroid. After checking the patient's kidney functions, we started the patient on vitamin C, and doxycycline was started as well. The next day, our patient was placed with Prokera in both eyes.

Examination

The bilateral periorbital area and upper and lower eyelids were injured. Visual acuity using the near-card was 20/50 and 20/40 in the right and left eye, respectively. Right and left intraocular pressures (IOP) were 18 and 12, respectively. Extraocular movements were full, and confrontational visual field was full bilaterally with no afferent pupillary defect. An anterior exam revealed diffuse conjunctival injection with mild chemosis bilaterally. Limbal whitening was appreciated inferiorly more than 180 degrees in the right eye and about 70 degrees in the left eye. The cornea was opacified with stromal haziness in bilaterally, with the right eye being worse than the left, and the inferior half was opacified worse in both eyes (Figure 1). While the view to the anterior chamber (AC) and iris was obscured, AC was grossly deep, and anterior segment anatomy appeared to be intact. Fluorescein staining showed complete corneal epi-defect extending

to the bulbar conjunctiva inferiorly bilaterally, but palpebral conjunctiva appeared to be intact (Figure 1). Posterior exam was unremarkable. Based on the exam, the patient was diagnosed with grade 3 chemical injury based on Roper Hall Classification. The patient's complete corneal epithelium defect, conjunctival injury, more than 180 degrees of limbal ischemia, and the high alkalinity of the chemical contributed towards a poor visual prognosis.

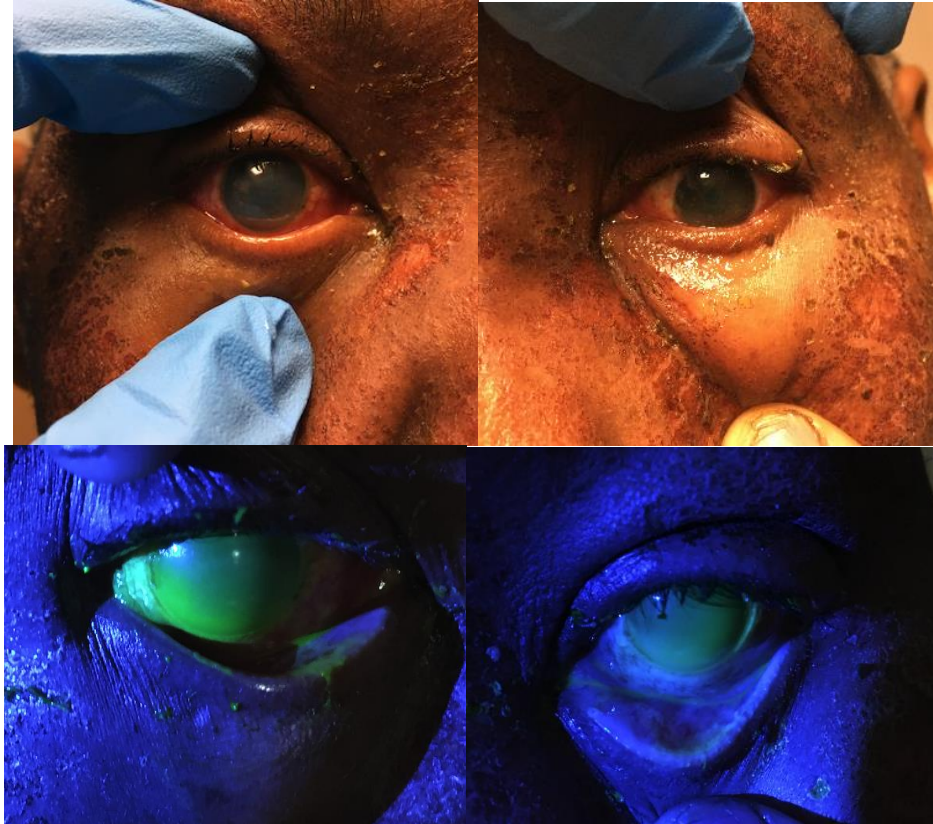


Figure 1. External images and fluorescein staining three days after the initial presentation.

Discussion and Diagnosis

In managing any chemical eye injury, regardless of the severity, the most critical initial management is copious irrigation to decrease chemical exposure [1-3]. The purpose of medical treatment is to help heal the corneal epithelium, augment collagen synthesis, control inflammation, and prevent infection[4]. For grades 2 to 4, inflammation control in the first week of the acute phase is of utmost importance [5]. Topical steroid, cycloplegia for comfort, and topical antibiotics are essential. Oral tetracycline is used to reduce inflammation via matrix metalloproteinase inhibition, while vitamin C delays corneal ulceration [6].

For grades 2 and 3, the early amniotic membrane treatment is often questioned because of the cost of the device [7]. However, for our patient with a grade 3 chemical injury, we chose to place the Prokera immediately as we thought the benefits of the amniotic membrane are substantial [8]. Such benefits include anti-inflammation, anti-scarring, stem cell proliferation, and epithelization promoting effects on the corneal surface [9-11]. It is also believed that early use of the membrane promotes the healing of the ocular surface by preventing the leucocytic infiltration, decreasing the duration and severity of inflammation, and

protecting the proliferating epithelial stem cell layer [12]. After six months of active treatment, our patient's corneal condition is stable. However, the patient developed severe stromal scarring and astigmatism with corneal vascularization (Figure 2).

While the placement of the early amniotic membrane is crucial for the sound recovery of a severe chemical injury, the treatment management of our patient and past patient experiences led us to consider whether the current Prokera support ring is the most optimal design for patients. Many patients, including ours, expressed discomfort with the ring. The non-conformity of the ring to the human globe may contribute to the discomfort. Additionally, the non-conformity caused the ring to be non-stationary, potentially reducing the amniotic membrane and cornea contact time. We decided to design a ring for the amniotic membrane that maximizes the membrane contact time and provides more comfort.

We started with a model of the current Prokera ring based on the dimensions available in the Prokera manufacturer website (Figure 3a). When placing the Prokera ring model on the human globe model, the current Prokera ring did not conform to the globe and would not correctly fit the fornix contour (Figure 3b). To address these design limitations, we proposed a new support ring design based on a few anatomical parameters, including the cross-sectional dimension of the human globe, limbus-to-limbus dimension, the transverse and sagittal diameter of the human globe, and the fornix depth [13]. Based on these parameters, a prototype design was created (Figure 4a). When comparing the placement of the new prototype ring on the eye model with the current Prokera model, the new design conforms to the globe more naturally and can completely cover the cornea with the membrane (Figure 4b and 5). The new ring is thinner than the current Prokera ring, and the height is longer to reach the fornix, preventing symblepharon formation. We believe the new design will limit the mobility of the ring to provide more comfort and stabilize membrane-to-cornea contact time.

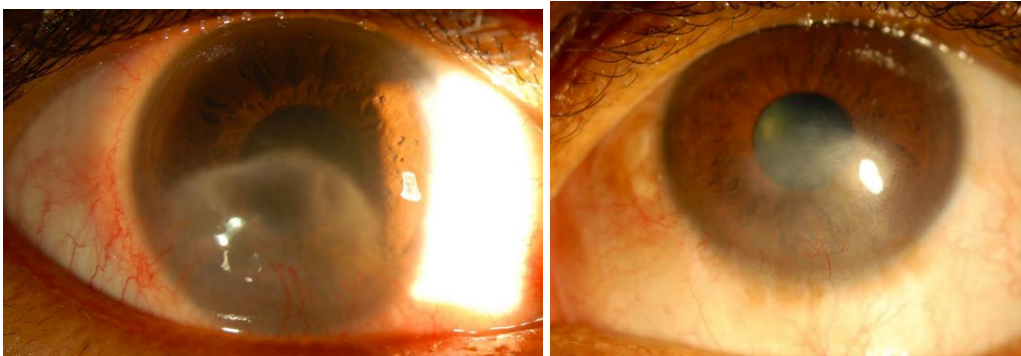


Figure 2. External photos six months after the injury




Figure 3. Current Prokera Ring design



Figure 4. New Proposed Amniotic Membrane Ring

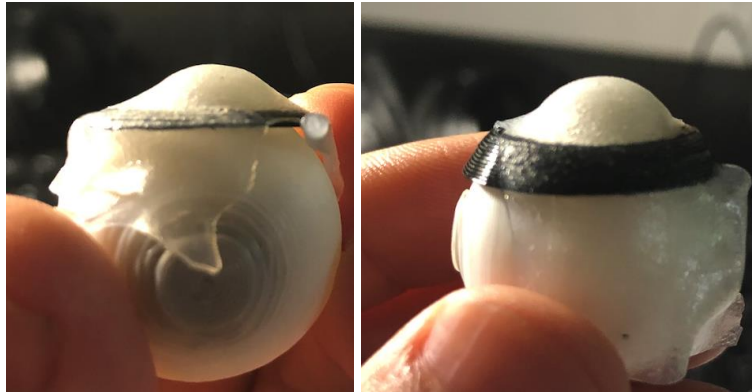

Figure 5. Comparison between Prokera and new proposed ring

Conclusion

For grade 2 or 3 chemical injuries, the decision to place the amniotic membrane immediately versus waiting after the active phase of injury depends on the clinician's discretion. Our patient had a grade 3 chemical injury, and the immediate placement of the Prokera in both eyes may have prevented further damage to the patient's cornea despite the development of the scarring with vascularization and astigmatism. To maximize the benefit of the amniotic membrane, we proposed a new support ring design. The new ring is designed to conform to the human globe, deep enough to get to the fornix to prevent symblepharon formation while stabilizing membrane-to-cornea contact time. Overall, the immediate amniotic membrane placement with the new proposed design could improve patient care for patients with severe conditions, including chemical burns, Steven Johnson Syndrome, and severe corneal ulcers.

References

- [1] Chau, J., D. T.F. Lee, and S. H.S. Lo, A Systematic Review of Methods of Eye Irrigation for Adults and Children with Ocular Chemical Burns. *Worldviews on evidence-based nursing / Sigma Theta Tau International, Honor Society of Nursing*, 2011. 9: p. 129-38.
- [2] Sharma, N., et al., Treatment of acute ocular chemical burns. *Surv Ophthalmol*, 2018. 63(2): p. 214-235.
- [3] Scott, R., The injured eye. *Philos Trans R Soc Lond B Biol Sci*, 2011. 366(1562): p. 251-60.
- [4] Dohlman, C.H., F. Cade, and R. Pfister, Chemical burns to the eye: paradigm shifts in treatment. *Cornea*, 2011. 30(6): p. 613-4.
- [5] Colby, K., Chemical injuries of the Cornea. *Focal Points in American Academy of Ophthalmology*. 2010. 28(1): p. 1-14.

- [6] Ralph, R.A., Tetracyclines and the treatment of corneal stromal ulceration: a review. *Cornea*, 2000. 19(3): p. 274-7.
- [7] Fish, R. and R.S. Davidson, Management of ocular thermal and chemical injuries, including amniotic membrane therapy. *Current opinion in ophthalmology*, 2010. 21(4): p. 317-21.
- [8] Mellor D, Pires RTF, Mack RJS, Figueiredo F, Heiligenhaus A, Park WC et al. Amniotic membrane transplantation for acute chemical and thermal burns. *Ophthalmology* 2000; 107: 980–990.
- [9] Choi YS, Kim JY, Wee WR, Lee JH. Effect of application of human amniotic membrane in rabbit corneal wound healing after excimer laser photo refractive keratectomy. *Cornea* 1998; 17: 389–395
- [10] Tseng SC, Li D-Q, Ma X. Suppression of transforming growth factor-beta isoforms, TGF-beta receptor type II, and myofibroblast differentiation in cultured human corneal and limbal fibroblast by amniotic membrane matrix. *J Cell Physiol* 1999; 179: 325–335
- [11] Tseng SCG, Prabhasawat P, Barton K, Gray T, Melter D. Amniotic membrane transplantation with or without limbal allografts for corneal surface reconstruction in patients with limbal stem cell deficiency. *Arch Ophthalmol* 1998; 116: 431– 441.
- [12] Liu T, Zhai H, Xu Y, et al. Amniotic membrane traps and induces apoptosis of inflammatory cells in ocular surface chemical burn. *Mol Vis*. 2012;18:2137-2146.