

## **Clinical and in vivo Confocal Microscopic Features of a Patient with Neuropathic Corneal Pain Secondary to Small Fiber Neuropathy**

Resident: Delu Song, MD, PhD, MTR

Faculty mentor: Mina Massaro-Giordano, MD

Scheie Eye Institute, Perelman School of Medicine, University of Pennsylvania

### **Abstract**

A 48-year-old female with complaints of severe persistent burning pain and foreign body sensation in both eyes for the past year. Ocular examination was unremarkable except for a few punctate epithelial erosions bilaterally. The patient showed a poor response to frequent instillations of artificial tears and cyclosporine eye drops. In vivo confocal microscopy (IVCM) revealed damages of small corneal nerve fibers which may be consistent with a diagnosis of neuropathic corneal pain (NCP). Subsequently, a diagnosis of painful small fiber neuropathy (SFN) was confirmed by a positive serum IgM binding to trisulfated heparin disaccharide (TS-HDS) using an ELISA method.

### **History**

A 48-year-old female presented with chronic burning pain and foreign body sensation in both eyes. Her symptoms were not relieved with frequent topical lubrication. She has no history of Sjogren's syndrome, Lupus, Rheumatoid Arthritis or other autoimmune diseases, also no significant past medical and surgical history, and no ocular history except the diagnosis of dry eye disease.

### **Examination**

On ophthalmic examination, the uncorrected visual acuity was 20/20 in both eyes. Slit-lamp examination revealed clear corneas bilaterally. A drop of 1% fluorescein stain from a fluorescein strip instilled in the conjunctival cul-de-sac revealed a few punctate epithelial erosions on cornea bilaterally. The tear film height was normal in both eyes. The tear film breakup time was 7

seconds in the right eye and 8 seconds in the left eye. The Schirmer test score without anesthetic was 30 mm at 5 minutes in both eyes, and with 0.5% proparacaine hydrochloride was 25 mm in the right eye and 26 mm in the left eye. Lissamine green stain did not reveal any staining.

In vivo confocal microscopy (IVCM) revealed reduced corneal fiber density, corneal nerve branch density, corneal nerve fiber length, and increased corneal fiber tortuosity and immune dendritic cells in both eyes compared to the exam four years ago. (Figure 1) Her serum was tested positive for IgM antibodies against trisulfated heparin disaccharide (TS-HDS). She was referred to see Neurology for co-management.

### **Discussion and diagnosis**

Small fiber neuropathy (SFN) is due to injury to the small unmyelinated C or thinly myelinated (A $\delta$ ) nerve fibers, which involve both sensory and autonomic functions.<sup>1,2</sup> SFN commonly presents with disabling symptoms due to neuropathic pain and autonomic dysfunction. The diagnosis of SFN requires confirmation of injury or disease affecting the somatosensory pathway of either peripheral and or central nervous systems.<sup>3</sup>

One of the recently identified antibodies in SNF patients is IgM binding to TS-HDS.<sup>4</sup> It has been concluded that serum antibody against TS-HDS is associated with painful, primarily sensory, non-length polyneuropathy with more common symptoms of hand discomfort, presence of IgM M-proteins, and evidence of capillary pathology. Serum IgM against TS-HDS is considered a marker for a possible dysimmune etiology of SNF.<sup>5</sup>

SFN can involve the cornea, the most densely innervated tissue in the body, and presents with eye pain.<sup>6-10</sup> However, neuropathic corneal pain (NCP), also termed corneal neuralgia, is currently an ill-defined disease that is not commonly recognized. Diagnosing NCP has been challenging for vision care providers, partly due to the lack of understanding of this disease, as well as due to minimal or absent clinical signs, thus masking the underlying condition. Symptoms of NCP include pain, aching, burning, irritation, dryness, and grittiness, which is often misdiagnosed as dry eye disease. A diagnosis of NCP was considered because the symptoms were out of proportion compared with objective findings, and the response to topical

therapy was poor. In addition, patients with NCP are extremely challenging to manage given there is a lack of evidence-based clinical recommendations for the management of patients with NCP.

IVCM is a non-invasive high-resolution real-time imaging device and can be informative as to the neuropathic basis of this condition. The corneal nerve fibers originate from the ophthalmic branch of the trigeminal nerve, which can be visualized by confocal microscopy. There was a correlation between the corneal nerve fiber loss detected by confocal microscopy and the severity of diabetic polyneuropathy <sup>11, 12</sup>, multiple sclerosis <sup>13</sup>, sarcoidosis. <sup>14</sup> This patient had no history of the aforementioned diseases. The advantages of IVCM include quantitative and non-invasive measurements compared to skin biopsy.

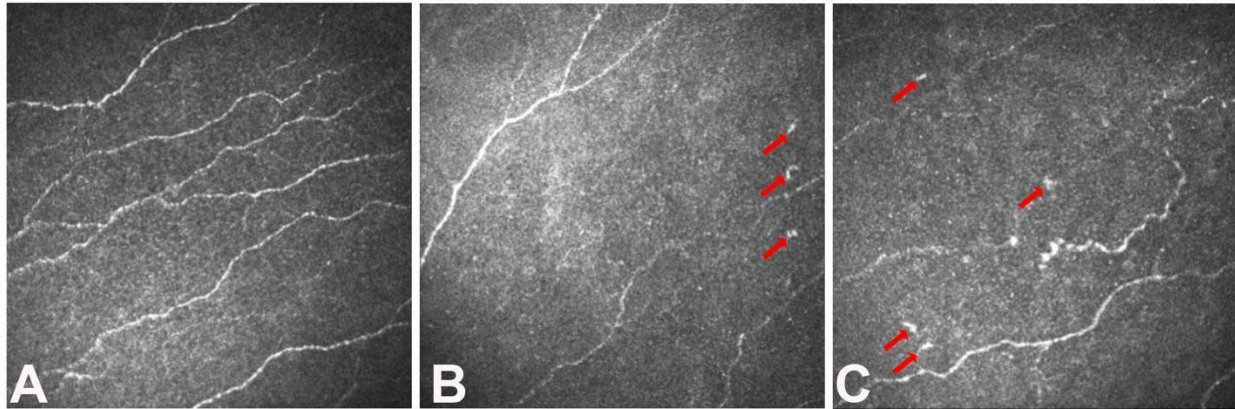
## **Conclusion**

NCP should be considered when patients present with pain, aching, burning, irritation, dryness, and grittiness, which are out of proportion compared with exam findings. These patients may also be poor responders to topical therapy. SFN should be suspected in patients with wide-spread body pain. In cases with systemic symptoms, referral to neurologists is suggested for further systemic somatosensory testing. Intravenous immunoglobulin (IVIg) therapy has been demonstrated as an effective therapy in patients with SFN secondary to fibromyalgia. <sup>15</sup> Therefore, IVIg holds promise as a potential treatment for patients with NCP.

IVCM is a non-invasive imaging technique that quantifies corneal nerve fiber density, branch density, and length, and has comparable, even possibly superior, ability to identify small nerve damage compared to skin biopsy. It also has potential utility for monitoring disease progression and response to treatment in patients with NCP and SFN. Autoantibodies directed against TS-HDS can be used as a diagnostic test for autoimmune SFN, which will justify and guide the treatment plan.

### Figure 1

Corneal confocal microscopic images of the corneal nerve plexus showed reduced corneal fiber density, corneal nerve branch density, corneal nerve fiber length, with increased corneal fiber tortuosity and dendritic cells (red arrows) (B and C) compared to her image from 2016 (A).



## References:

1. Hovaguimian A, Gibbons CH. Diagnosis and treatment of pain in small-fiber neuropathy. *Curr Pain Headache Rep* 2011;15:193–200.
2. Tavee J, Zhou L. Small fiber neuropathy: A burning problem. *Cleve Clin J Med* 2009;76:297–305.
3. Jensen TS, Baron R, Haanpää M, et al. A new definition of neuropathic pain. *Pain* 2011;152:2204–2205.
4. Pestronk A, Schmidt RE, Choksi RM, et al. Clinical and laboratory features of neuropathies with serum IgM binding to TS-HDS. *Muscle Nerve* 2012;45:866–872.
5. Farhad K. Current Diagnosis and Treatment of Painful Small Fiber Neuropathy. *Curr Neurol Neurosci Rep* 2019;19:103.
6. Rosenthal P, Borsook D. The corneal pain system. Part I: the missing piece of the dry eye puzzle. *Ocul Surf* 2012;10:2–14.
7. Rosenthal P, Borsook D. Ocular neuropathic pain. *Br J Ophthalmol* 2016;100:128–134.
8. Rosenthal P, Borsook D, Moulton EA. Oculofacial Pain: Corneal Nerve Damage Leading to Pain Beyond the Eye. *Invest Ophthalmol Vis Sci* 2016;57:5285–5287.
9. Aggarwal S, Kheirkhah A, Cavalcanti BM, et al. Autologous Serum Tears for Treatment of Photoallodynia in Patients with Corneal Neuropathy: Efficacy and Evaluation with In Vivo Confocal Microscopy. *Ocul Surf* 2015;13:250–262.
10. Hamrah P, Qazi Y, Shahatit B, et al. Corneal Nerve and Epithelial Cell Alterations in Corneal Allodynia: An In Vivo Confocal Microscopy Case Series. *Ocul Surf* 2017;15:139–151.
11. Tavakoli M, Quattrini C, Abbott C, et al. Corneal confocal microscopy: a novel noninvasive test to diagnose and stratify the severity of human diabetic neuropathy. *Diabetes Care* 2010;33:1792–1797.
12. Petropoulos IN, Alam U, Fadavi H, et al. Corneal nerve loss detected with corneal confocal microscopy is symmetrical and related to the severity of diabetic polyneuropathy. *Diabetes Care* 2013;36:3646–3651.
13. Bitirgen G, Akpınar Z, Malik RA, Ozkagnici A. Use of Corneal Confocal Microscopy to Detect Corneal Nerve Loss and Increased Dendritic Cells in Patients With Multiple Sclerosis. *JAMA Ophthalmol* 2017;135:777–782.
14. Parambil JG, Tavee JO, Zhou L, et al. Efficacy of intravenous immunoglobulin for small fiber neuropathy associated with sarcoidosis. *Respir Med* 2011;105:101–105.
15. Metyas S, Chen C, Quismorio A, et al. Improvement in Fibromyalgia Symptoms and Skin Biopsy Results in Patients with Fibromyalgia Related Small Fiber Neuropathy. *Curr Rheumatol Rev* 2019. Nov 6.