

Bilateral chronic bacterial conjunctivitis in giant fornix syndrome

Resident author: Patrick Commiskey, MD¹

Medical student assistant: Eve M.R. Bowers, BA¹

Faculty mentor: Alex Mammen, MD¹

¹University of Pittsburgh Medical Center Eye Clinic, Pittsburgh, PA

Abstract:

A 98-year-old woman was referred to cornea clinic for bilateral persistent corneal epithelial defects and chronic discharge unresponsive to varying combination of artificial tears, topical antibiotic drops and ointment, topical steroids, and amniotic membrane grafts.

The patient was found to have deep-set orbits with giant fornices, paracentral 1 mm epithelial defects, and a purulent conjunctivitis culture-positive for *Staphylococcus aureus*. Over the next two months, she responded to a combination of topical and systemic antibiotics, autologous serum eye drops, povidone iodine forniceal rinses, and hypochlorous acid treatment of the eyelashes. Giant fornix syndrome (GFS) remains an important diagnostic consideration in elderly patients with chronic conjunctivitis and deep-set orbits.

History

A 98-year-old woman presented on referral from an outside ophthalmologist diagnosed with chronic bilateral dry eyes, persistent epithelial defects, and relapsing episodes of copious mucus discharge and worsening eyelid apraxia. She denied contact lens use, mucus fishing, chronic sinusitis, or autoimmune disease. Her past medical history was notable for hypertension, hypothyroidism, heart failure, and dementia. Her medications included amlodipine, donepezil, escitalopram, irbesartan, levothyroxine, sotalol, and valsartan. Past ocular history was notable for cataract surgery in the remote past and amniotic membrane grafts two months prior to presentation. Her ocular medications were preservative free artificial tears every hour, besifloxacin drops twice each day, and erythromycin ointment at night.

Examination

At presentation, her vision was counting fingers at one foot in the right eye (OD) and two feet in the left eye (OS). Pupils and intraocular pressure were normal. Anterior segment examination was notable for bilateral deep-set eyes, deep fornices, 2+ diffuse conjunctival injection with papillary reaction and purulent discharge, and paracentral 1 mm cornea epithelial defects with minimal thinning. **[Fig. 1]** Conjunctival smears revealed polymorphonuclear cells and gram-positive cocci in clusters. A computer tomography (CT) scan of the head from five years prior demonstrated normal orbital bony anatomy, well-aerated sinuses, and a pocket of air deep in the upper fornix of the left eye **[Fig. 2]**.

Discussion and Diagnosis

The patient was diagnosed with giant fornix syndrome (GFS), an unusual ocular condition caused by a nidus of infectious material caught in the “dead space” of a large superior fornix that can result in chronic conjunctivitis, keratopathy, nasolacrimal duct obstruction,¹ and eyelid apraxia. GFS may be mistaken for severe dry eyes, conjunctivitis, or floppy eyelid syndrome, and may respond initially to topical therapy, making diagnosis challenging.² It was first described in 2004 at Moorfields Eye Hospital in a series of twelve predominantly female patients ages 77-93 years who presented with chronic relapsing conjunctivitis.³ It has subsequently been reported in several small case series,⁴⁻⁷ and published as “senile sunken upper eyelids⁸.” Eyelid opening apraxia may be secondary to irritation from infectious material in the fornix. The spasm may resolve with successful treatment of the underlying condition, or with supplemental botulinum toxin injection.³ There is significant overlap between GFS, silent sinus syndrome (SSS)^{9,10} and the severe form silent brain syndrome (SBS),¹¹ collectively referred to as the enophthalmos syndromes. Suggestive features on CT scan are enophthalmos and air bubble under the superior eyelid.¹² **[Fig. 2]** Accurate measurement of the fornix depth may help assist in diagnosis and monitor disease progression.¹³

Treatment of GFS focuses on removal of offending material from the fornix, application of topical antibiotic, optimization of ocular surface, treating complications such as NLDO and corneal neovascularization, and at times, restoration of physiologic fornix with eyelid fillers or fornix reconstruction.² Doxycycline is a commonly-used oral adjunct to topical therapy. While *Staphylococcus aureus* is the most common bacterium implicated in GFS, culture of the fornix may be helpful in picking up less-common *MRSA* and *pseudomonas* species.⁴ GFS with *MRSA* may respond well to systemic minocycline.¹⁴

Povidone-iodine 5% eyedrops are an effective, safe, and inexpensive antiseptic that have been shown to effectively treat GFS. It is often combined with manual debridement of the fornix.¹⁵ The drops can be self-administered, which helps to mitigate frequent outpatient visits for irrigation and fornix sweeping, and are less toxic and equally effective as the povidone-iodine 10% solution.¹⁶ Povidone-iodine 10% irrigation has been described for treatment of GFS after failed topical antibiotics and steroids.¹⁷ Subtarsal or subconjunctival injection of antibiotics and corticosteroids have also been described for GFS patients who have failed aggressive topical and systemic treatments¹⁸.

Chronic, relapsing GFS resistant to medical and mechanical therapy can be corrected surgically with 4-5 mm of fornix reconstruction under local anesthesia. This process minimizes superior fornix dead space and potential nidus for infection. In a case series of six patients, 83% of patients reported complete resolution of symptoms and all reported symptomatic improvement by 18 months.^{19,20,21} Hyaluronic acid gel has been described as an alternative for functional treatment of GFS. Like surgical correction, this minimally-invasive injection shortens the superior fornix to eliminate dead space.²² Our patient was treated with sweeping of her fornices with saline-moistened cotton tipped applicators followed by besifloxacin drops,

bacitracin ointment, autologous serum drops, and oral doxycycline initially. The conjunctival cultures came back as methicillin-susceptible *Staphylococcus aureus*.

After resolution of her epithelial defects at 2 weeks, her fornices were swept and rinsed with 5% povidone iodine due to mild persistent purulent discharge. Hypochlorous acid sprays and foam were prescribed to reduce the microbial flora on her eyelids and eyelashes. She was noted to be clear of purulent discharge at 3.5 weeks. A 2.5-week course of topical loteprednol drops were added to address residual inflammation.

At eight weeks [Fig. 3], she was back to her baseline level of vision in both eyes (OD 20/50 and OS counting fingers at 2 feet) with her vision limited by bullous keratopathy in left > right eyes and corneal scarring from her persistent epithelial defects. Her ocular discomfort and eyelid apraxia were markedly decreased. She has been maintained on a regimen of saline rinses of her fornices twice daily, autologous serum drops, sodium chloride ointment at night, and oral doxycycline every other day without recurrence of her conjunctivitis for a follow-up period of 3 months.

Conclusion

Giant fornix syndrome remains an important differential diagnosis for elderly patients with chronic conjunctivitis and deep-set eyes. Sweeping of the fornices with povidone iodine, treatment with appropriate topical and oral antibiotics, management of the ocular surface, and if need be, surgical management, are important therapeutic considerations that can help prevent progression to severe keratopathy and nasolacrimal duct obstruction.

Figures

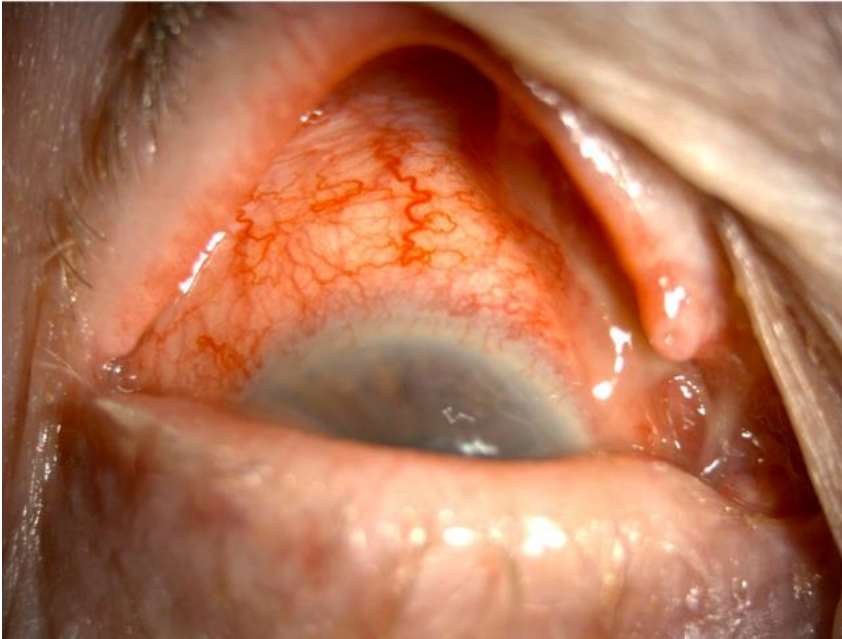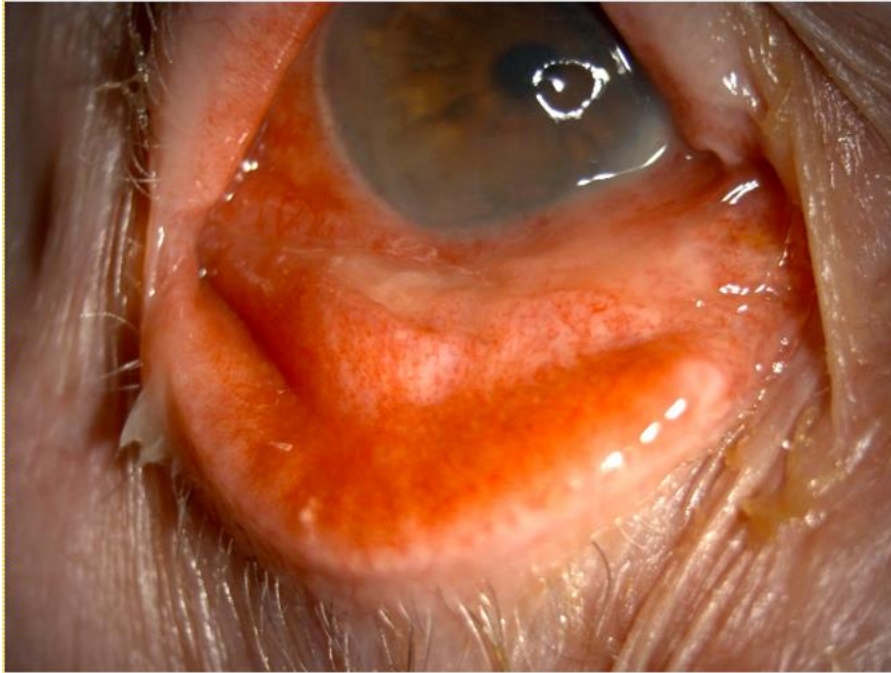


Figure 1: External photographs of the right eye at the time of initial presentation demonstrating deep fornix, diffuse conjunctival hyperemia, and purulent discharge

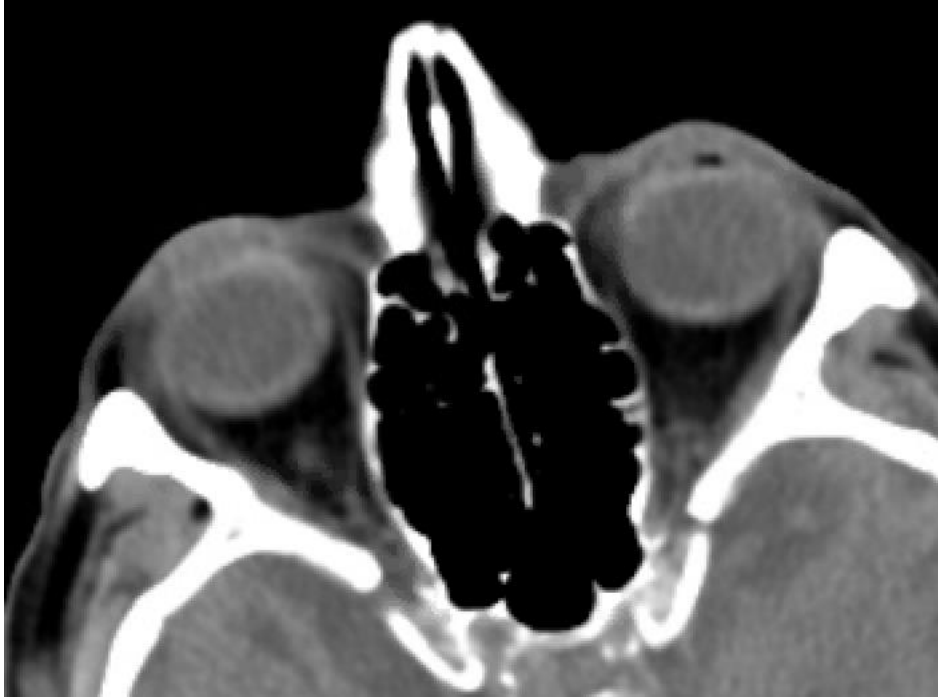

Figure 2: Axial CT scan from 5 years prior to presentation demonstrating

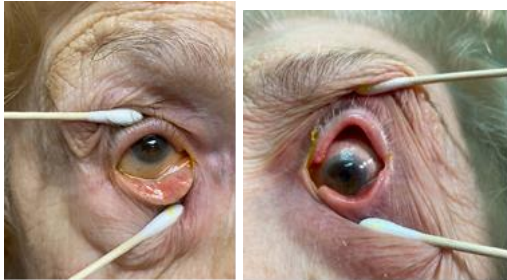

Figure 3: External photographs of the bilateral eyes at eight weeks from initial presentation demonstrating much improved conjunctival injection and resolved discharge. You can still appreciate the deep fornices and eyelid laxity.

References

1. Lever J, Eubanks E, Gupta C, Barmettler A, Servat JJ, Nesi-Eloff F. Giant fornix syndrome with chronic methicillin resistant staphylococcus aureus conjunctivitis causing nasal lacrimal duct obstruction. *Investigative Ophthalmology & Visual Science*. 2013;54(15):5348-5348.
2. Varu DM, Rhee MK, Akpek EK, et al. Conjunctivitis Preferred Practice Pattern(R). *Ophthalmology*. 2019;126(1):P94-P169.
3. Rose GE. The giant fornix syndrome: an unrecognized cause of chronic, relapsing, grossly purulent conjunctivitis. *Ophthalmology*. 2004;111(8):1539-1545.
4. Turaka K, Penne RB, Rapuano CJ, et al. Giant Fornix Syndrome: A Case Series. *Ophthalmic Plastic & Reconstructive Surgery*. 2012;28(1):4-6.
5. Gupta S, Prasad TSB. Giant fornix syndrome. *BMJ*. 2015;351:h6274.
6. Beuste T, Abadie C, Mouriaux F, Blanchardière A. Giant fornix syndrome: Case report and literature review. *Journal Français d'Ophthalmologie*. 2016;39.
7. To J, Macsai M, Phelps PO. Chronic Conjunctivitis in an Older Patient With Ptosis. *JAMA Ophthalmology*. 2020;138(1):97-98.
8. Liang L, Sheha H, Fu Y, Liu J, Tseng SC. Ocular surface morbidity in eyes with senile sunken upper eyelids. *Ophthalmology*. 2011;118(12):2487-2492.
9. Langer PD, Patel BC, Anderson RL. Silent sinus syndrome. *Ophthalmology*. 1994;101(11):1763-1764.
10. Liss JA, Patel RD, Stefko ST. A case of bilateral silent sinus syndrome presenting with chronic ocular surface disease. *Ophthalmic Plast Reconstr Surg*. 2011;27(6):e158-160.
11. Chen JJ, Cohen AW, Wagoner MD, Allen RC. The "silent brain syndrome" creating a severe form of the "giant fornix syndrome". *Cornea*. 2012;31(9):1065-1067.
12. Turner SJ, Sharma V, Hunter PA. Giant fornix syndrome: a recently described cause of chronic purulent conjunctivitis and severe ocular surface inflammation, with a new diagnostic sign on CT. *Eye*. 2006;20(12):1481-1483.
13. Peden R, Hughes L, Wright M. An alternative method for upper and lower conjunctival fornix measurement. *Eye*. 2017;31(9):1380-1380.
14. Lee KW, Jung JW. Systemic Minocycline Treatment of Methicillin-resistant Staphylococcus aureus in Giant Fornix Syndrome. *Korean J Ophthalmol*. 2016;30(5):394-395.
15. Vahdani K, Rose GE. Topical Povidone-Iodine for Treatment of Giant Fornix Syndrome. *Ophthalmic Plast Reconstr Surg*. 2019;35(5):e114-e115.
16. Ta CN, Singh K, Egbert PR, de Kaspar HM. Prospective comparative evaluation of povidone-iodine (10% for 5 minutes versus 5% for 1 minute) as prophylaxis for ophthalmic surgery. *J Cataract Refract Surg*. 2008;34(1):171-172.
17. Karim R, Mandal N, Tuft S. Management of giant fornix syndrome with irrigation with povidone-iodine. *BMJ Case Rep*. 2018;2018.
18. Taylor JB, Fintelman RE, Jeng BH. Subconjunctival injections and povidone-iodine washings for the treatment of giant fornix syndrome. *Cornea*. 2011;30(4):479-480.
19. Farmer LD, Rajak SN, McNab AA, Hardy TG, Selva D. Surgical Correction of Giant Fornix Syndrome. *Ophthalmic Plast Reconstr Surg*. 2016;32(2):142-144.

20. Nabavi CB, Long JA, Compton CJ, Vicinanzo MG. A Novel Surgical Technique for the Treatment of Giant Fornix Syndrome. *Ophthalmic Plastic & Reconstructive Surgery*. 2013;29(1).
21. Vahdani K, Lim L-A, Thaller VT. Fornix Reduction for Treatment of Giant Fornix Syndrome. *Ophthalmic Plastic & Reconstructive Surgery*. 2016;32(4):313-314.
22. Taban MR, Shamie N. Use of hyaluronic acid gel filler to improve contact lens wear in patients with deep sunken superior sulcus. *J Curr Ophthalmol*. 2018;30(4):374-376.