

## **Sterile corneal perforation following corneal collagen cross-linking in a patient with Down syndrome**

Resident: Jacob D. Grodsky, MD<sup>1</sup>

Faculty mentor: Sean Edelstein, MD<sup>1</sup>

<sup>1</sup>Saint Louis University Department of Ophthalmology, Saint Louis, MO

### **Abstract**

An 18-year old male with history of Down syndrome (DS), hypothyroidism, obstructive sleep apnea, asthma, seasonal allergies, and congenital heart disease presented with blurry vision and pain OD. Examination revealed bilateral floppy eyelid syndrome and corneal ectasia, as well as acute hydrops OD.

Medical management included 5% sodium chloride drops, prophylactic antibiotic ointment, and counselling against eye rubbing and to wear a Fox shield when sleeping. Worsening hydrops OD prompted intracameral injection of 20% SF<sub>6</sub> gas which hastened resolution of edema within 3 weeks. Residual severe corneal scarring, however, limited visual improvement to light perception. Meanwhile, progressive ectasia OS prompted epi-off corneal collagen crosslinking (CXL) procedure. Sterile corneal perforation was noted four days following uneventful surgery, necessitating emergency tectonic penetrating keratoplasty and temporary tarsorrhaphy. This case illustrates that patients with DS and keratoconus are at especially high risk for rapidly progressive disease and for surgery-related complications. Sterile corneal perforation is an uncommon complication after epi-off CXL.

## History

An 18-year-old African American male with Down syndrome presented with blurry vision, pain, increased tearing, and redness OD. Past medical history was significant for hypothyroidism, obstructive sleep apnea without current use of CPAP, asthma, seasonal allergies, and congenital heart disease s/p repair of ventricular septal defect. Past ocular history included strabismus surgery to correct esotropia.

## Examination

Baseline intraocular pressure measurements were 20 mmHg OD and 16 mmHg OS. Floppy eyelids and allergic facies were noted bilaterally. Figure 1 illustrates corneal ectasia with central hydrops OD (UCVA light perception), which progressed to affect over 80% of the cornea at follow-up, and residual corneal scar formation with resolution of the hydrops (UCVA unchanged) following intracameral SF<sub>6</sub> injection.

Progression of disease in the contralateral left eye was documented utilizing Placido ring corneal topography (Figure 2). Initial UCVA 20/60 on the left worsened to 20/100 preceding epi-off CXL treatment.

## Discussion and Diagnosis

Keratoconus is a progressive, bilateral, corneal ectasia in which there is stromal thinning and apical protrusion of the cornea resulting in irregular astigmatism.<sup>1,2</sup> Our patient displayed several typical features associated with keratoconus, which include disease presentation around puberty with progression into the third or fourth decade of life or later, as well as a disproportionately high association with Down syndrome, atopic disease/allergies, obstructive sleep apnea, and connective tissue disorders.<sup>3</sup> Pathogenesis theories associated with keratoconus include degradation of collagen content in the cornea, keratocyte apoptosis and decreased keratocyte cell density, oxidative stress, and altered enzyme activity including increased levels of proinflammatory cytokines IL-6 and TNF- $\alpha$ .<sup>4,5</sup>

Corneal hydrops occurs in about 3% of keratoconic eyes and results from rupture of Descemet's membrane (DM), causing subsequent stromal hydration and edema.<sup>6-8</sup> Resolution of hydrops is often very slow despite treatment with topical hypertonic saline and antibiotic or steroid eyedrops to prevent infection, as was utilized in our patient. Pneumatic descemetopexy was first described in 1987 by Zusman et al.<sup>9</sup> to speed up recovery and with questionable vision benefit. Intracameral injection of air or gas (SF<sub>6</sub> or C<sub>3</sub>F<sub>8</sub>) is used to stretch and tamponade the detached DM, thus preventing further aqueous penetration and corneal edema.<sup>8,9</sup> Our patient experienced rapid resolution of corneal edema within 3 weeks following 20% SF<sub>6</sub> injection, however, significant residual corneal scarring limited vision benefit. Potential risks discussed with our patient included risk of general anesthesia, ocular hypertension with pupillary block, and risk for potentiating cataract formation.

Progression of disease in the contralateral eye prompted recommendation for our patient to undergo epi-off CXL, a procedure first described by Wollensak et al.<sup>10</sup> in 2003 and receiving FDA-approval in 2016 for halting progression of corneal ectatic disease.<sup>11</sup> The premise of this

procedure is to stiffen the cornea by creating new corneal collagen cross-links following application of riboflavin (vitamin B2) drops and stromal exposure to ultraviolet A light.<sup>10,12,13</sup> Our patient experienced a 6 month delay in getting epi-off CXL after progression had been documented due to public aid insurance issues. Four days following epi-off CXL performed utilizing topical anesthesia, the patient's mother called noting a bubble had formed on the operated eye (Figure 3), but no associated redness, pain, or drainage. Slit-lamp exam revealed a 4mm central perforated ulcer without stromal infiltrate, Seidel positive leak, and a shallow anterior chamber (Figure 3). Attempted glue patch was unsuccessful, and an emergency tectonic penetrating keratoplasty with temporary tarsorrhaphy was performed that same evening. Significant improvement in vision was noted, and UCVA was 20/60 OS at 4-month follow-up.

Corneal perforation is a rare complication following CXL and has been reported in 10 eyes, including 6 cases of sterile keratolysis and 4 cases of microbial keratitis.<sup>14-18</sup> A report in German by Faschinger et al.<sup>17</sup> described bilateral corneal melt in a patient with DS with baseline central corneal thickness < 400 mm. Müller et al.<sup>19</sup> found that histological changes following CXL included possible permanent keratocyte loss or repopulation of altered keratocytes as a mechanism leading to diminished stromal remodeling and sterile melt.

### Conclusion

Keratoconus may be rapidly progressive in younger patients, therefore close monitoring and early intervention with CXL may be prudent. Suitable CXL candidates should be educated that although the procedure is generally benign, it is not without potential significant risk and may require keratoplasty. Patients with DS may be considered at especially high risk for rapidly progressive disease and for surgery-related complications. Sterile corneal perforation is an uncommon complication after epi-off CXL.

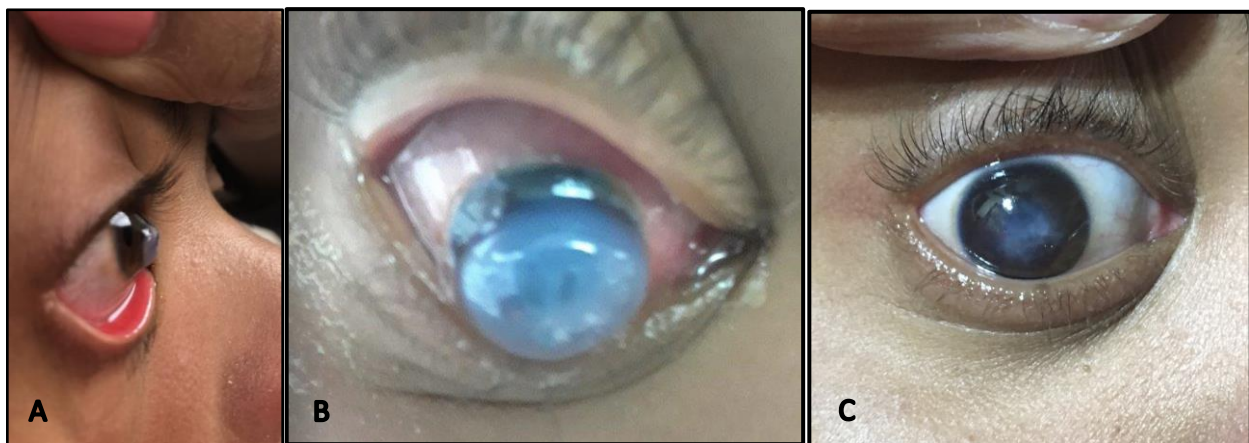


Figure 1: External photographs of the right eye: (A) acute hydrops affecting central  $\frac{1}{3}$  of the cornea (at presentation), (B) progression to involve 80% of the cornea (10 days later), and (C)

resolution of hydrops with residual corneal scarring following intracameral SF<sub>6</sub> injection (3 months later).

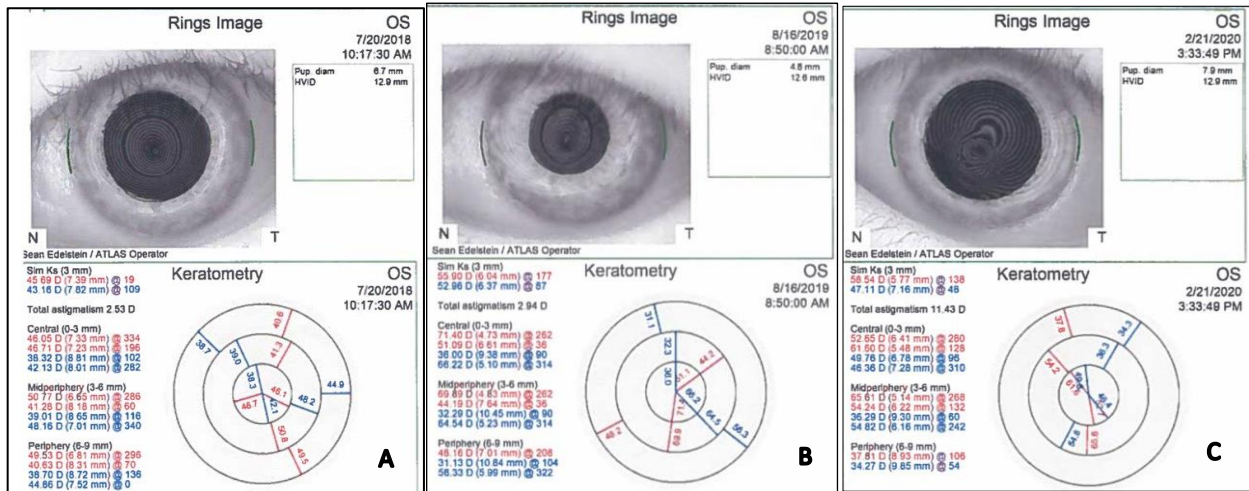


Figure 2: Placido ring corneal topography of the contralateral left eye illustrating progressive disease. SimK and Kmax values increased from (A) 45/43D and 50.8D, to (B) 55/52D and 71D, to (C) to 58/47 and 65D. Significant sequential worsening in distortion of the mires is appreciated.

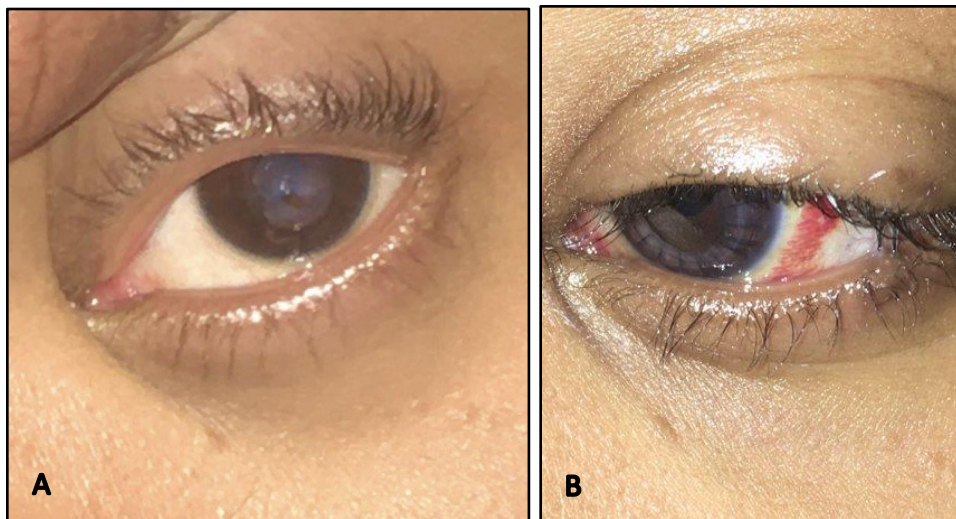


Figure 3: External photographs of the left eye: (A) sterile corneal perforation occurring four days following epi-off CXL, and (B) emergency tectonic corneal transplant with temporary tarsorrhaphy.

## References

1. Zadnik K, Barr JT, Edrington TB, Everett DF, Jameson M, McMahon TT, et al. Baseline findings in the Collaborative Longitudinal Evaluation of Keratoconus (CLEK) Study. *Invest Ophthalmol Vis Sci*. 1998 Dec;39(13):2537–46.
2. Kanski J, Bowling B. Kanski's Clinical Ophthalmology A Systemic Approach. In: *Elsevier Health Sciences*. 9th ed. Elsevier; 2020. p. 248–50.
3. Rabinowitz YS. Keratoconus. *Surv Ophthalmol*. 1998 Jan;42(4):297–319.
4. Sugar J, Macsai MS. What Causes Keratoconus? *Cornea*. 2012 Jun;31(6):716–9.
5. Lema I, Durán J. Inflammatory Molecules in the Tears of Patients with Keratoconus. *Ophthalmology*. 2005 Apr;112(4):654–9.
6. Panda A, Aggarwal A, Madhavi P, Wagh VB, Dada T, Kumar A, et al. Management of Acute Corneal Hydrops Secondary to Keratoconus With Intracameral Injection of Sulfur Hexafluoride (SF6). *Cornea*. 2007 Oct;26(9):1067–9.
7. Sii F, Lee GA, Gole GA. Perforated Corneal Hydrops Treated With Sulfur Hexafluoride (SF6) Gas and Tissue Adhesive. *Cornea*. 2005 May;24(4):503–4.
8. Miyata K, Tsuji H, Tanabe T, Mimura Y, Amano S, Oshika T. Intracameral air injection for acute hydrops in keratoconus. *Internet Advance publication at ajo.com* March 7, 2002. *Am J Ophthalmol*. 2002 Jun;133(6):750–2.
9. Zusman NB, Iii GOW, Najarian L V., Wilson LA. Sulfur Hexafluoride Gas in the Repair of Intractable Descemet's Membrane Detachment. *Am J Ophthalmol*. 1987 Dec;104(6):660–2.
10. Wollensak G, Spoerl E, Seiler T. Riboflavin/ultraviolet-a–induced collagen crosslinking for the treatment of keratoconus. *Am J Ophthalmol*. 2003 May;135(5):620–7.
11. Kobashi H, Rong SS. Corneal Collagen Cross-Linking for Keratoconus: Systematic Review. *Biomed Res Int*. 2017;2017:1–7.
12. Beshtawi IM, O'Donnell C, Radhakrishnan H. Biomechanical properties of corneal tissue after ultraviolet-A–riboflavin crosslinking. *J Cataract Refract Surg*. 2013 Mar;39(3):451–62.
13. Kamaev P, Friedman MD, Sherr E, Muller D. Photochemical Kinetics of Corneal Cross-Linking with Riboflavin. *Investig Ophthalmology Vis Sci*. 2012 Apr 30;53(4):2360.
14. Mohamed-Noriega K, Butrón-Valdez K, Vazquez-Galvan J, Mohamed-Noriega J, Cavazos-Adame H, Mohamed-Hamsho J. Corneal Melting after Collagen Cross-Linking for Keratoconus in a Thin Cornea of a Diabetic Patient Treated with Topical Nepafenac: A Case Report with a Literature Review. *Case Rep Ophthalmol*. 2016 Feb 26;7(1):119–24.
15. Gokhale NS, Vemuganti GK. Diclofenac-induced Acute Corneal Melt After Collagen Crosslinking for Keratoconus. *Cornea*. 2010 Jan;29(1):117–9.
16. Labiris G, Kaloghianni E, Koukoula S, Zissimopoulos A, Kozobolis VP. Corneal melting after collagen cross-linking for keratoconus: a case report. *J Med Case Rep*. 2011 Dec 16;5(1):152.
17. Faschinger C, Kleinert R, Wedrich A. Corneal melting in both eyes after simultaneous corneal cross-linking in a patient with keratoconus and Down syndrome [in German]. *Ophthalmologe*. 2010 Oct 9;107(10):951–5.
18. Angunawela RI, Arnalich-Montiel F, Allan BDS. Peripheral sterile corneal infiltrates and

melting after collagen crosslinking for keratoconus. *J Cataract Refract Surg.* 2009 Mar;35(3):606–7.

19. Müller PL, Loeffler KU, Messmer E, Holz FG, Perdikakis G, Kohlhaas M, et al. Histological Corneal Alterations in Keratoconus After Crosslinking—Expansion of Findings. *Cornea.* 2020 Mar;39(3):333–41.