

Hydroxyurea-Induced Limbal Stem Cell Deficiency Treated with Keratolimbal Allograft

Resident: Corey J. Miller, MD¹

Faculty Mentor: Joshua H. Hou, MD¹

¹University of Minnesota Department of Ophthalmology and Visual Neurosciences, Minneapolis, MN

Abstract

A 45-year-old male with a history of sickle cell beta thalassemia was referred for bilateral corneal scarring and haze. Initial exam findings notable for diffuse bilateral corneal scarring and conjunctivalization with reduced visual acuity. History was notable for prior treatment with hydroxyurea (hydroxycarbamide) for sickle cell disease, followed by onset of progressive, bilateral limbal stem cell deficiency (LSCD) a year later. Patient's exam and history were consistent with hydroxyurea-induced LSCD. He underwent keratolimbal allografting (KLAL) with good results. Based on our review of the literature, only two cases of this condition have been reported, and only one case has been reported in a patient with sickle cell disease. Furthermore, to the best of our knowledge, use of KLAL to treat hydroxyurea-induced LSCD in sickle cell patients has never been reported. This case highlights a rare but potentially important cause of LSCD and the role of KLAL surgery in management.

History

A 45-year-old male with a history of sickle cell beta thalassemia was referred for bilateral corneal scarring and haze. The patient reported onset of corneal haze and scarring ten years prior, which was first noted one year after initiation of oral hydroxyurea for management of sickle cell beta thalassemia. He had no prior ocular history and was not using any topical ophthalmic medications. On initial diagnosis at an outside facility, he underwent a superficial keratectomy; however, after recurrent conjunctivalization and scarring, KLAL was recommended. Due to lack of insurance, patient was lost to follow-up for several years before presenting to our clinic with progressive worsening of vision.

Examination

On initial exam, patient's best corrected visual acuity was count fingers at two feet in the right eye and 20/50 in the left eye. Intraocular pressure was normal in each eye. Anterior segment exam (Fig. 1) was notable for diffuse subepithelial scarring with complete corneal conjunctivalization in right eye. Prominent peripheral conjunctivalization with peri-central subepithelial scar tissue were noted in the left eye. No Arlt line was seen on everted eyelid exam. B-scan ultrasound of the right eye was unremarkable. Fundus exam of the left eye showed nonspecific pigmentary changes but was otherwise normal.

Discussion and Diagnosis

Hydroxyurea, also known as hydroxycarbamide, is an oral anti-neoplastic medication commonly used in the management of sickle cell disease. In sickle cell disease, use of hydroxyurea has been shown to decrease pain episodes, acute chest syndrome, hospital admissions and the need for blood transfusions.¹⁻² LSCD as a result of hydroxyurea use is a rare side effect with only two reported cases in the literature.³⁻⁴

Hydroxyurea-induced LSCD was first described in 2001 by Ellies, et al.³ They reported a case of a 68-year-old male with chronic myelocytic leukemia that presented with a bilateral keratitis after 2 years of treatment with hydroxyurea. The corneal findings partially resolved with stopping hydroxyurea but returned on re-initiation of the medication. Ultimately the patient developed LSCD that was confirmed with both impression cytology and histopathology. The patient failed amniotic membrane transplant and subsequently underwent KLAL surgery.

A second case of hydroxyurea-induced LSCD was described in 2009 by Ding, et al.⁴ They reported a 49-year-old female with sickle cell disease who also developed LSCD from hydroxyurea use. They noted earlier involvement of the superior limbus than the inferior limbus, which they attributed to the presence of more active stem cells superiorly.⁵ After the patient died, postmortem histological evaluation of the ocular tissues confirmed the diagnosis.

Although both cases demonstrate a link between Hydroxyurea use and the development of LSCD, little is known about the exact pathogenesis, risk factors and prognosis for this condition. Ellis, et al. hypothesized that the cytotoxic effects of hydroxyurea are responsible for the LSCD.³ Ding, et al. hypothesized that low penetrance of systemic medication to the avascular cornea underlies the rarity of LSCD after systemic anti-neoplastic medication use.⁴

In our patient, the lack of other confounding ocular or medical history, timing of onset relative to initiation of systemic hydroxyurea, and examination findings of bilateral LSCD led to the presumed diagnosis. The significant subepithelial scarring was attributed to the previous, failed superficial keratectomies that were performed prior to presentation. Due to the bilateral and extensive disease, autografting options were not possible. Since, no living-related donor was identified, the patient underwent KLAL with AMT and a temporary tarsorrhaphy in the right eye. Postoperative immunosuppression was achieved with topical prednisolone acetate 1% and oral mycophenolate mofetil, tacrolimus, and prednisone. Surgical pathology was consistent with LSCD and corneal fibrosis.

At post-operative month six, best corrected visual acuity was 20/25 in the right eye with normal intraocular pressure. Anterior segment exam (Fig. 2) showed a well-healed graft with clear central cornea. There was no evidence of rejection or recurrence. The patient subsequently underwent KLAL with AMT in the fellow eye with good results at post-operative month one. Shortly after, the patient suffered a severe stroke related to his sickle cell disease and was lost to follow-up. It remains unclear whether the patient's systemic immunosuppression contributed to the incidence and severity of his stroke.

Conclusion

We present a case of suspected hydroxyurea-induced LSCD managed with KLAL. LSCD is a rare complication of systemic hydroxyurea use with only two other cases reported in the literature at this time. Currently, little is known about the pathophysiology and management of this condition. Based on the case report by Ellies et al., cessation of the medication may be effective in reversing early keratopathy.³ However, later LSCD may require more aggressive treatments such as KLAL. To the best of our knowledge, this is the first reported use of KLAL for treatment of hydroxyurea-induced LSCD in a sickle cell patient. Although our patient had

good visual outcomes from KLAL, he ultimately suffered a major stroke. It is unclear whether the postoperative immunosuppression contributed to this adverse event. As such, caution should be exercised in performing KLAL in this population of patients. Overall, further reports and studies are needed to fully understand this condition and its management.

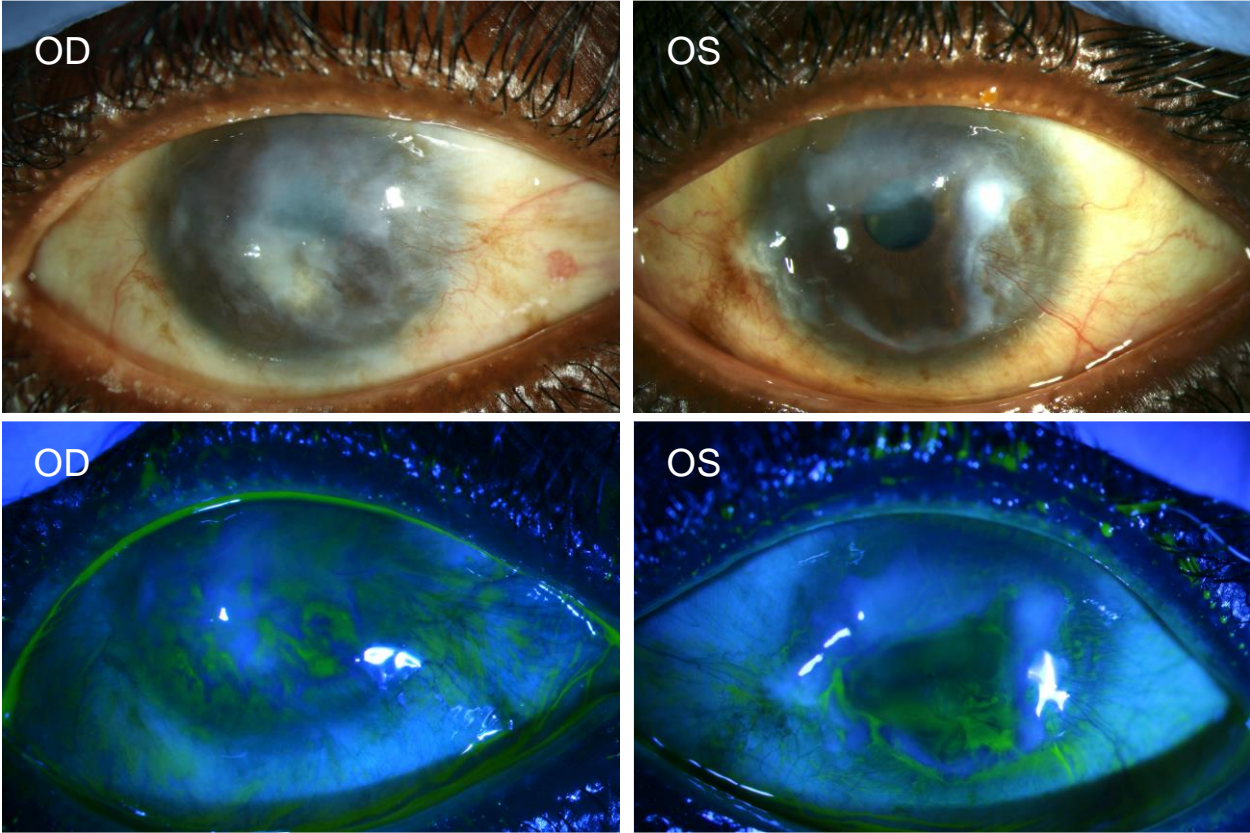


Figure 1. Slit lamp photos demonstrating bilateral limbal stem cell deficiency.

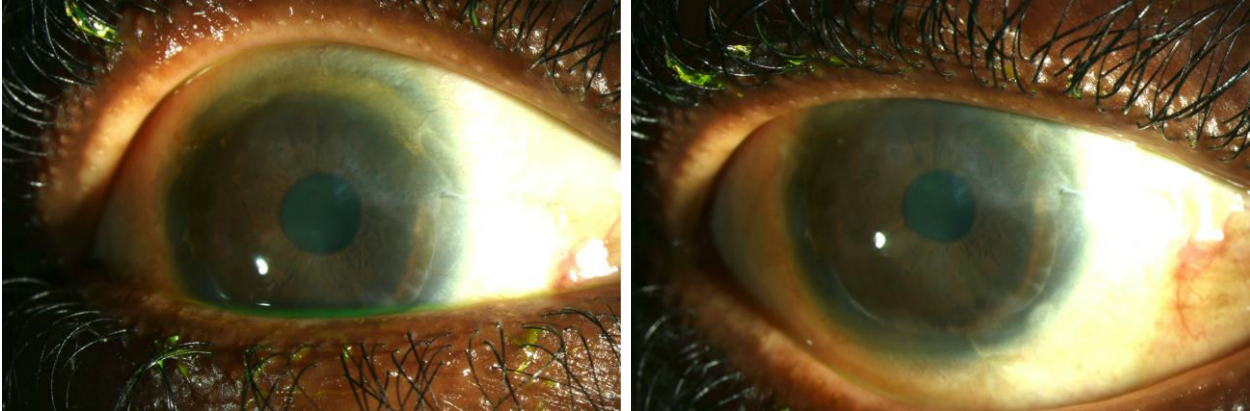


Figure 2. Slit lamp photos of the right eye at postoperative month six.

References

1. Nevitt SJ, Jones AP, Howard J. Hydroxyurea (hydroxycarbamide) for sickle cell disease. *Cochrane Database Syst Rev.* 2017;4(4):CD002202. Published 2017 Apr 20.
2. Meremikwu MM, Okomo U. Sickle cell disease. *BMJ Clin Evid.* 2016;2016:2402. Published 2016 Jan 22.
3. Ellies P, Anderson DF, Touhami A, Tseng SCG. Limbal stem cell deficiency arising from systemic chemotherapy. *Br J Ophthalmol* 2001;85(3):373–374.
4. Ding X, Bishop RJ, Herzlich AA, Patel M, Chan CC. Limbal stem cell deficiency arising from systemic chemotherapy with hydroxycarbamide. *Cornea* 2009;28(2):221-223.
5. Pellegrini G, Golisano O, Paterna P, Lambiase A, Bonini S, Rama P, De Luca M. Location and clonal analysis of stem cells and their differentiated progeny in the human ocular surface. *J Cell Biol* 1999;145:769–782.