

Granulomatosis with Polyangiitis: When the Labs Lie

Katherine Chuang, MD, Priyanka Parekh, MD, Ramana Moorthy, MD, Chi-Wah Yung, MD, Shaohui Liu, MD, PhD

Abstract

A 47-year-old African American woman was transferred from an outside hospital for further evaluation and management of unresponsive orbital cellulitis. While orbital inflammation initially improved with oral prednisone, rapidly progressive peripheral ulcerative keratitis and necrotizing scleritis were noted. After infectious causes were ruled out, diagnosis of granulomatosis with polyangiitis (GPA) was made despite negative c-ANCA and p-ANCA immunofluorescence assays. The patient was successfully treated with steroids, cyclophosphamide, and azathioprine with improvement in vision. This case demonstrates that if clinical presentation is consistent with vasculitis but serum ANCA testing is negative, vasculitis should remain on the differential as false negative test results can occur. It also highlights the importance of ruling out infectious causes of orbital inflammation while maintaining high clinical suspicion for non-infectious systemic vasculitis.

History

A 47-year-old African American woman was transferred from an outside hospital for further evaluation and management of a red and swollen left eye. She initially presented to an outside ophthalmologist with one and a half weeks of left eye redness and swelling, pain with eye movement, blurry vision, and floaters. She denied hemoptysis, hematuria, chest pain, joint pain, rash, and skin nodules. Past ocular history was significant for anterior uveitis, and past medical history was significant for hidradenitis suppurativa. Past surgical history, family history, and social history were noncontributory. She was diagnosed by an outside ophthalmologist with orbital cellulitis, and was admitted to an outside hospital for IV antibiotics. When her condition failed to improve after five days of antibiotic treatment and an MRI orbit was concerning for endophthalmitis, she was transferred to our hospital.

Visual acuity in the unaffected right eye was 20/20 and orbital and ophthalmic examinations were normal. Visual acuity in the left eye (OS) was hand motion. Pupil OS was fixed with afferent pupillary defect by reverse. Intraocular pressure was 25 OS. Extraocular motions were severely limited in all directions; there was severe ptosis, proptosis, lagophthalmos, conjunctival chemosis, and scleral injection. The slit lamp exam was limited due to severe eyelid edema and tight orbit. The cornea had punctate epithelial erosions inferiorly. The anterior chamber had 2+ cell and fibrin. The lens had 1+ nuclear sclerotic cataract and pigment on the anterior capsule. Dilated fundus exam and B scan were notable for serous retinal detachment. Labs were notable for white blood cell count 11.3 K/cumm (ref. 3.6-10.6 K/cumm), platelets 473 K/cumm (ref. 150-450 K/cumm), ESR 67 mm/hr (ref. 0-20 mm/hr), CRP 9.44 mg/dL (ref. 0.00-0.30 mg/dL), and TSH 0.385 MCU (ref. 0.550-4.780 MCU). Notable normal labs were as follows: ANA, rheumatoid factor, anti-CCP, c3, c4, and ACE. Infectious workup for syphilis, TB, Lyme, and HIV were negative. The patient's CT orbit was notable for thickening anterior to the left globe

and thickening of the wall of the left globe suspicious for preseptal cellulitis and scleritis/panophthalmitis (Figure 1). CT orbit also showed serous retinal detachment and edema of the optic disc and nerve. MRI orbit showed abnormal enhancement of the retroorbital fat and extraocular muscles. There was enhancing nodular tissue within the right inferior turbinate. No evidence of post-septal abscess was found. Chest x-ray and CT chest were unremarkable. Bedside nasal endoscopy showed polypoid degeneration; there were no signs of invasive fungal sinusitis, though endonasal mucosal biopsy was not performed.

Clinical Course

Following transfer to our hospital, suspicion for orbital infection remained high and the patient was continued on broad-spectrum systemic antibiotics. When the patient continued to show no improvement and invasive fungal sinusitis was ruled out with nasal endoscopy and MRI, the patient was diagnosed with orbital pseudotumor. Treatment was initiated with 1 mg/kg oral prednisone daily with close monitoring for worsening of orbital findings, which would indicate infectious cause. However, eyelid edema, proptosis, chemosis, and other orbital signs improved significantly over three days, allowing gram-negative and anaerobic systemic antibiotic coverage to be tapered. The patient was continued only on vancomycin for coverage of possible peri-orbital cellulitis.

As the orbital inflammation improved, the patient was found to have multifocal necrotizing scleritis. In addition, she developed rapidly progressive peripheral ulcerative keratitis (PUK) with corneal melt and limbal/scleral thinning, and a hypopyon (Figure 2). Systemic vasculitis with superimposed infection was suspected. Topical therapy was initiated with fortified vancomycin and tobramycin, and oral therapy was initiated with NSAIDs, acyclovir, and doxycycline. Corneal bacterial culture grew *Mannheimia haemolytica*, and corneal fungal culture was negative. Further lab workup at this time revealed urine abnormalities including urine protein/creatinine ratio 583.8 mg/g (ref. 21.0-161.0 mg/g) and 5 /HPF urine red blood cells (ref. 0-3 /HPF). HLA-B27, c-ANCA, and p-ANCA were normal. Despite this lack of c-ANCA, GPA was suspected based on findings of nasal inflammation, urine abnormalities, and worsening of ocular inflammation even while on high-dose steroids. She was started on IV methylprednisolone 1000 mg twice a day and cyclophosphamide 500 mg IV every two weeks. After three days, PUK improved, scleral thinning stabilized, and visual acuity improved from hand motion to 20/225.

Over the next several weeks, prednisone was tapered and six cycles of cyclophosphamide 500 mg IV in total were administered. Azathioprine was used for maintenance. Inflammation was controlled, though areas of avascular sclera remained in areas of previous necrotizing scleritis (Figure 3). After two months, VA improved to 20/50. The patient was then lost to follow up and stopped all systemic immunosuppression. However, she has been doing well and sees an outside ophthalmologist who prescribes her prednisolone acetate 1% once per day in the left eye. She was recently started on rituximab for hidradenitis suppurativa by an outside dermatologist. Fortuitously, rituximab has been shown to be an effective therapy for GPA and may prevent relapse in our patient.^{1,2}

Discussion

GPA is a clinical diagnosis of necrotizing granulomatous vasculitis of the upper and lower respiratory system, systemic vasculitis, and necrotizing glomerulonephritis.³ Inflammatory eye disease is the initial manifestation in 8-16% of patients with ANCA vasculitis.⁴ Eventually 50-60% of patients with ANCA-positive vasculitis develop ocular inflammation, of which most have anterior segment pathology.⁵ A study of 59 patients with ocular inflammation and ANCA-positive vasculitis found 71% of eyes with scleritis, 5.65 % with episcleritis, 11.1% with PUK, and 8.9% with anterior uveitis.⁵

Diagnosis of GPA remains challenging. Diagnostic criteria for GPA require two of the following four signs: abnormal urinary sediment (red cell casts or greater than 5 red blood cells per high power field), abnormal findings on chest radiograph (nodules, cavities, or fixed infiltrates), oral ulcers or nasal discharge, and granulomatous inflammation on biopsy.⁶ If two or more of these signs are present, sensitivity and specificity of the diagnosis are 88.2% and 92.0% respectively. These criteria were developed before ANCA testing was commonly used; the American College of Rheumatology and the European League Against Rheumatism may develop new criteria in coming years.⁷

In our patient, the initial presentation of unilateral proptosis and painful ophthalmoplegia was suggestive of an infectious orbital cellulitis. Since infectious causes can be readily treated and must be ruled out when suspected, she was managed with systemic antimicrobial therapy. However, phenotypic changes in the clinical course, namely the presence of orbital inflammation with multifocal necrotizing scleritis and PUK, raised suspicion of aggressive systemic vasculitis such as GPA. This suspicion increased after infectious causes were ruled out and the patient failed to respond to aggressive systemic antimicrobial treatment. In a study of 500 patients with scleritis, 14 patients with scleritis due to GPA had significantly higher rates of sudden-onset necrotizing scleritis as compared to patients with idiopathic scleritis and scleritis due to other autoimmune diseases (21.4% versus 1.2% and 2.7% respectively).⁸ PUK consists of findings of epithelial defect, inflammatory cells in the stroma, and stromal ulceration in the peripheral cornea, and is often associated with adjacent conjunctival, episcleral, or scleral inflammation.⁹ Presence of scleritis and concurrent PUK, as seen in our patient, is associated with connective tissue and vasculitic disorders such as GPA and rheumatoid arthritis.¹⁰ Lastly, the patient's prior diagnosis of hidradenitis suppurativa, and inflammatory disease, raised suspicion of an autoimmune disorder. Though both hidradenitis suppurativa and GPA are rare, multiple cases of concurrent disease may suggest an association between the two conditions.¹¹

In our patient, diagnosis was obfuscated by the negative c-ANCA result. However, GPA patients have been found to test negatively for c-ANCA in several studies. In one series of 16 patients with PUK and GPA, 12.5% of patients were ANCA negative.¹² In the Wegener's Granulomatosis Etanercept Trial (WGET), 24% of GPA patients were c-ANCA negative and 11% were c-ANCA and p-ANCA negative.^{13,14} In the WGET, this ANCA negative rate occurred when immunofluorescence assay (IFA) is used alone for testing, as was the case with our patient.

When a combination of additional testing modalities including ELISA against mature proteinase-3 and pro-proteinase-3 were used, the rate of GPA patients who were ANCA negative dropped to 8%. These studies suggest that though a great majority of GPA patients are ANCA positive, a minority will be ANCA-negative. The diagnosis of GPA should still be entertained if clinical suspicion remains high. This is even more important given the high rate of mortality seen in GPA—80% in one year if untreated.¹⁵ With aggressive immunomodulatory therapy, prognosis has greatly improved, with five year survival of 75%.¹⁶

Conclusion

In summary, we present a patient who presented with orbital inflammation, necrotizing scleritis and PUK. After infectious causes were ruled out, GPA was suspected despite negative ANCA antibodies. When serum IFA studies are used alone, ANCA testing can be negative in 11% of patients with ANCA vasculitis. As such, it is important to retain clinical suspicion of ANCA vasculitis even when c-ANCA and p-ANCA tests are negative. This patient was successfully treated for GPA with cyclophosphamide induction and azathioprine maintenance therapy with improvement in vision and prevention of serious systemic manifestations.

Figures

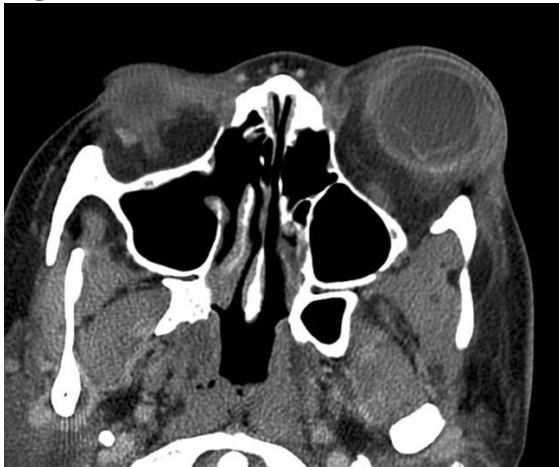

Figure 1. CT orbits upon presentation. CT orbits demonstrated thickening anterior to the left globe, thickening of the wall of the left globe, low density material between the retina and globe wall, and thickening of the optic nerve which were concerning for preseptal cellulitis, scleritis, panophthalmitis, serous retinal detachment, and optic nerve edema. No postseptal abscess was present.

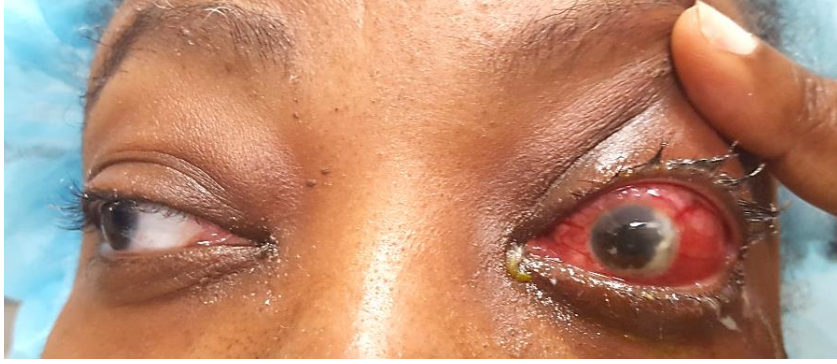

Figure 2. Peripheral ulcerative keratitis and multifocal necrotizing scleritis. Though ptosis and proptosis improved on oral steroid treatment, the patient was found to have multifocal necrotizing scleritis and developed rapidly progressive PUK and hypopyon. These did not respond to topical and systemic antimicrobials.

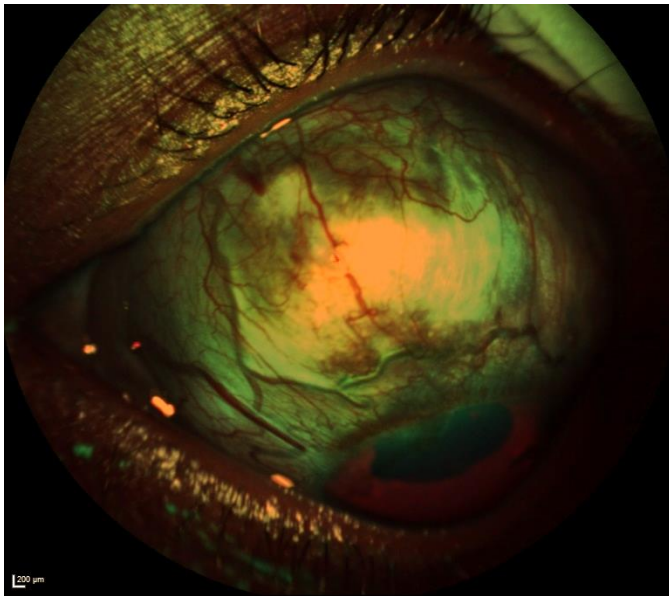


Figure 3. External photos one month after presentation. After inflammation was controlled, avascular patches of sclera could be observed in areas previously afflicted with necrotizing scleritis.

References

1. You C, Ma L, Lasave AF, Foster CS. Rituximab Induction and Maintenance Treatment in Patients with Scleritis and Granulomatosis with Polyangiitis (Wegener's). *Ocular immunology and inflammation*. 2018;26(8):1166-1173.
2. Ahmed A, Foster CS. Cyclophosphamide or Rituximab Treatment of Scleritis and Uveitis for Patients with Granulomatosis with Polyangiitis. *Ophthalmic research*. 2019;61(1):44-50.
3. Fahey JL, Leonard E, Churg J, Godman G. Wegener's granulomatosis. *The American journal of medicine*. 1954;17(2):168-179.
4. Pakrou N, Selva D, Leibovitch I. Wegener's granulomatosis: ophthalmic manifestations and management. *Seminars in arthritis and rheumatism*. 2006;35(5):284-292.

5. Watkins AS, Kempen JH, Choi D, et al. Ocular disease in patients with ANCA-positive vasculitis. *Journal of ocular biology, diseases, and informatics*. 2009;3(1):12-19.
6. Leavitt RY, Fauci AS, Bloch DA, et al. The American College of Rheumatology 1990 criteria for the classification of Wegener's granulomatosis. *Arthritis and rheumatism*. 1990;33(8):1101-1107.
7. Yoo J, Kim HJ, Ahn SS, et al. The utility of the ACR/EULAR 2017 provisional classification criteria for granulomatosis with polyangiitis in Korean patients with antineutrophil cytoplasmic antibody-associated vasculitis. *Clinical and experimental rheumatology*. 2018;36 Suppl 111(2):85-87.
8. Cocho L, Gonzalez-Gonzalez LA, Molina-Prat N, Doctor P, Sainz-de-la-Maza M, Foster CS. Scleritis in patients with granulomatosis with polyangiitis (Wegener). *The British journal of ophthalmology*. 2016;100(8):1062-1065.
9. Yagci A. Update on peripheral ulcerative keratitis. *Clinical ophthalmology (Auckland, NZ)*. 2012;6:747-754.
10. Sainz de la Maza M, Foster CS, Jabbur NS, Baltatzis S. Ocular characteristics and disease associations in scleritis-associated peripheral keratopathy. *Archives of ophthalmology (Chicago, Ill : 1960)*. 2002;120(1):15-19.
11. Alavi A, Shavit E, Archer J, Pagnoux C. Hidradenitis suppurativa and vasculitis: A case series and literature review of a rare association. *SAGE open medical case reports*. 2019;7:2050313x19882852.
12. Ebrahimiadib N, Modjtahedi BS, Roohipoor R, Anesi SD, Foster CS. Successful Treatment Strategies in Granulomatosis With Polyangiitis-Associated Peripheral Ulcerative Keratitis. *Cornea*. 2016;35(11):1459-1465.
13. Stone JH. Limited versus severe Wegener's granulomatosis: baseline data on patients in the Wegener's granulomatosis etanercept trial. *Arthritis and rheumatism*. 2003;48(8):2299-2309.
14. Finkielman JD, Lee AS, Hummel AM, et al. ANCA are detectable in nearly all patients with active severe Wegener's granulomatosis. *The American journal of medicine*. 2007;120(7):643.e649-614.
15. Walton EW. Giant-cell granuloma of the respiratory tract (Wegener's granulomatosis). *British medical journal*. 1958;2(5091):265-270.
16. Phillip R, Luqmani R. Mortality in systemic vasculitis: a systematic review. *Clinical and experimental rheumatology*. 2008;26(5 Suppl 51):S94-104.