

# Red Eyes and Red Herrings: An Atypical Case of Atypical Mycobacterium

Hasenin Al-khersan, MD<sup>1</sup>

Guillermo Amescua, MD<sup>1</sup>

Janet L. Davis, MD<sup>1</sup>

<sup>1</sup>Bascom Palmer Eye Institute, Miami, FL

## Abstract

*Purpose:* To present a case of atypical *Mycobacterium* scleritis in a patient without reported risk factors.

*Case Presentation:* A 50-year-old female presented with left eye redness for two months. On examination, the left eye demonstrated conjunctival injection and two temporal scleral nodules. Laboratory work-up revealed elevated rheumatoid factor and CRP. The patient was started on oral prednisone for a suspicion of rheumatoid arthritis with initial improvement. Subconjunctival triamcinolone acetonide was then administered to the left eye. Subsequently, the patient developed scleral thinning at the site of injection. She was taken to the operating room for scleral debridement during which the nodules were lanced producing copious pus. Intraoperative cultures grew *Mycobacterium abscessus*. Topical and subconjunctival amikacin were administered along with oral clarithromycin. The infection resolved, and the scleral thinning halted.

*Conclusion:* Infectious scleritis can present a diagnostic challenge. In cases of idiopathic scleritis that do not improve with treatment, the diagnosis should be reconsidered. Biopsy can be a useful diagnostic adjunct. Treatment with local steroid injections should be administered cautiously in cases when infection is a possibility.

## History

A 50-year-old female presented with left eye redness and headaches starting two months prior. She reported that a recent head CT performed by her primary care doctor was unremarkable. She denied ocular disease, trauma, or surgery. There was no known family history of autoimmune disease.

## Examination

At presentation, best-corrected visual acuity (BCVA) was 20/20 OD and 20/25 OS. Intraocular pressure, extraocular motility, and pupillary exam were normal. Examination of the right eye was unremarkable. The left eye demonstrated two temporal scleral nodules with surrounding injection. Posterior examination was unremarkable. Ultrasound demonstrated anterior staphyloma in the left eye without posterior findings.

Laboratory testing was performed. Quantiferon, RPR, FTA, ANCA, and ACE were unremarkable. The rheumatoid factor (RF) and CRP were mildly elevated. Additionally, Lyme IgG and IgM and reflex Western blot assays were positive. The patient denied travel to Lyme endemic regions, tick bites, and rashes.

The patient was started on oral prednisone for possible rheumatoid arthritis (RA)-associated nodular scleritis and doxycycline for the positive Lyme studies. She was referred to rheumatology for further RA evaluation. Two weeks after presentation, the patient noted improvement in pain, but the scleral nodules and injection persisted. Therefore, subconjunctival triamcinolone acetonide (0.5mL of 40mg/mL) was then administered to the left eye. Further confirmatory RA workup by rheumatology was negative. Subsequently, the patient's exam showed new scleral thinning of the left eye with persistence of the temporal scleral nodules (Figure 1).

### Discussion and Diagnosis

Anterior scleritis, the most common form of scleritis, presents with eye redness, significant pain, and globe tenderness.<sup>1</sup> Many systemic diseases are associated with scleritis, and diagnosis of underlying systemic conditions is important in the management of ocular disease. Etiologies include autoimmune, infectious, and traumatic causes. Of autoimmune etiologies, RA is most common.<sup>2</sup>

In this case, the patient's initial work up demonstrated two possible causes of scleritis: Lyme disease and RA. Lyme disease was thought to be an unlikely etiology for several reasons. First, there was no history of travel to endemic areas, rash or tick bites, or improvement with doxycycline. Lastly, Lyme disease can present with ocular inflammation, including episcleritis and scleritis, but not usually with rapid scleral thinning or suppuration.<sup>3,4</sup>

Instead, nodular scleritis, in the setting of RA, was initially the leading diagnosis. Importantly, however, although the scleritis initially improved symptomatically with oral prednisone, it worsened with new necrosis after subconjunctival triamcinolone injection, raising concern for a non-spirochetal infection. Furthermore, though she had a mildly elevated RF, further testing by a rheumatologist did not support a diagnosis of RA-associated scleritis.

At this juncture, the diagnosis was reconsidered given the patient's worsening condition after local steroid therapy and the low likelihood based on rheumatology consultation of RA as the etiology. Thus, scleral biopsy and culture was judged to be the most direct way to evaluate the patient and to stabilize the globe.

Scleral biopsy was performed in the operating room under local anesthesia. Dissection of the scleral nodules released purulent material, which was cultured, revealing the lesions were abscesses rather than inflammatory nodules. Necrotic sclera was debrided. An amniotic membrane was sutured over the scleral thinning. Cultures taken during surgery grew *Mycobacterium abscessus* one week later. The patient then started amikacin (8mg/mL) topical

drops every hour, clarithromycin 500mg twice daily, and 1mL subconjunctival amikacin(40mg/mL) injection.

Over five weeks of treatment, our patient reported resolution of pain. The hyperemia improved, and the scleral thinning stabilized (Figure 2). Her BCVA was 20/25+2 in the affected eye three months after surgery.

### Conclusion

Infection causes between 5-10% of scleritis cases.<sup>5</sup> Bacteria are the most common organisms.<sup>6</sup> Ocular surgery or trauma are predisposing factors especially in rare, nontuberculous mycobacterial infections, which overwhelmingly occur after prior surgery or trauma.<sup>7</sup> Obtaining a good clinical history is therefore essential. Our patient had no prior ocular trauma or surgery, however. An atypical infectious etiology was suspected subsequent to local injection of depot corticosteroids after which worsening of her condition was noted, prompting biopsy.

Paradoxical worsening or failure of scleritis to improve with corticosteroids should suggest the possibility of infection. Debridement at the time of biopsy was an important adjunct to medical treatment. Salvage of this eye was possible because biopsy was elected early, facilitating control of the infection with topical, injectable, and oral antibiotics.

Local triamcinolone injection can be a useful adjunctive therapy in non-necrotizing anterior scleritis but should be avoided in cases with necrosis due to risk of scleral melt and perforation.<sup>8</sup> In scleritis of unknown etiology without initial necrosis as this one, local corticosteroid injection should be cautiously administered with close follow up and escalation to biopsy if indicated.

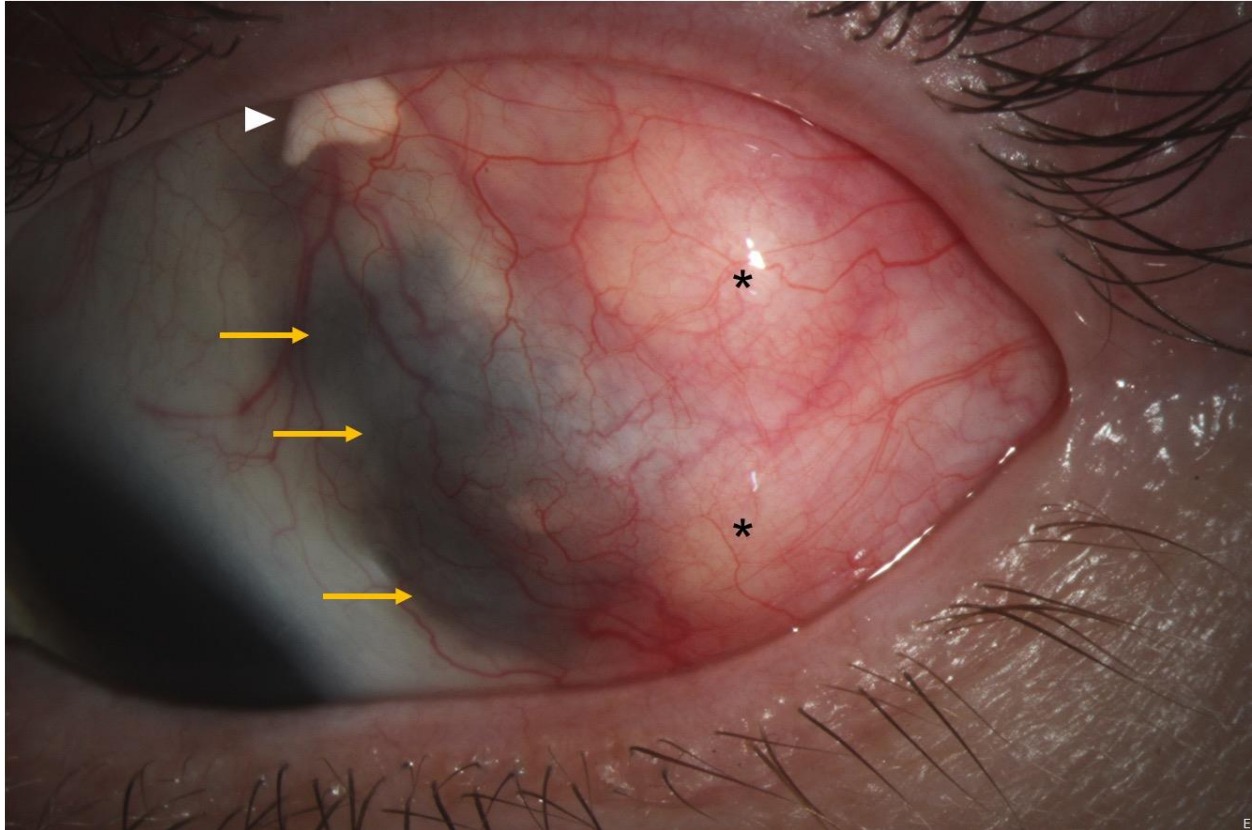


Figure 1: Slit lamp photography of the left eye after subconjunctival triamcinolone acetonide injection demonstrates two temporal nodules (asterisks), conjunctival hyperemia, and surrounding scleral thinning (yellow arrows). Superiorly, remnant subconjunctival triamcinolone acetonide can be seen (white arrowhead).

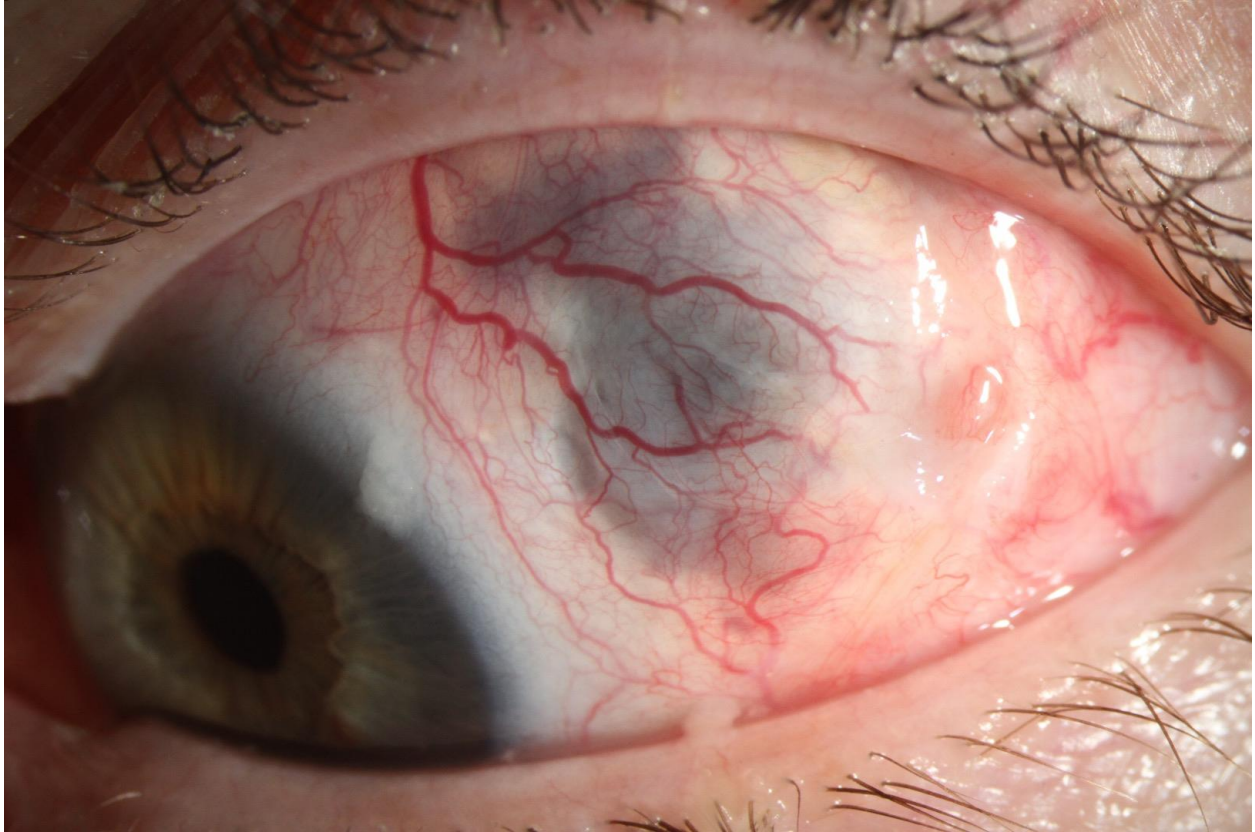

Figure 2: Slit lamp photography of the left eye after treatment for mycobacterium scleritis demonstrates resolution of the temporal scleral nodules with improvement in the conjunctival hyperemia and stable scleral thinning.

## References

1. Okhravi N, Odufuwa B, McCluskey P, Lightman S. Scleritis. *Survey of Ophthalmology*. 2005;50(4):351-363.
2. Akpek EK, Thorne JE, Qazi FA, Do DV, Jabs DA. Evaluation of patients with scleritis for systemic disease. *Ophthalmology*. 2004;111(3):501-506.
3. Mikkilä HO, Seppälä IJT, Viljanen MK, Peltomaa MP, Karma A. The expanding clinical spectrum of ocular lyme borreliosis. *Ophthalmology*. 2000;107(3):581-587.
4. Flach AJ, Lavoie PE. Episcleritis, Conjunctivitis, and Keratitis as Ocular Manifestations of Lyme Disease. *Ophthalmology*. 1990;97(8):973-975.
5. Ramenaden ER, Raiji VR. Clinical characteristics and visual outcomes in infectious scleritis: a review. *Clinical ophthalmology (Auckland, NZ)*. 2013;7:2113-2122.
6. Hodson KL, Galor A, Karp CL, et al. Epidemiology and Visual Outcomes in Patients With Infectious Scleritis. 2013;32(4):466-472.
7. Kheir WJ, Sheheitli H, Abdul Fattah M, Hamam RN. Nontuberculous Mycobacterial Ocular Infections: A Systematic Review of the Literature. *Biomed Res Int*. 2015;2015:164989-164989.
8. Albin TA, Zamir E, Read RW, Smith RE, See RF, Rao NA. Evaluation of subconjunctival triamcinolone for nonnecrotizing anterior scleritis. *Ophthalmology*. 2005;112(10):1814-1820.